

KLİMİK 2024

Ensefalitler

**Radyoloji Tanıda Ne Kadar
Yardımcı?
Tedaviyi Yönlendirir mi?**

Prof. Dr. Kamil Karaali
Akdeniz Üniversitesi
Radyoloji

Santral Sinir Sistemi Enfeksiyonları

Menenjit

Serebrit

Apse

Ensefalit

Granülom

Ventrikülit

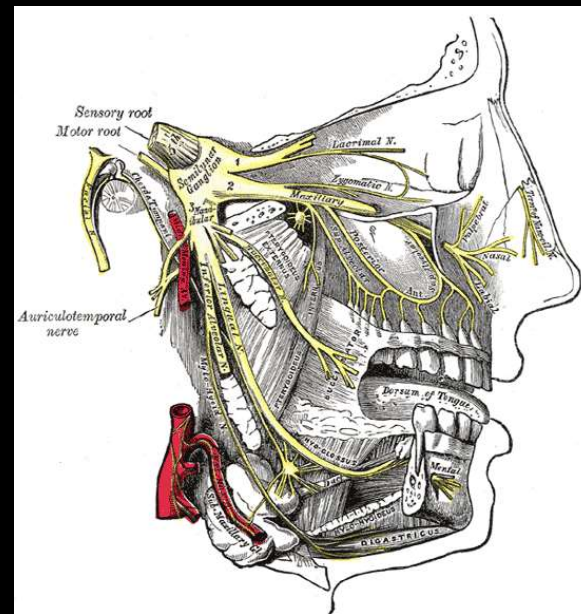
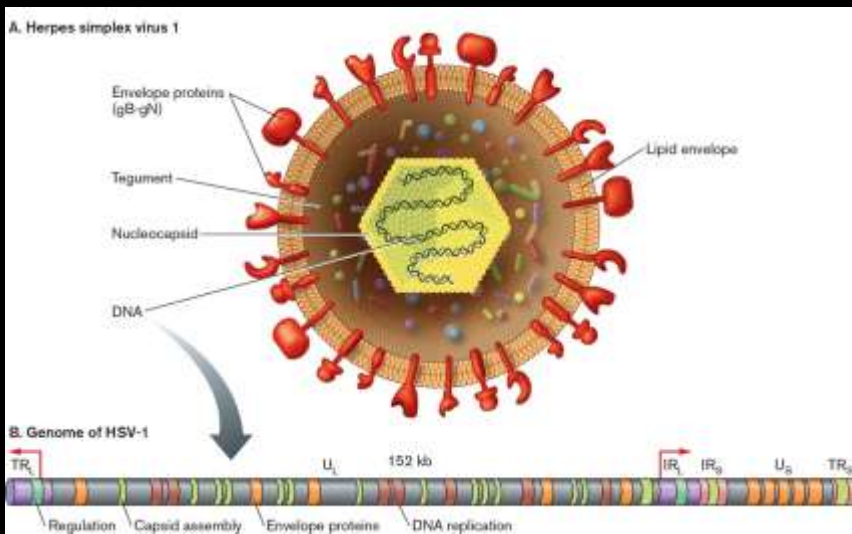
Ampiyem

Ensefalitler

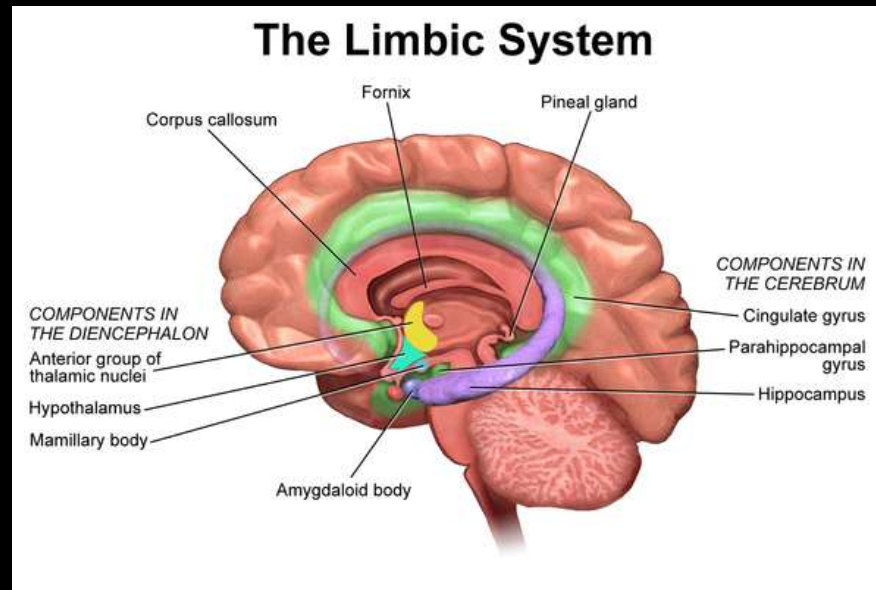
- Serebral parankimde enfeksiyöz süreç
- En sık viral etkenler (başta HSV tip 1 ve 2 olmak üzere)
- Postenfeksiyöz (ADEM)
- Subakut ensefalitler/yavaş virüs enfeksiyonları (CJD, prion ...)

Ensefalitler

- En sık viral neden HSV
 - HSV tip 1: 90 %
 - HSV tip 2: 10 %
 - HHV 6, HHV 7
- VZV, EBV, CMV



<https://microbenotes.com/herpes-simplex-virus-1-hsv-1/>



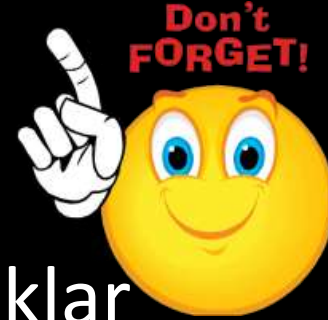https://www.physio-pedia.com/Limbic_System

Herpes ensefaliti

- Temporal lob / hipokampal bölge
 - Asimetrik tutulum / **Bilateral asimetrik**
- Inferior frontal (orbital giruslar, girus rektus)
- insula
- **Singulat girus**

Herpes ensefaliti

- Bazal ganglia tutulumu **yoktur**
- Takipte peteşial hemorajik odaklar
- Beyin sapı tutulumu immünitesi baskılanmış olgularda
- Difüzyon !!
 - Sitotoksik (ADC düşük) kötü prognoz?
 - Vazojenik (ADC yüksek) iyi prognoz?

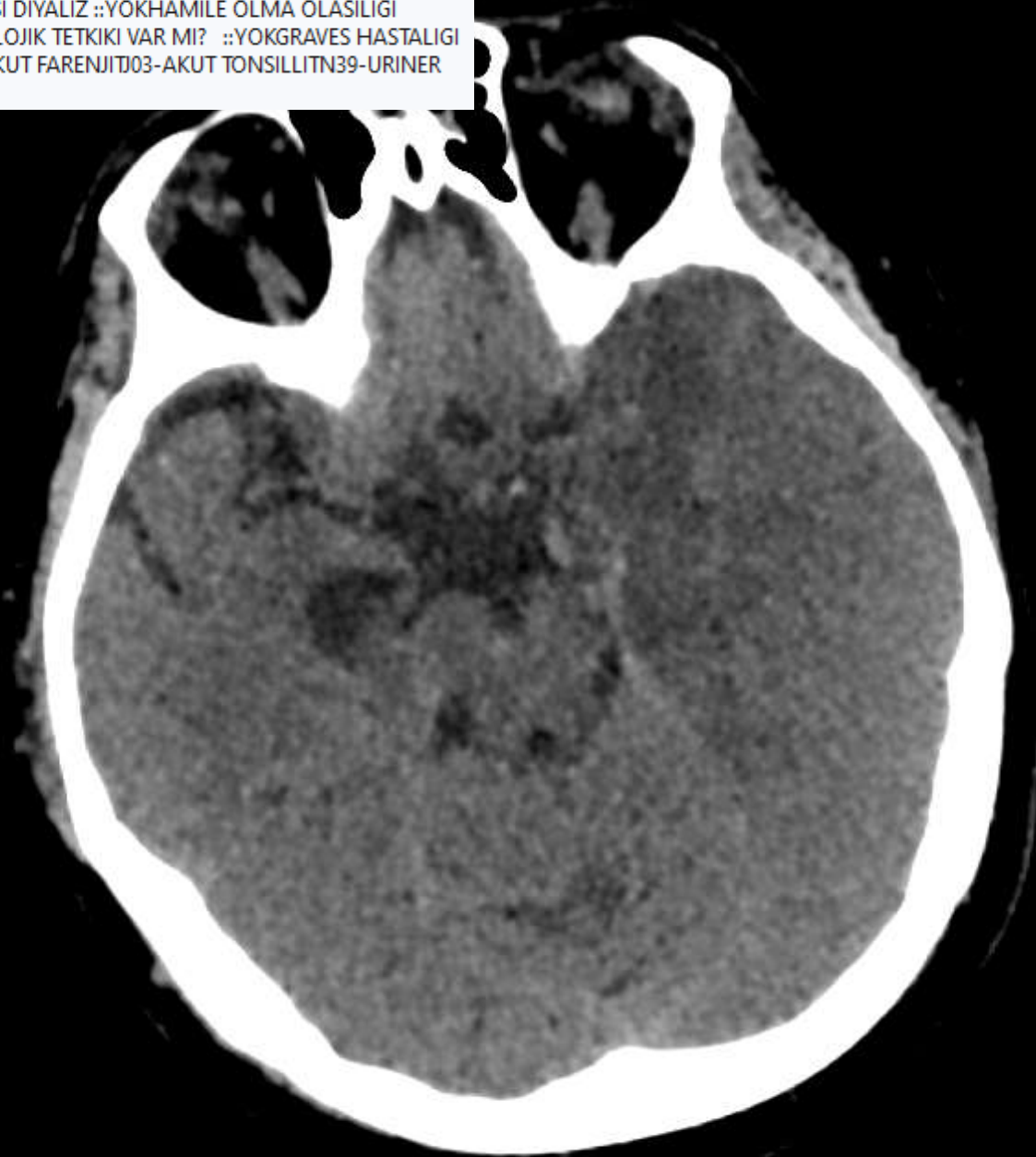

Herpes ensefaliti

- BT' nin pozitif olması ikinci haftayı bulabilir
- MRG genelde 48 saat içinde pozitif (T2 ve FLAIR)

Olgu geçmişi

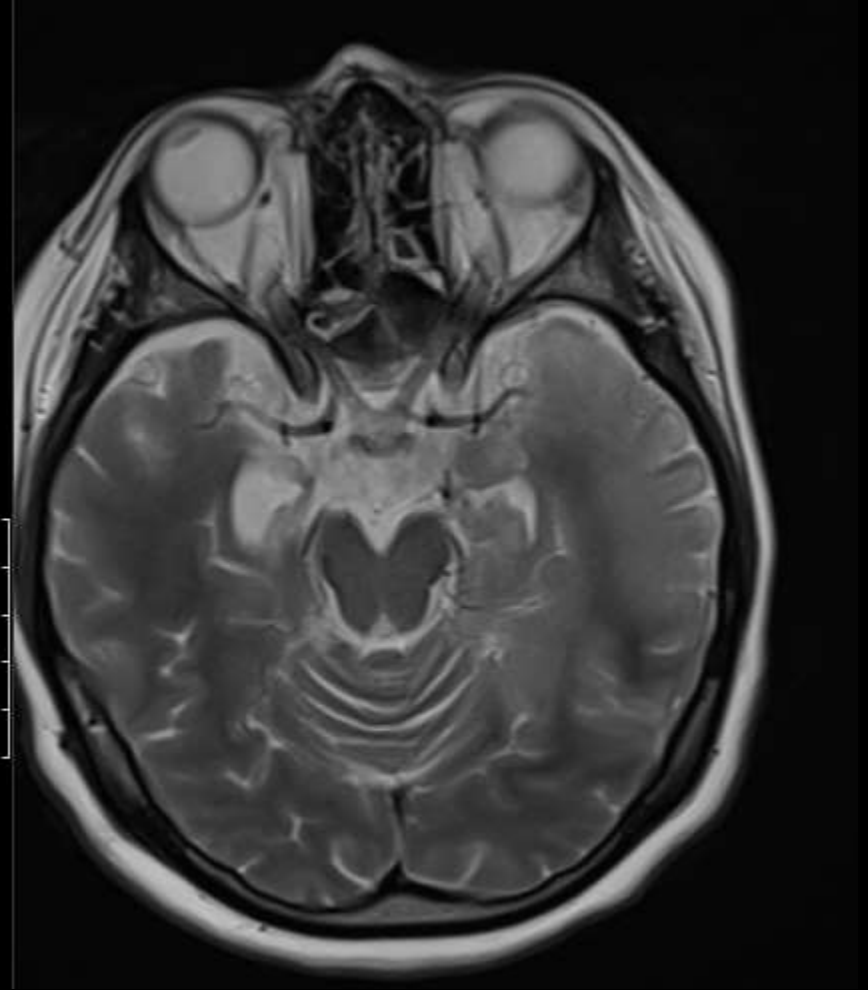
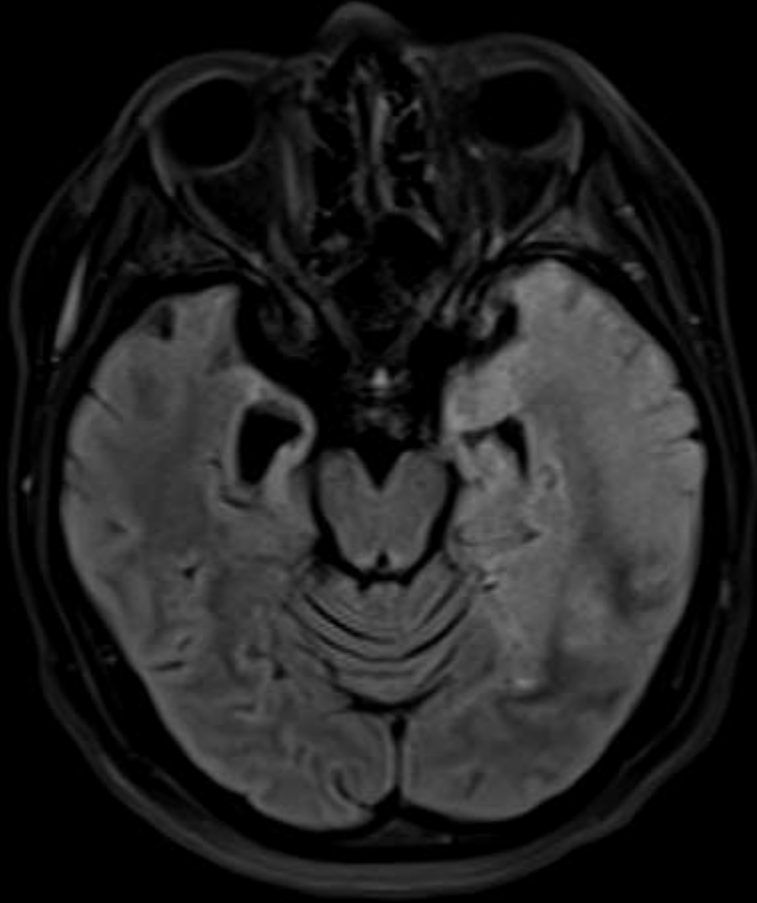
KLINIK BILGI ::26 YAS KADIN HASTA BILINEN JME TARZIINDA EPILEPSI TANILI HASTA 3 GUNDUR UYKUYA MEGIL ++ IKK? SVO? TDRO DR ONURILAC KULLANIM OYKUSU ::YOKALERJI OYKUSU VAR MI ::YOKBOBREK YETMEZLIGI ::YOKTETKIK SONRASI DIYALIZ ::YOKHAMILE OLMA OLASILIGI ::YOKSON 48 SAAT ICERISINDE KONTRASTLI RADYOLOJIK TETKIKI VAR MI? ::YOKGRAVES HASTALIGI ::YOKMULTIPLE MYLELOMA ::YOKGUT :YOK J02-AKUT FARENJITJ03-AKUT TONSILLITN39-URINER SISTEMIN DIGER BOZUKLUKLARI



Olgu geçmişi

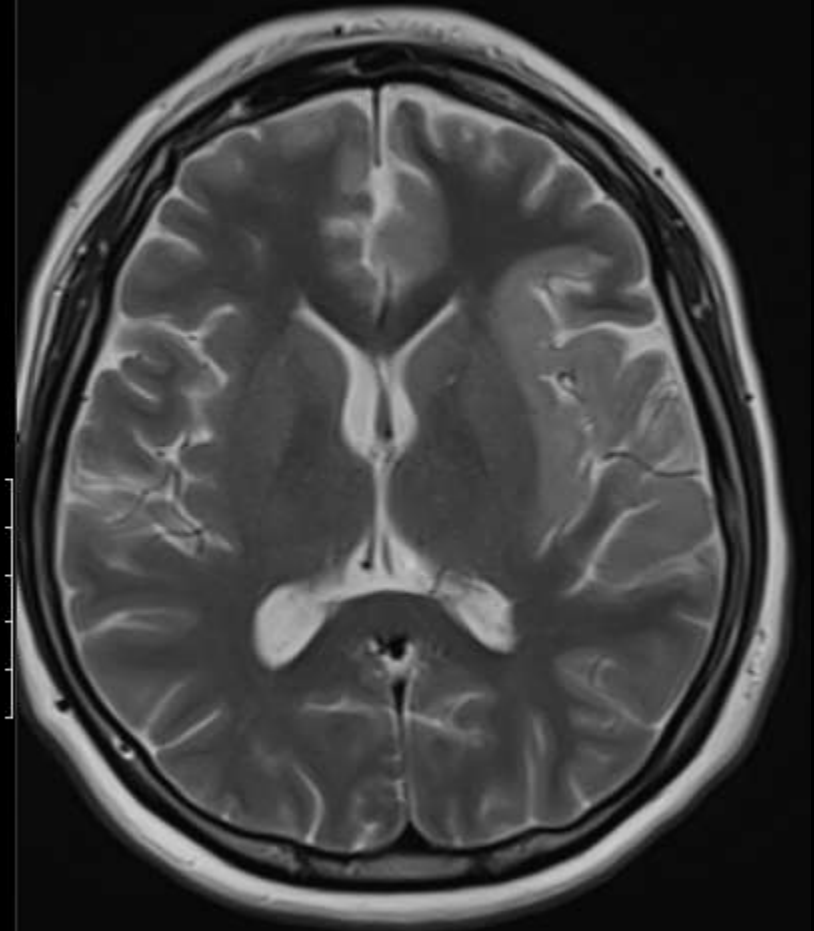
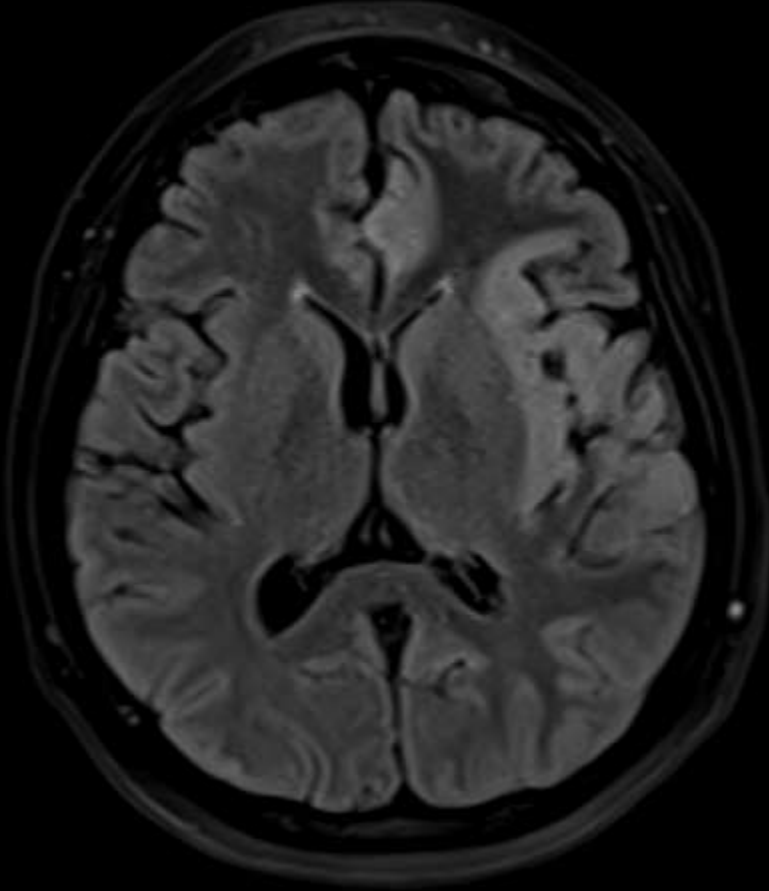
KLINIK BILGI ::26 YAS KADIN HASTA BILINEN JME TARZIINDA EPILEPSI TANILI HASTA 3 GUNDUR UYKUYA MEGIL ++ IKK? SVO? TDRO DR ONURILAC KULLANIM OYKUSU ::YOKALERJI OYKUSU VAR MI ::YOKBOBREK YETMEZLIGI ::YOKTETKIK SONRASI DIYALIZ ::YOKHAMILE OLMA OLASILIGI ::YOKSON 48 SAAT ICERISINDE KONTRASTLI RADYOLOJIK TETKIKI VAR MI? ::YOKGRAVES HASTALIGI ::YOKMULTIPLE MYLELOMA ::YOKGUT :YOK J02-AKUT FARENJITJ03-AKUT TONSILLITN39-URINER SISTEMIN DIGER BOZUKLUKLARI

10 gün
sonra



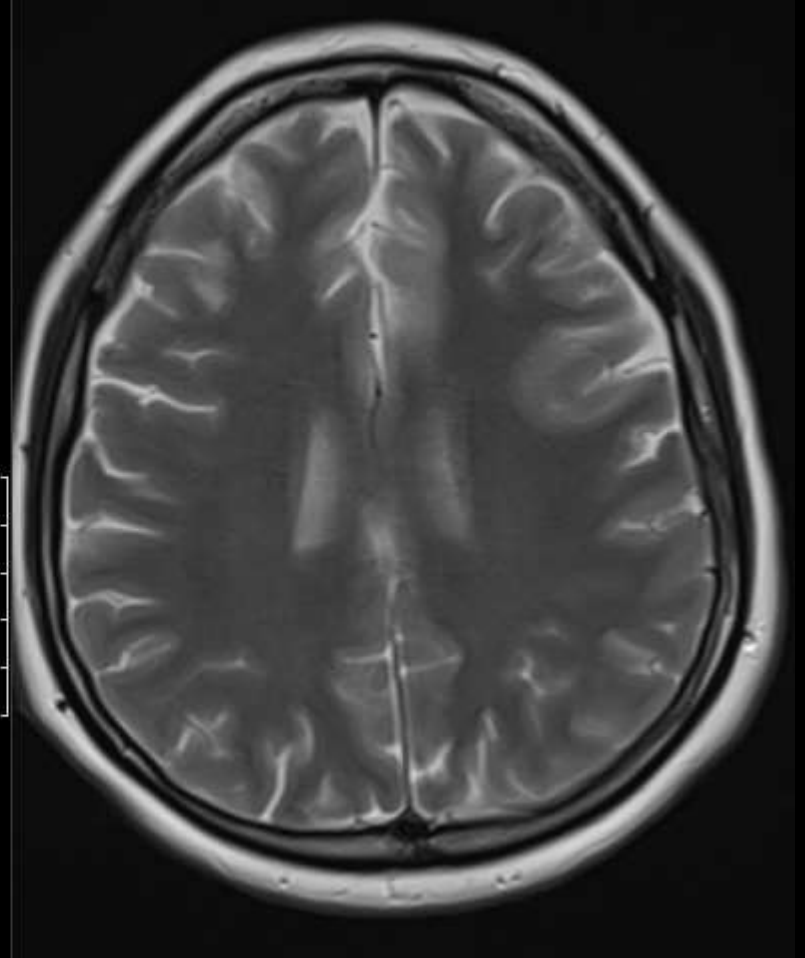
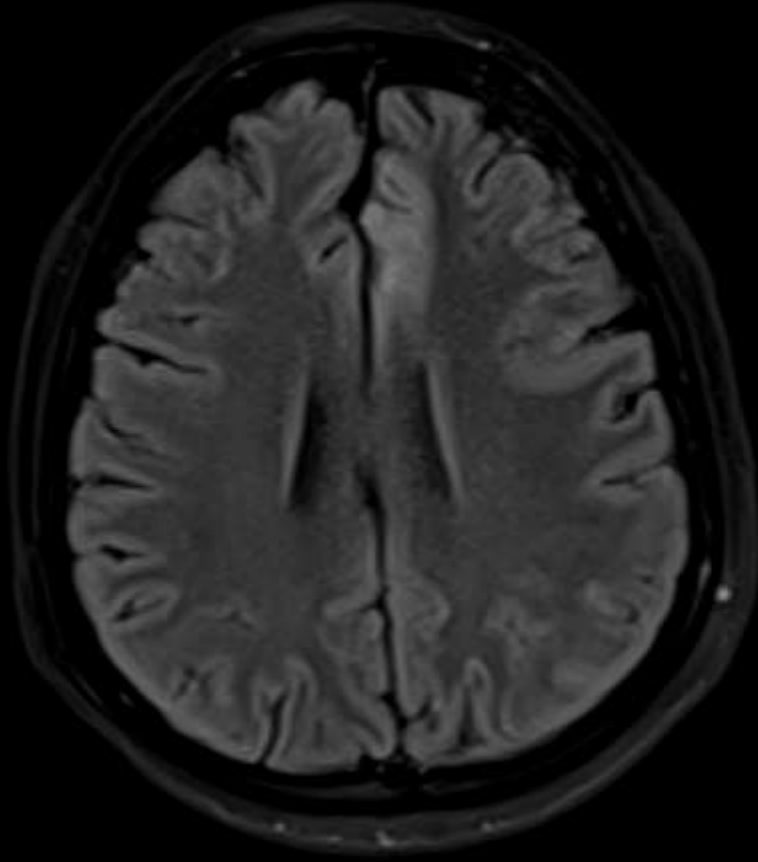
Olgu geçmişi

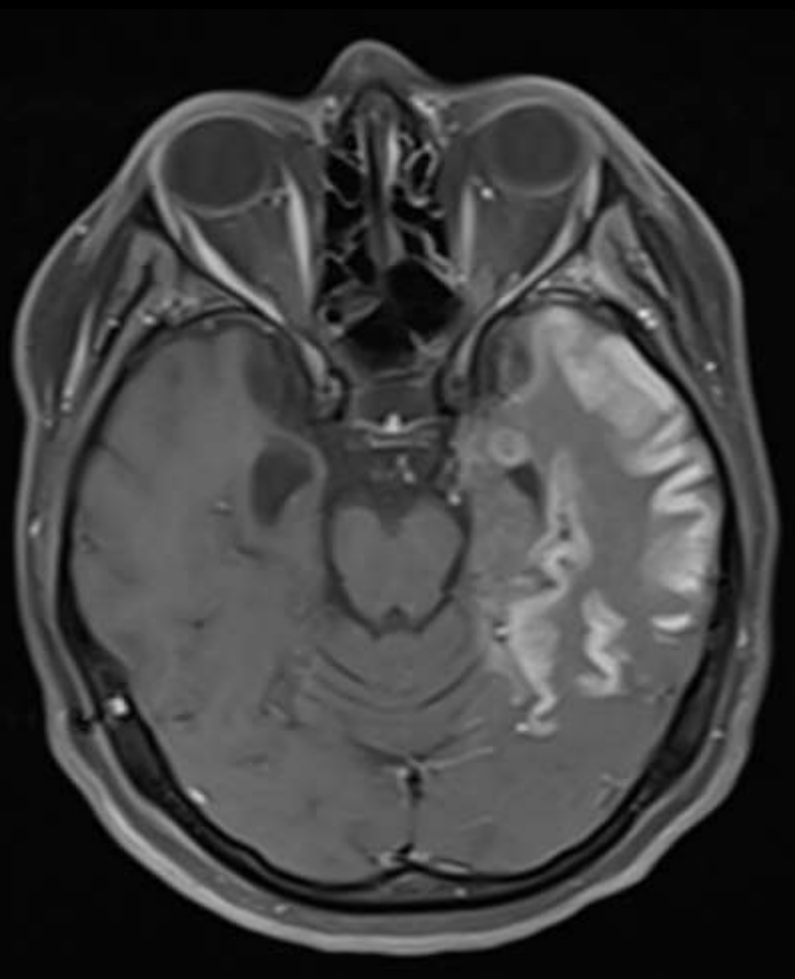
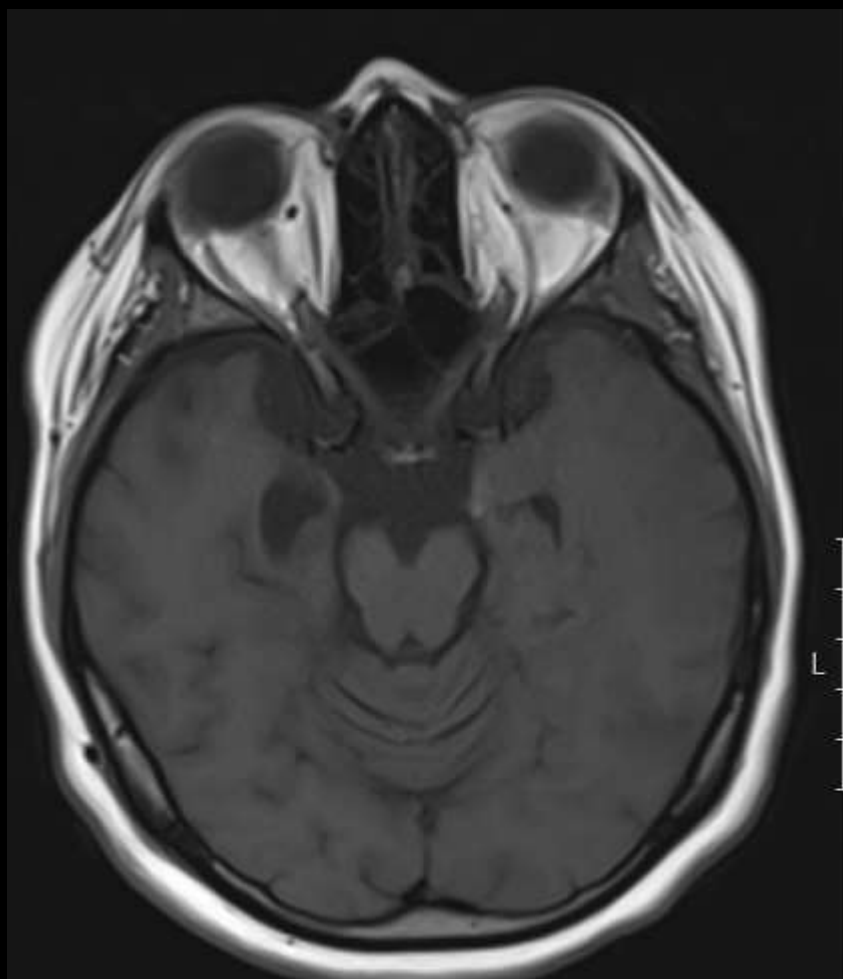
KLINIK BILGI ::26 YAS KADIN HASTA BILINEN JME TARZIINDA EPILEPSI TANILI HASTA 3 GUNDUR UYKUYA MEGIL ++ IKK? SVO? TDRO DR ONURILAC KULLANIM OYKUSU ::YOKALERJI OYKUSU VAR MI ::YOKBOBREK YETMEZLIGI ::YOKTETKIK SONRASI DIYALIZ ::YOKHAMILE OLMA OLASILIGI ::YOKSON 48 SAAT ICERISINDE KONTRASTLI RADYOLOJIK TETKIKI VAR MI? ::YOKGRAVES HASTALIGI ::YOKMULTIPLE MYLELOMA ::YOKGUT :YOK J02-AKUT FARENJITJ03-AKUT TONSILLITN39-URINER SISTEMIN DIGER BOZUKLUKLARI

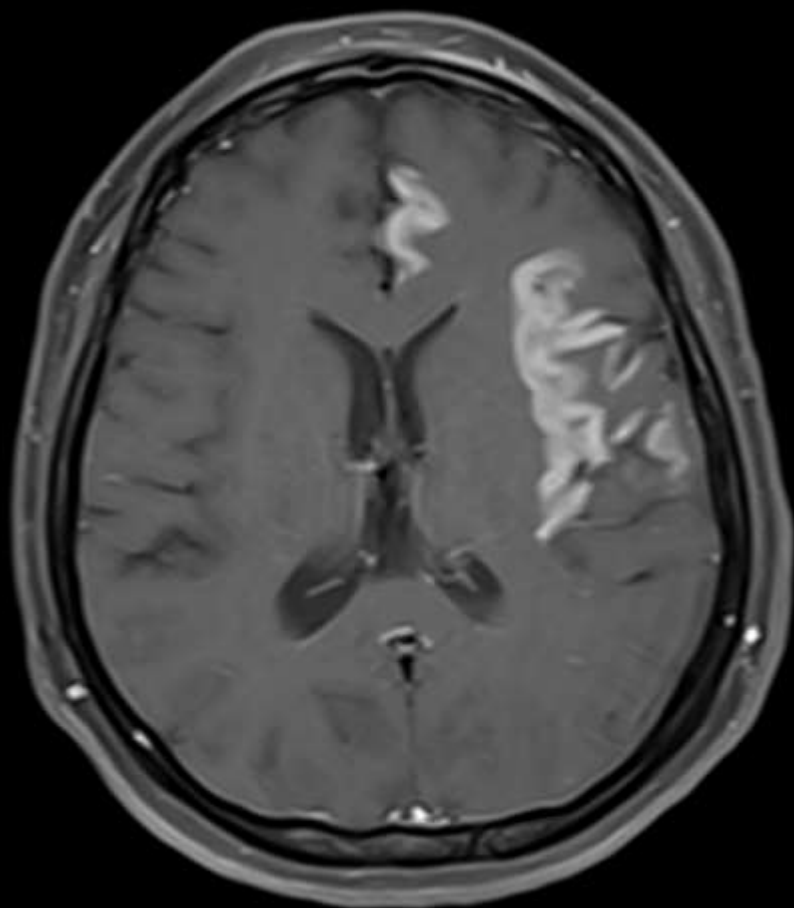
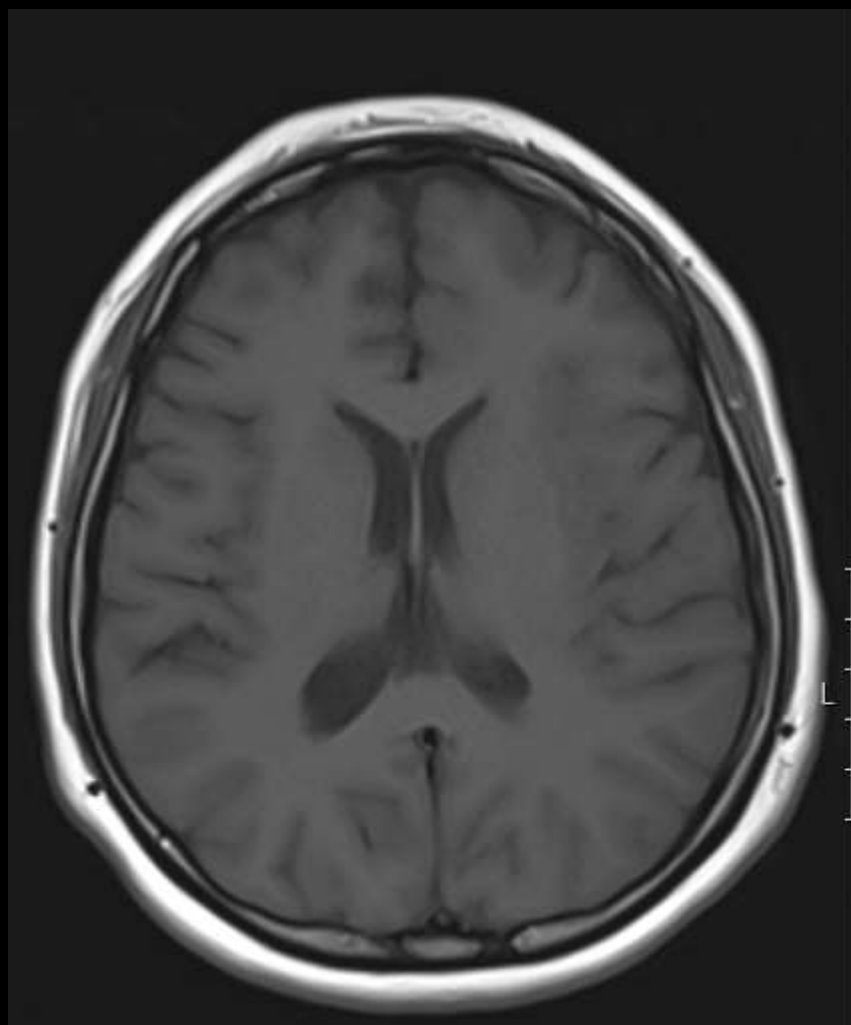


Olgu geçmişi

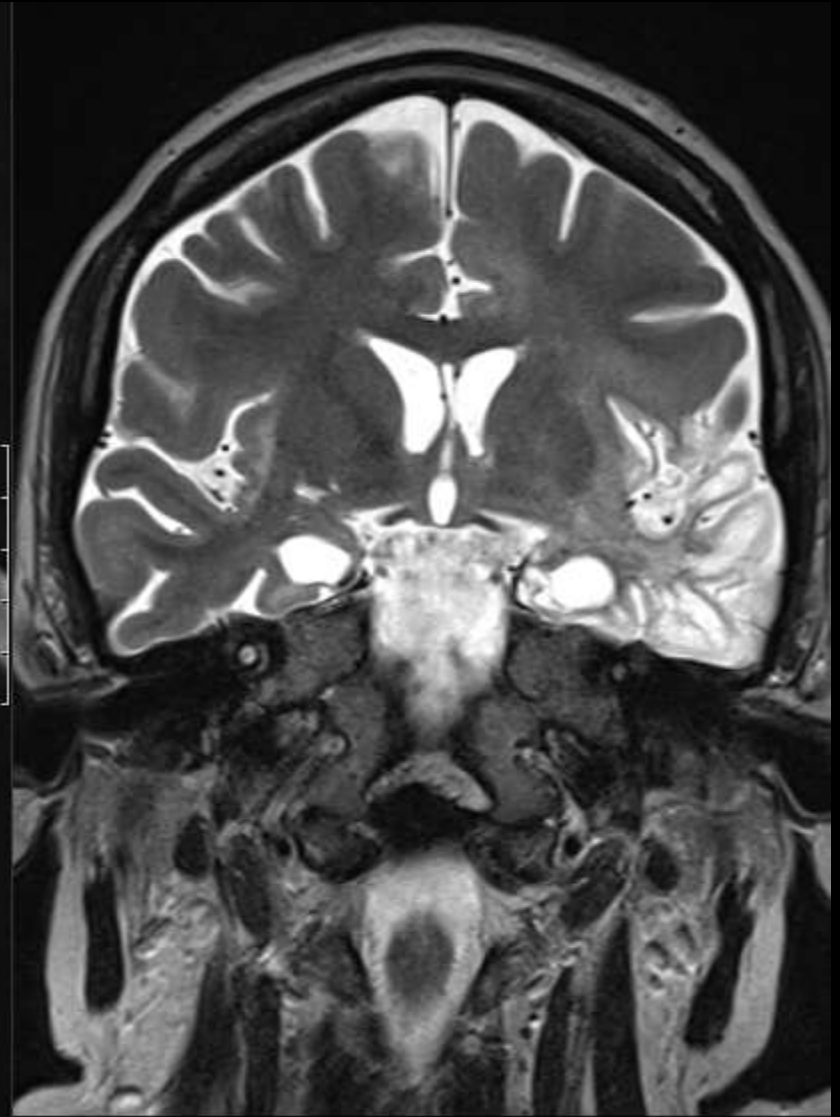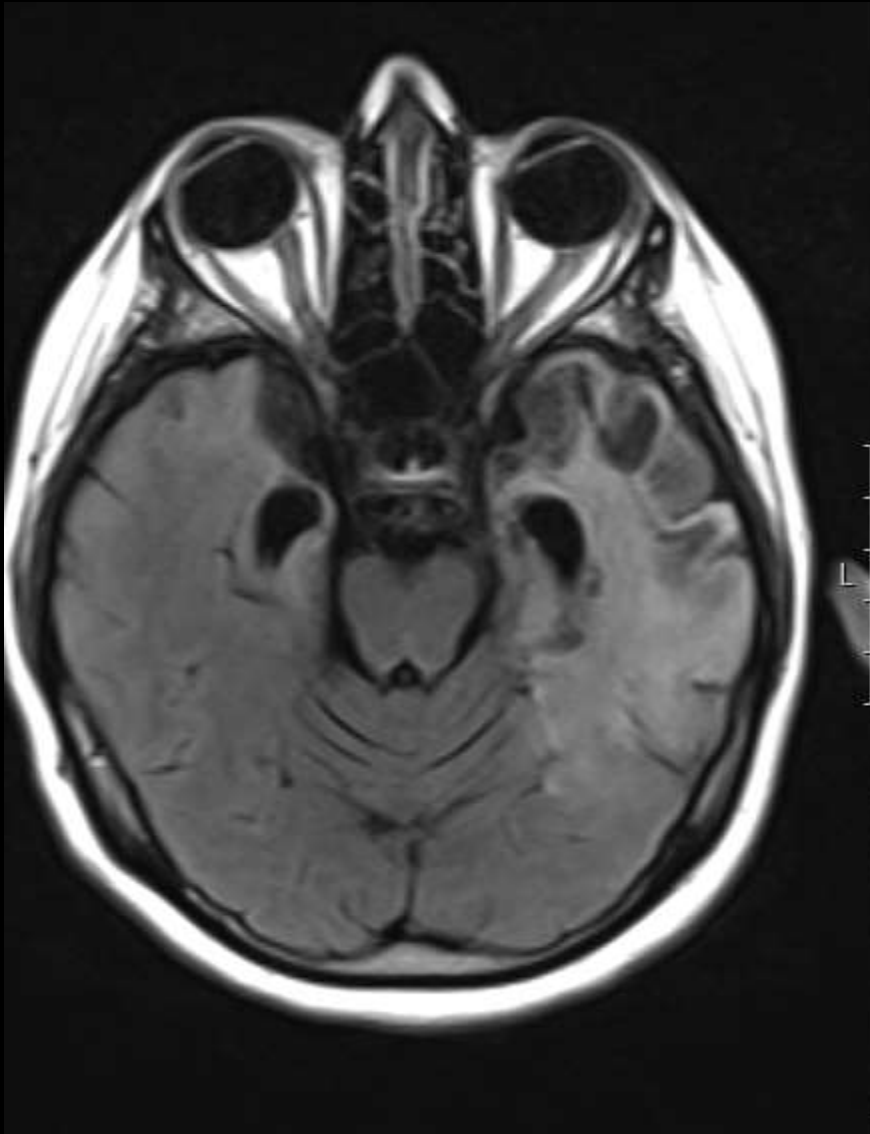
KLINIK BILGI ::26 YAS KADIN HASTA BILINEN JME TARZIINDA EPILEPSI TANILI HASTA 3 GUNDUR UYKUYA MEGIL ++ IKK? SVO? TDRO DR ONURILAC KULLANIM OYKUSU ::YOKALERJI OYKUSU VAR MI ::YOKBOBREK YETMEZLIGI ::YOKTETKIK SONRASI DIYALIZ ::YOKHAMILE OLMA OLASILIGI ::YOKSON 48 SAAT ICERISINDE KONTRASTLI RADYOLOJIK TETKIKI VAR MI? ::YOKGRAVES HASTALIGI ::YOKMULTIPLE MYLELOMA ::YOKGUT :YOK J02-AKUT FARENJITJ03-AKUT TONSILLITN39-URINER SISTEMIN DIGER BOZUKLUKLARI







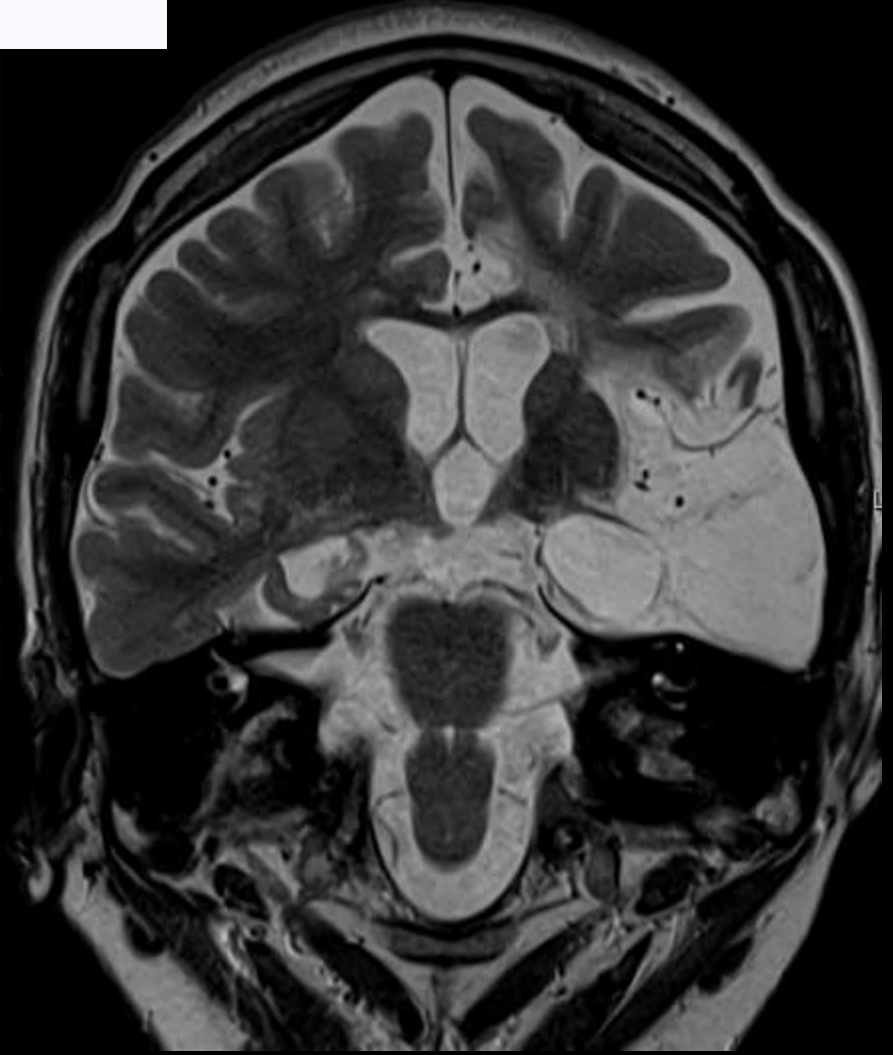
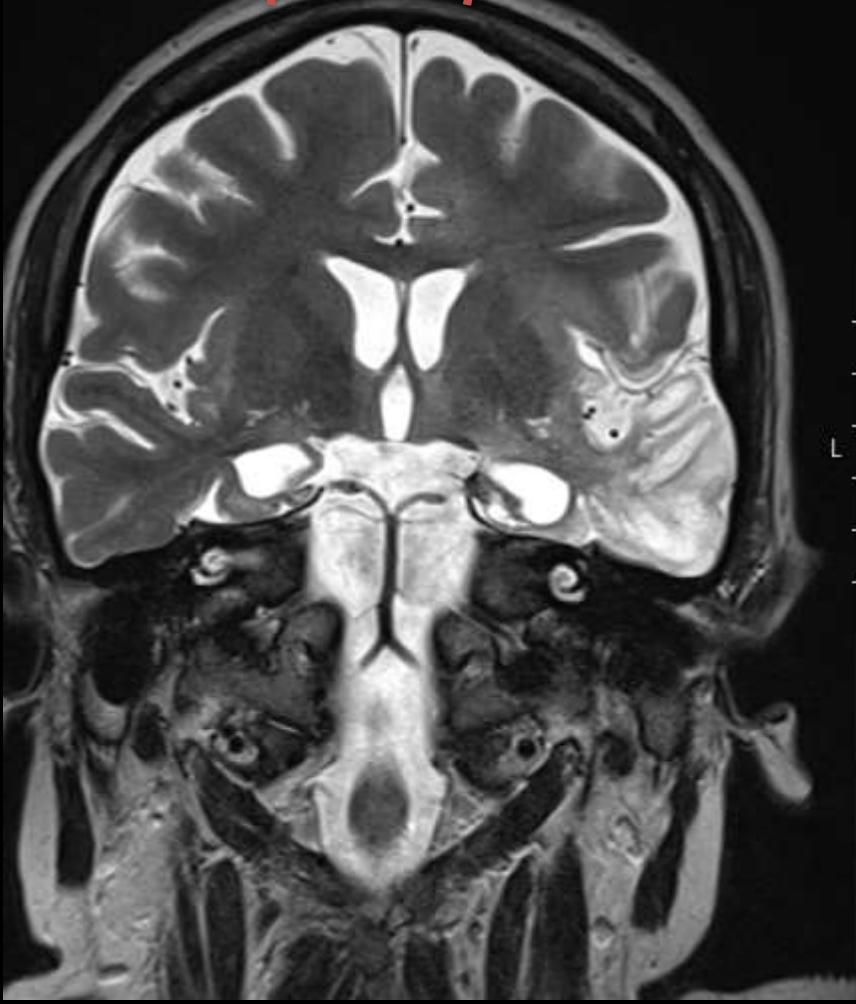
1 ay sonra



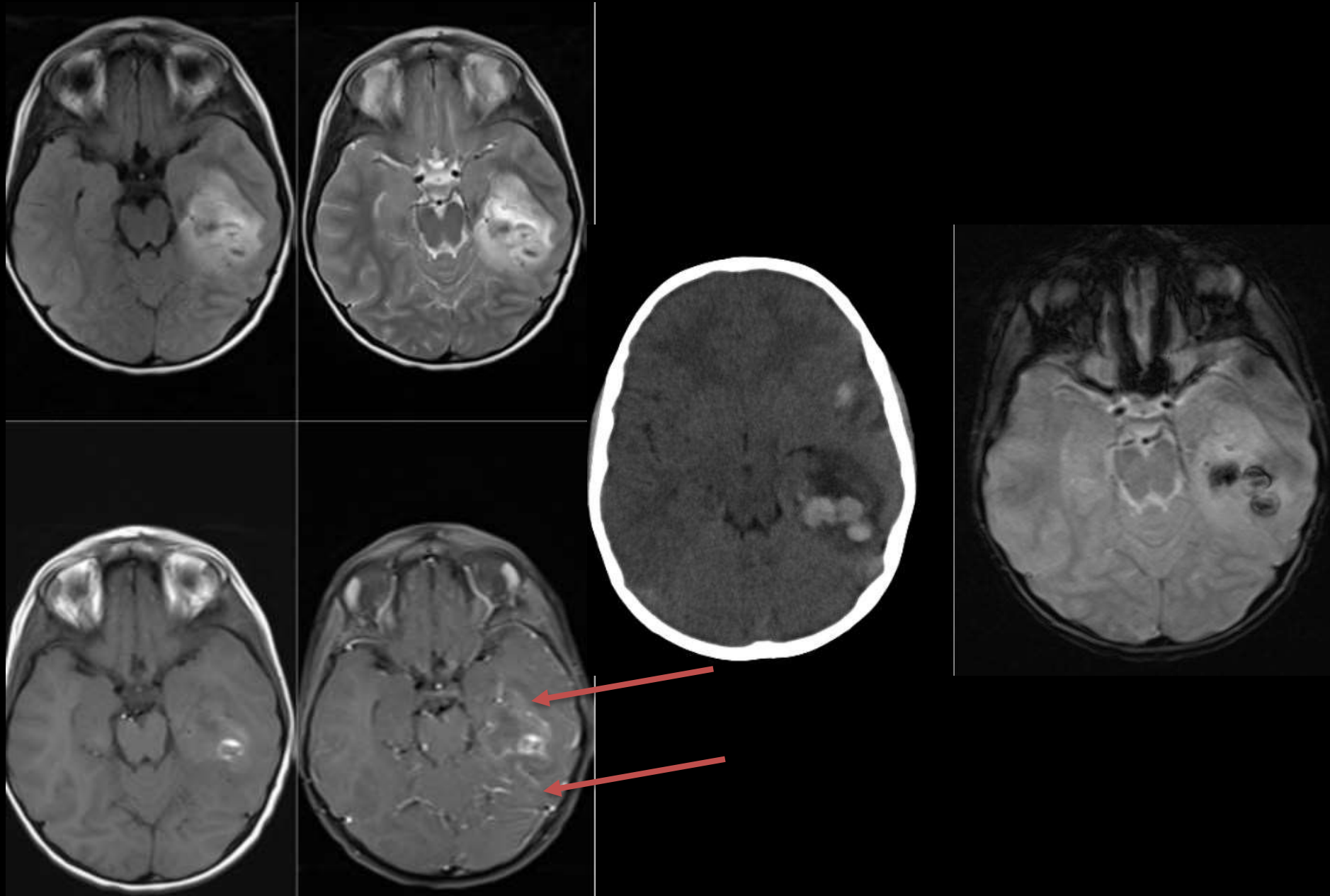
Olgu geçmişi

KLINİK BİLGİ ::OLFAKTOR HALISUNASYON?? EPILEPTİK NOBETLERDE ARTIŞHASTADA KALP PİLİ VAR MI ::YOKSTENT OYKUSU ::YOKTENT OYKUSU MR UYUMLU MU ::HAYIRMETALİK PROTEZ ::YOKMETALİK PROTEZ MR UYUMLU MU ::HAYIRALERJİ OYKUSU VAR MI ::YOKBOBREK YETMEZLİĞİ ::YOKVARSA, ÜRE-KR DEĞERİ ::HAYIRALEMİLE OLMA OLASILIĞI ::YOK F41.9-ANKSİYETE BOZUKLUGU, TANIMLANMAMIŞ

2 ve 8 ay sonra

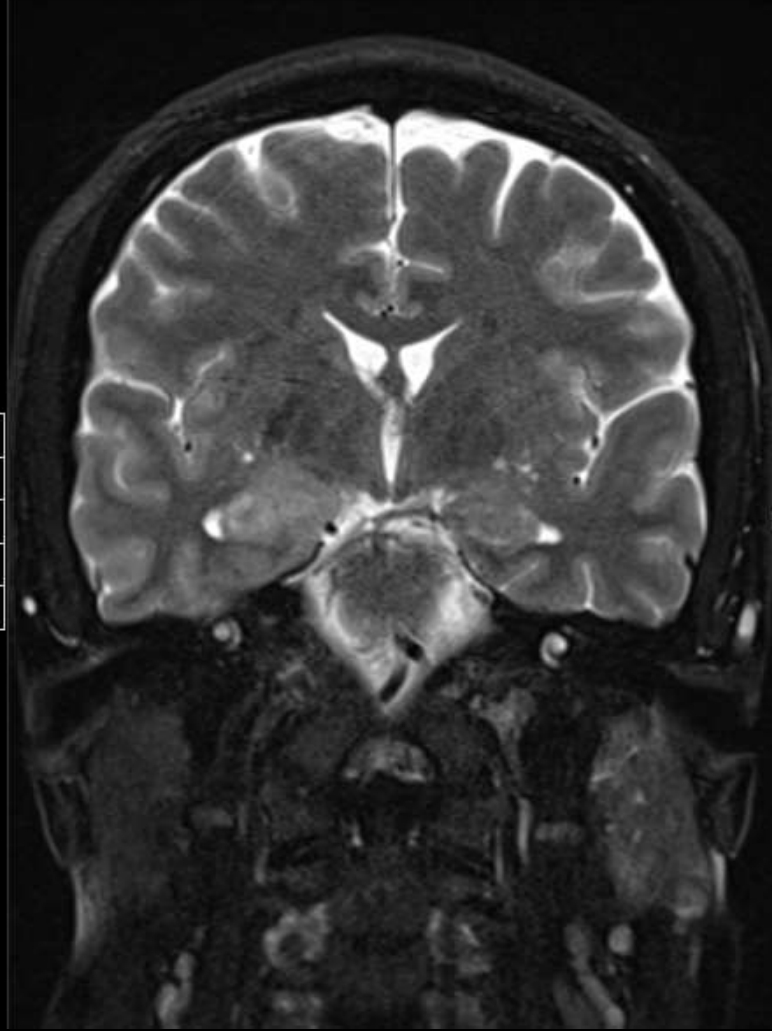
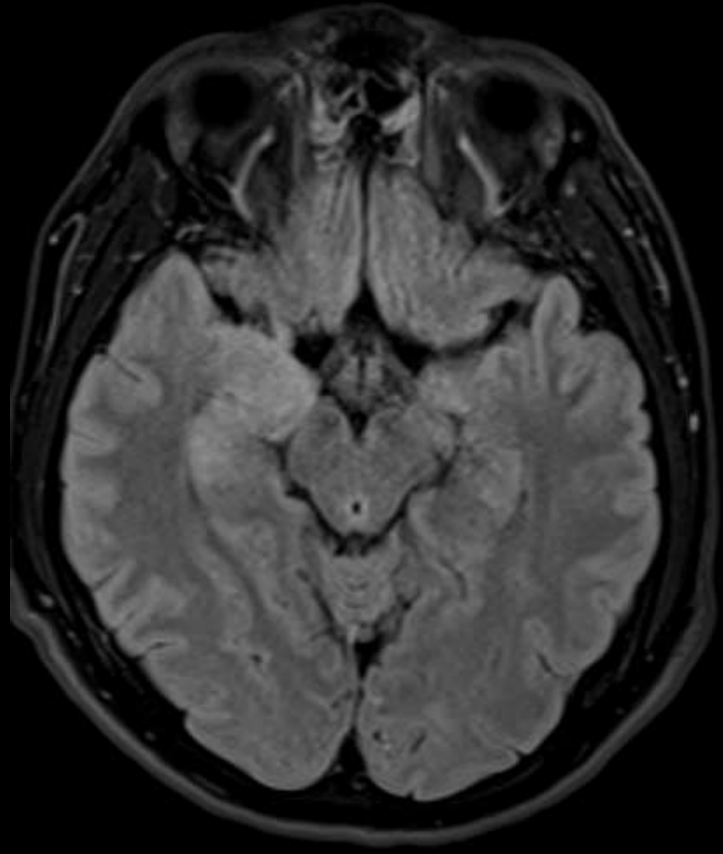


12 y , E, uykuya meyil, ateş



Olgu geçmişi

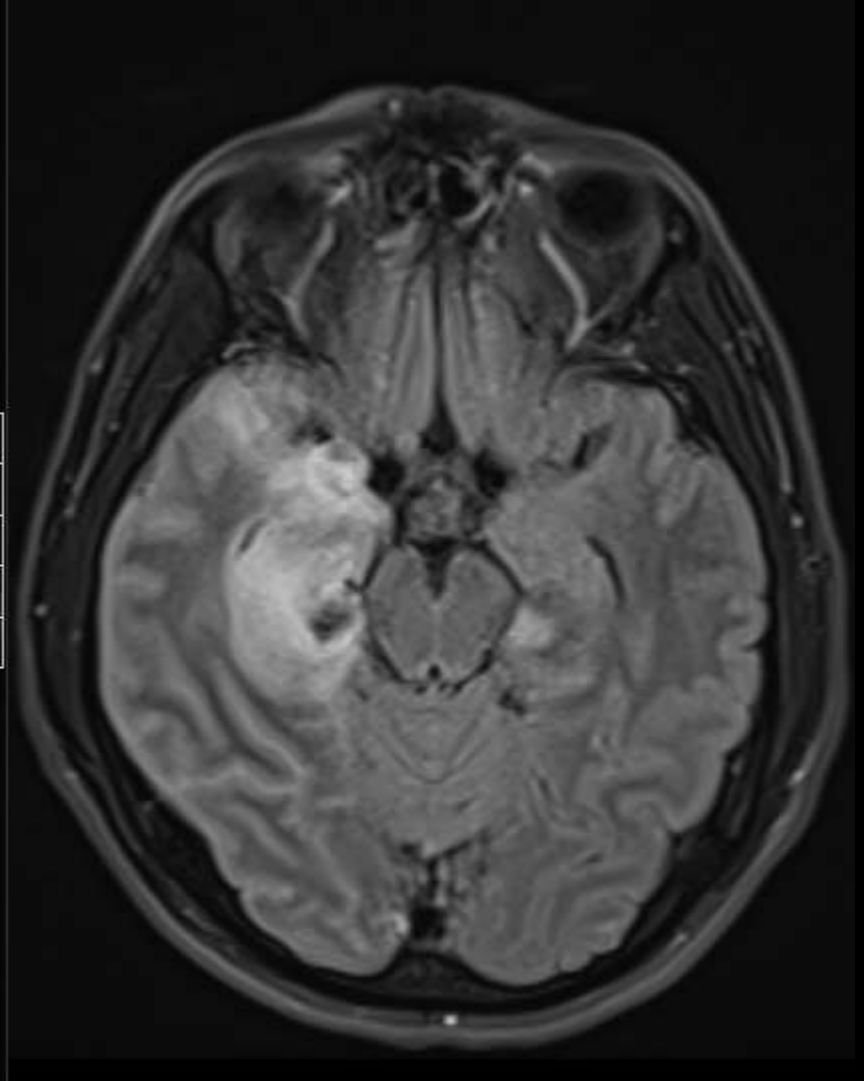
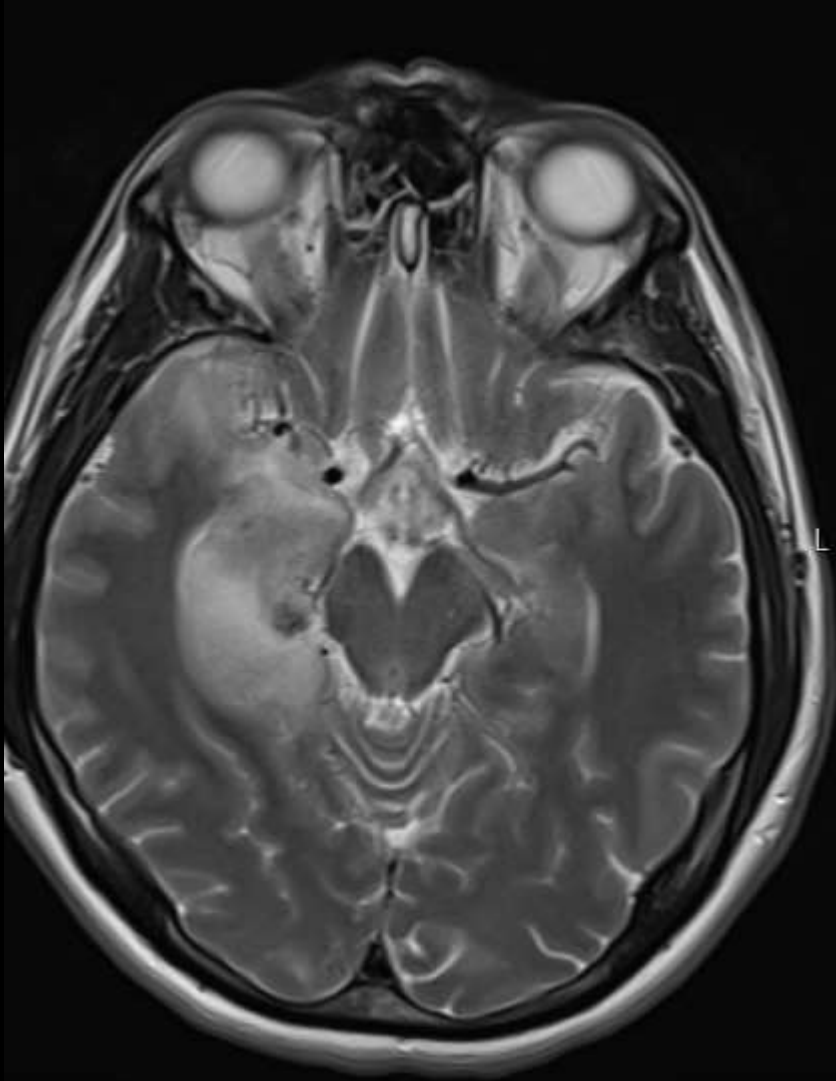
35 YAS KADIN HASTABH YOKHASTANIN 5 GUN ONCE BASLAYAN TERLEME VE SONRASINDA BILATERAL BAS AGRISI MEVCUT BULANTI KUSMASI VE BIR KERE BAYILMASI OLMUSDM CEKILEN



Özge geçmişi

KLINİK BILGI ::35 YAS ERKEK HASTABITEMPORAL BAS AGRISI VE BAYGINLIKLA AS BOSVURDU. DM DE CEKILEN MR I OTOIMMUN ENSEFALIT? SEKLİNDE. BOSTAN GONDERILEN HSV 1 PCR I POZITIF GELEN HASTA HSV ENSEFALITI TEDAVISI ALMAKTA, DIS MERKEZ MR I ILE KARSILASTIRMALI BEYIN MRININ YORUMLANMASI RICASIYLAHASTADA KALP PILI VAR MI ::YOKSTENT OYKUSU ::YOKSTENT OYKUSU MR UYUMLU MU ::HAYIRMETALIK PROTEZ ::YOKMETALIK PROTEZ MR UYUMLU MU ::HAYIRALERJI OYKUSU VAR MI ::YOKBOBREK YETMEZLIGI ::YOKVARSA, URE-KR DEGERI

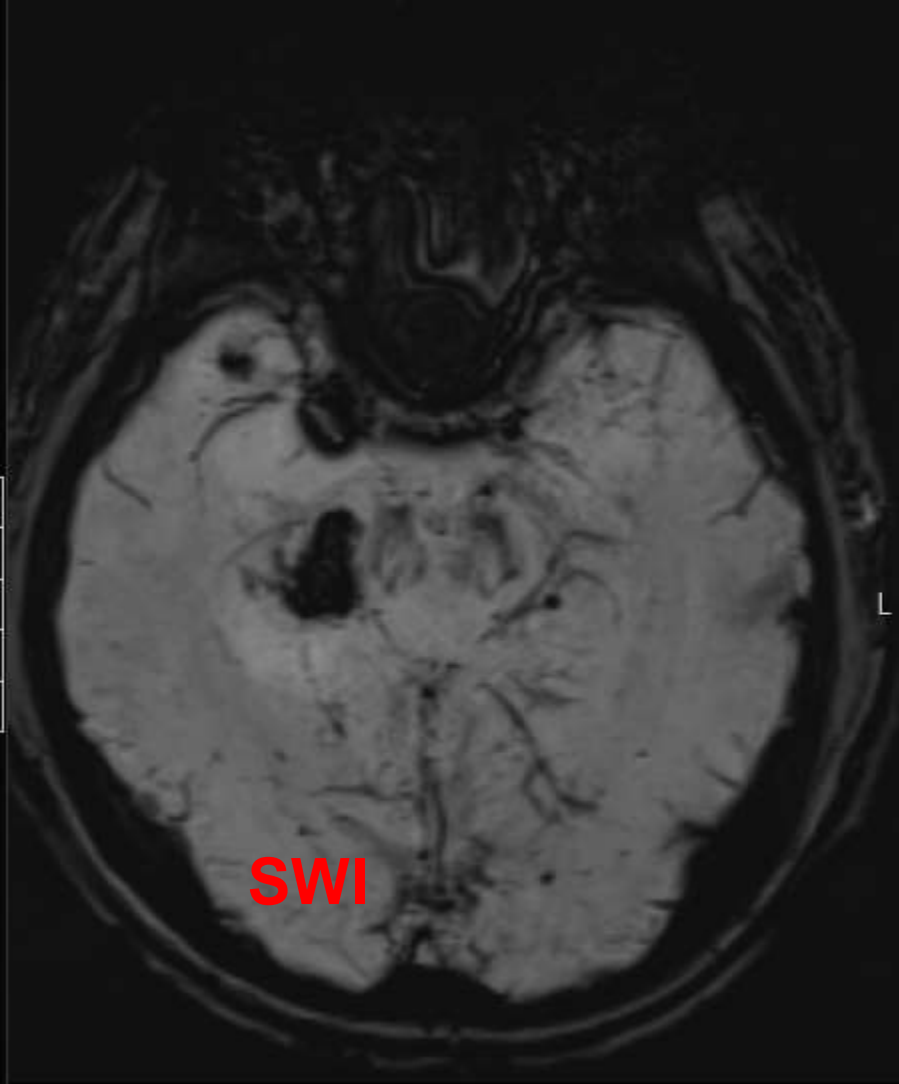
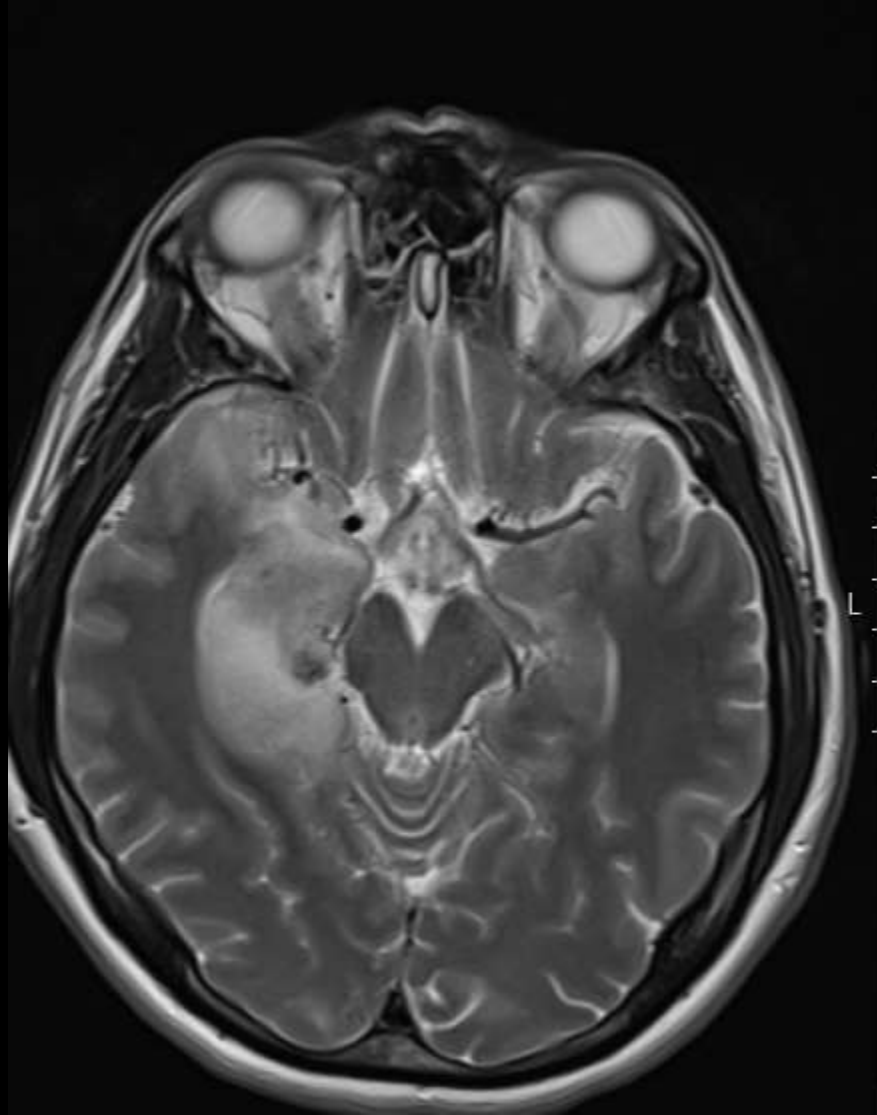
10 gün sonra



Özge geçmiştir

KLINİK BİLGİ ::35 YAS ERKEK HASTABİTEMPORAL BAS AGRISI VE BAYGINLIKLA AS BOSVURDU. DM DE ÇEKİLEN MR İ OTOİMMUN ENSEFALİT? SEKLİNDE. BOSTAN GONDERİLEN HSV 1 PCR İ POZİTİF GELEN HASTA HSV ENSEFALİTİ TEDAVİSİ ALMAKTA, DİS MERKEZ MR İ İLE KARSILAŞTIRMALI BEYİN MRİNİN YORUMLANMASI RİCASIYLAHASTADA KALP PİLİ VAR MI ::YOKSTENT OYKUSU ::YOKSTENT OYKUSU MR UYUMLU MU ::HAYİRMETALİK PROTEZ ::YOKMETALİK PROTEZ MR UYUMLU MU ::HAYİRALERJİ OYKUSU VAR MI ::YOKBOBREK YETMEZLİĞİ ::YOKVARSA, URE-KR DEĞERİ

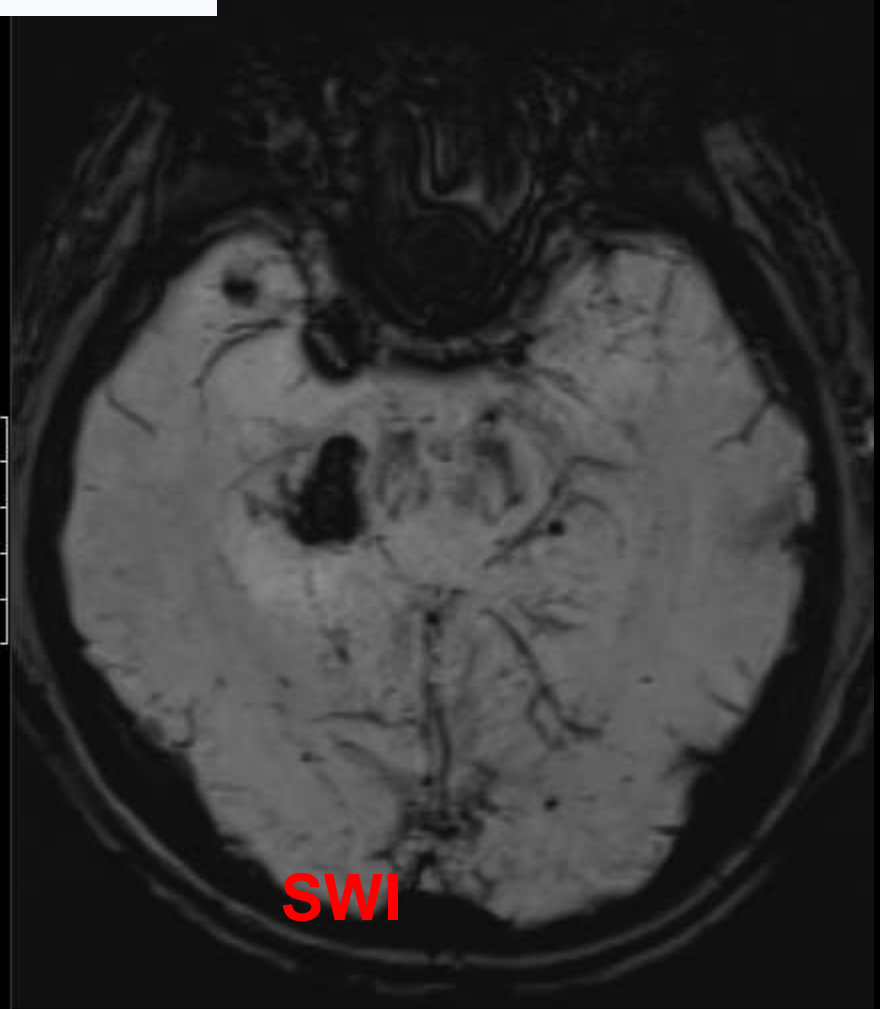
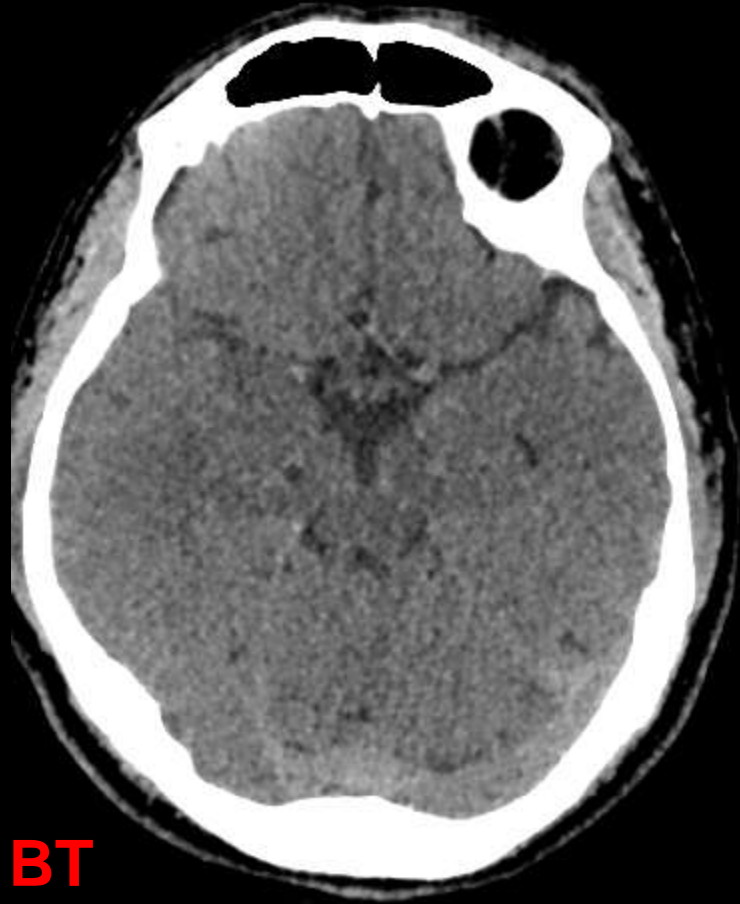
10 gün sonra



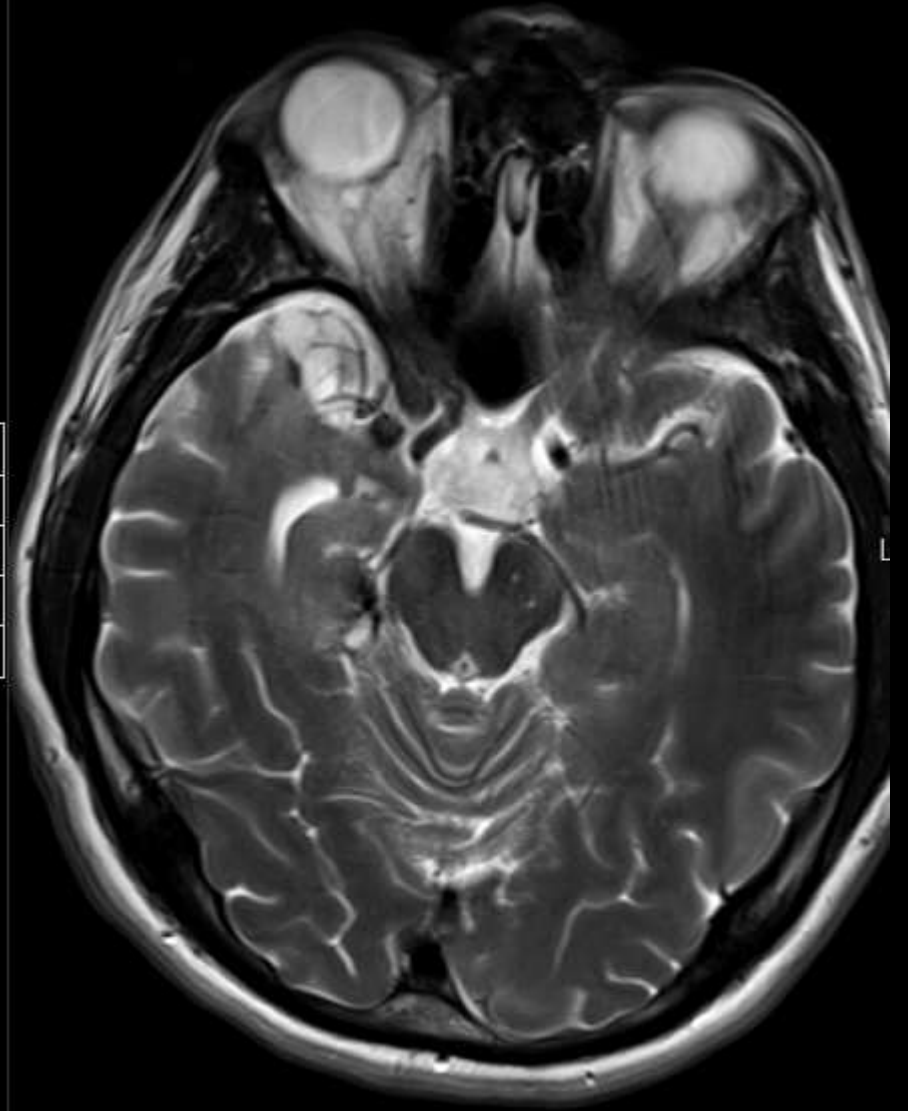
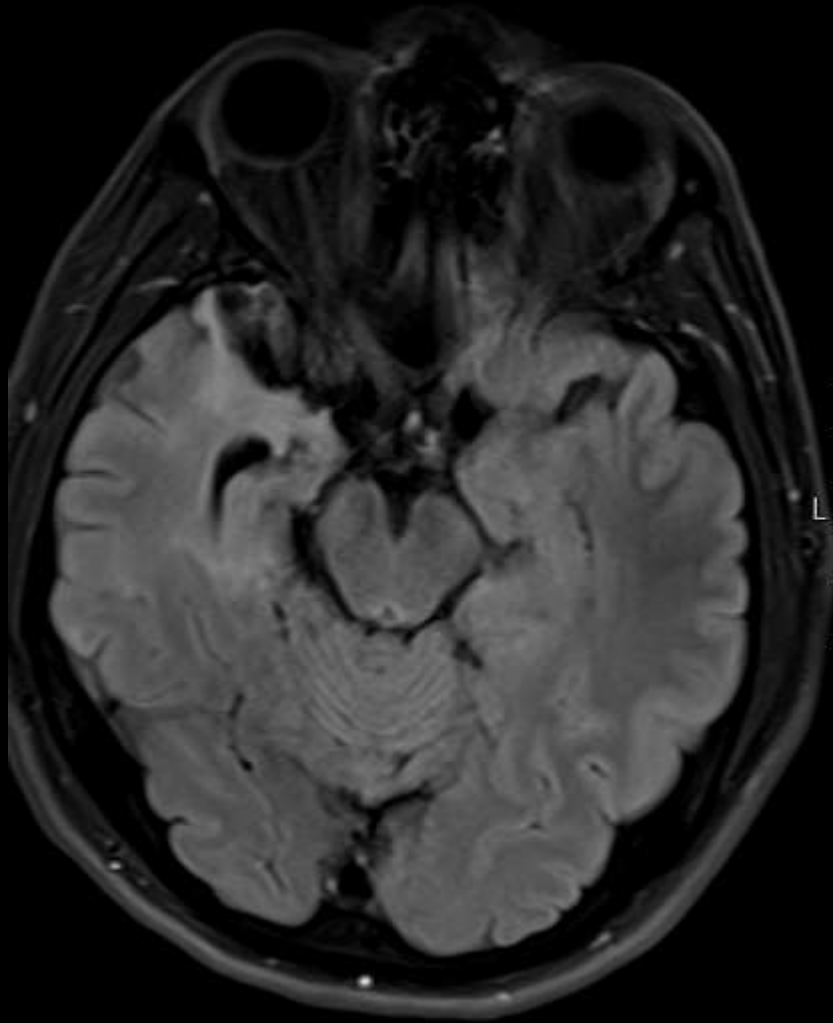
Özge geçmişi

KLINİK BİLGİ ::35 YAS ERKEK HASTABİTEMPORAL BAS AGRISI VE BAYGINLIĞLA AS BOSVURDU. DM DE ÇEKİLEN MR İ OTOİMMUN ENSEFALİT? SEKLİNDE. BOSTAN GONDERİLEN HSV 1 PCR İ POZİTİF GELEN HASTA HSV ENSEFALİTİ TEDAVİSİ ALMAKTA, DİS MERKEZ MR İ İLE KARSILAŞTIRMALI BEYİN MRİNİN YORUMLANMASI RİCASIYLAHASTADA KALP PİLİ VAR MI ::YOKSTENT OYKUSU ::YOKSTENT OYKUSU MR UYUMLU MU ::HAYIRMETALİK PROTEZ ::YOKMETALİK PROTEZ MR UYUMLU MU ::HAYİRALERJİ OYKUSU VAR MI ::YOKBOBREK YETMEZLİĞİ ::YOKVARSA, URE-KR DEĞERİ

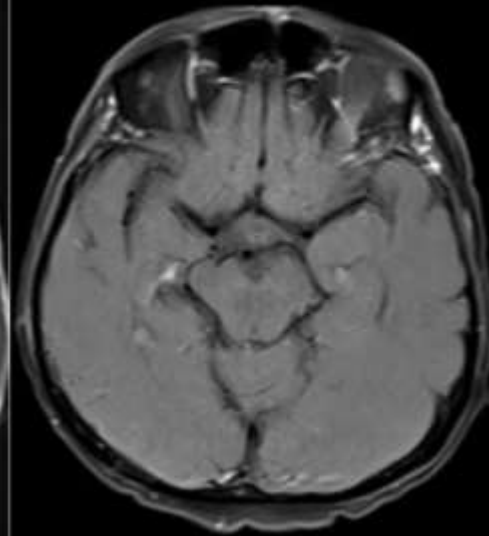
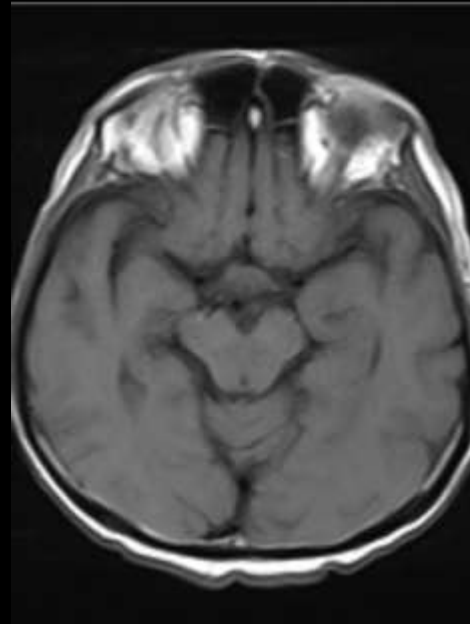
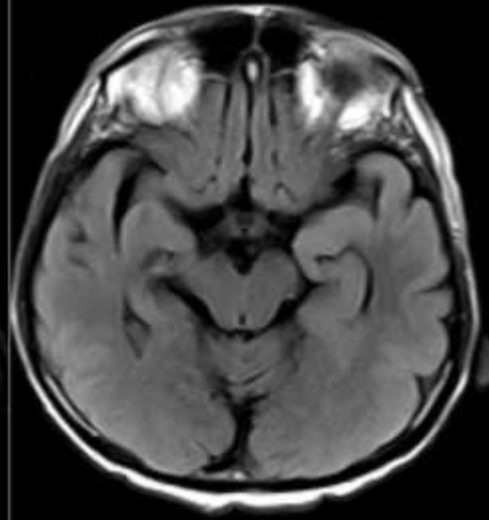
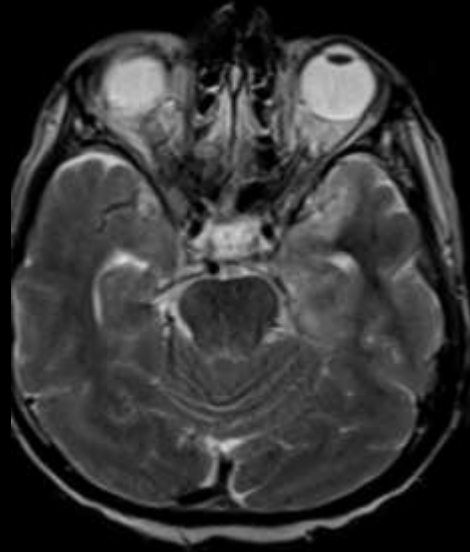10 gün sonra

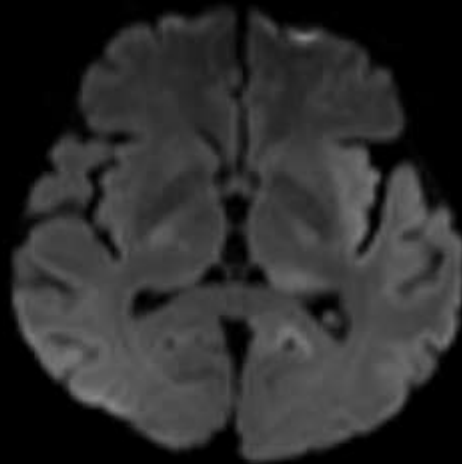
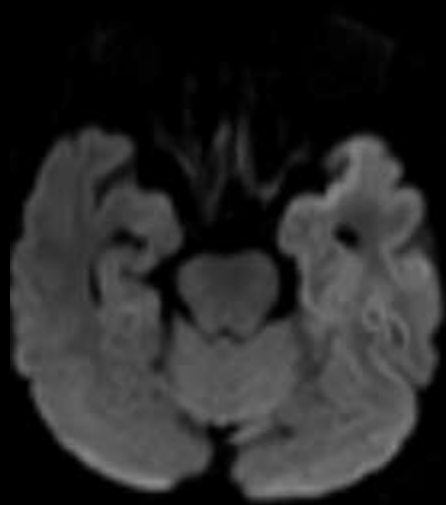


4 ay
sonra

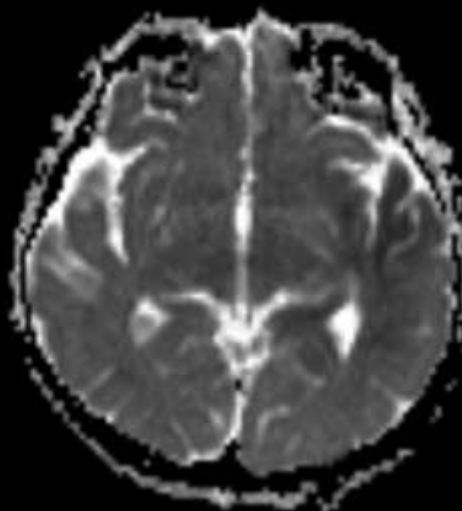
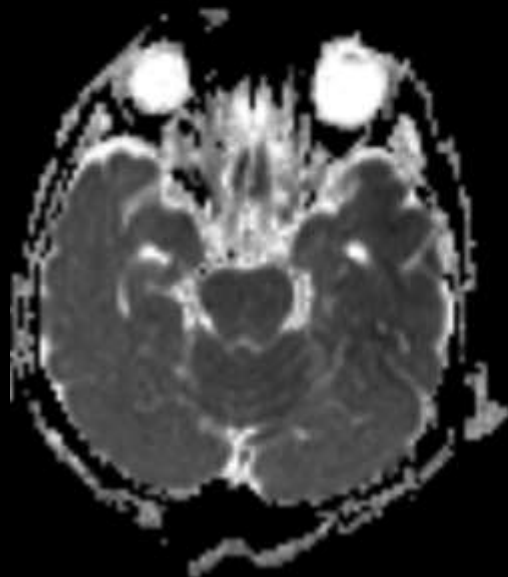


66 y, E, Mide Ca, Konfüzyon, Metastaz??



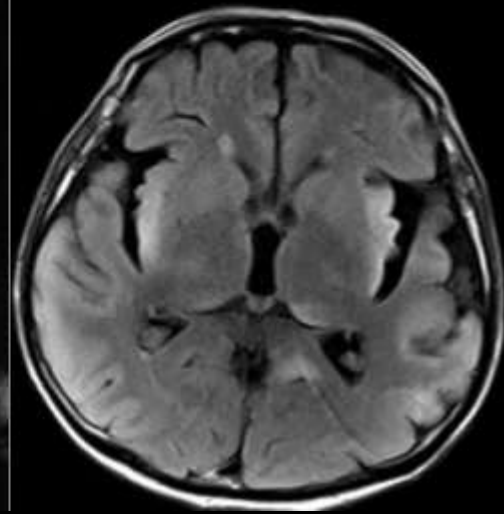
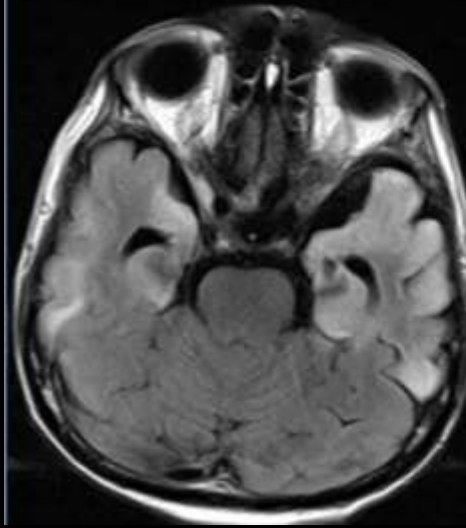
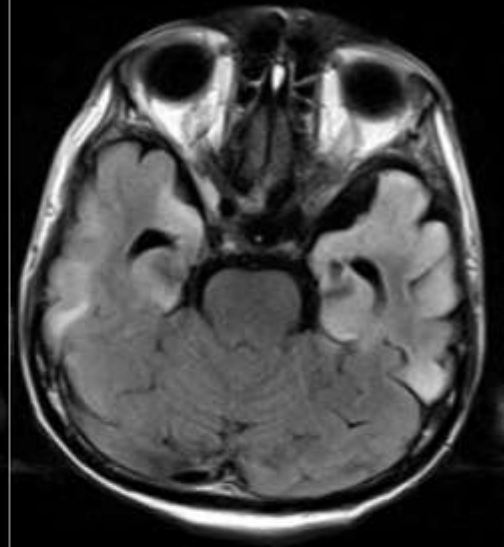
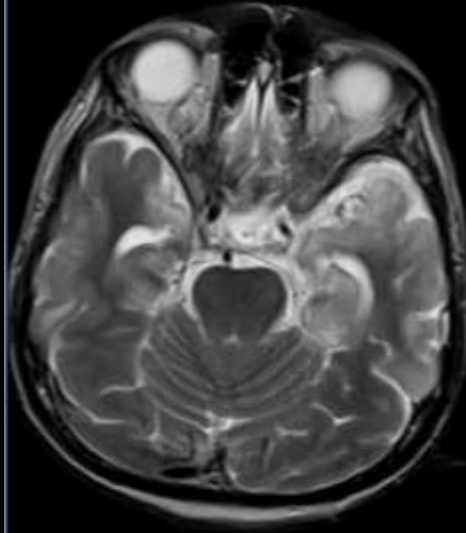


b1000

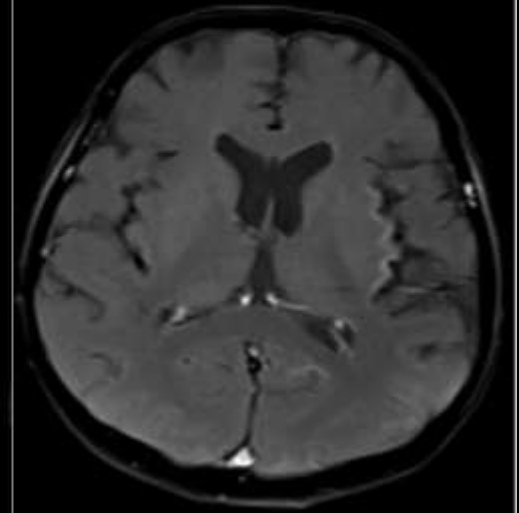
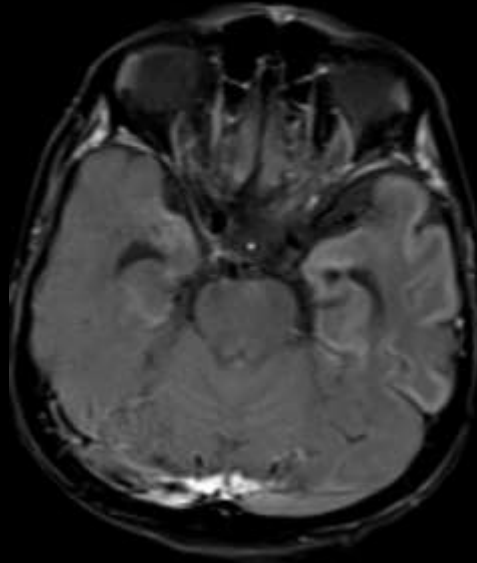
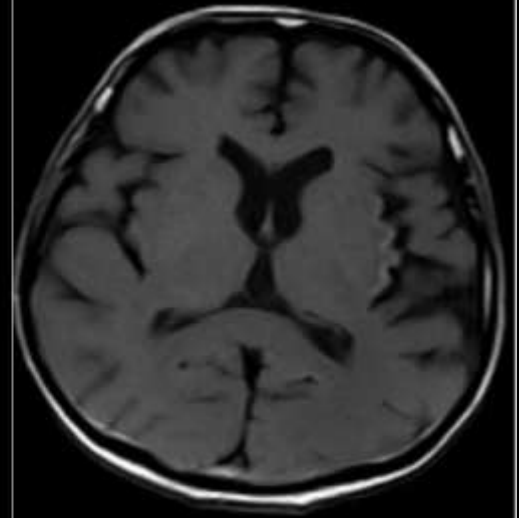
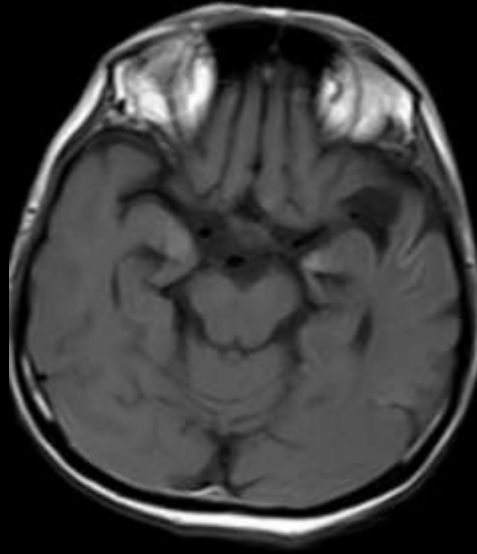


ADC

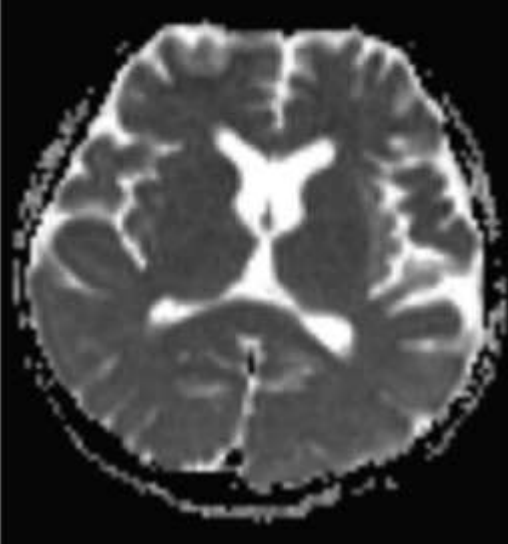
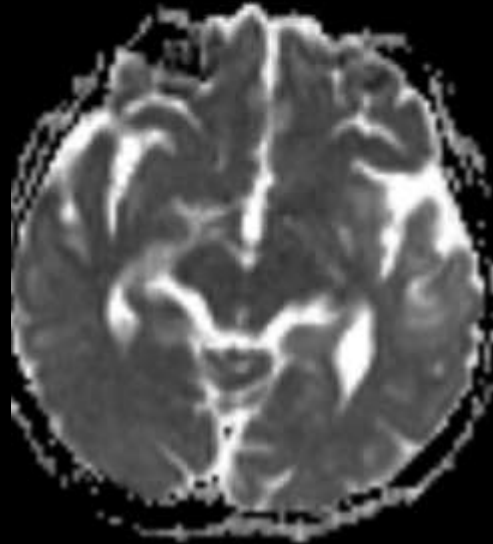
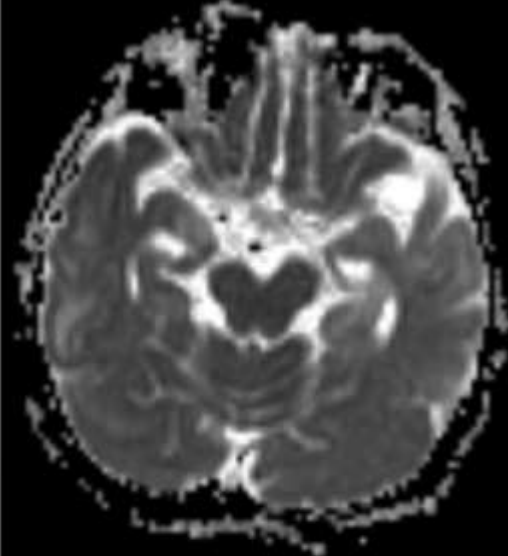
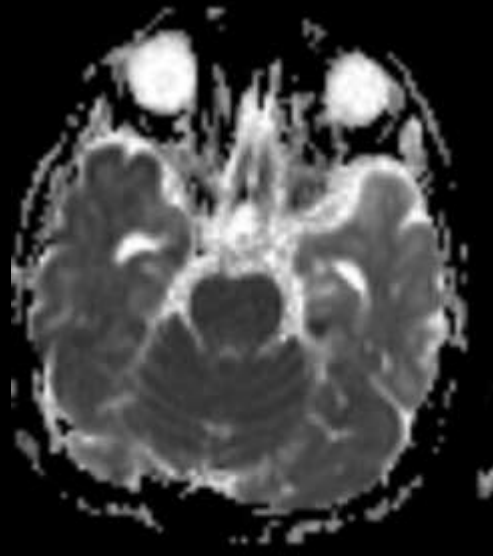
3 hafta
sonraki
izlem MRG



3 hafta
sonraki
izlem MRG

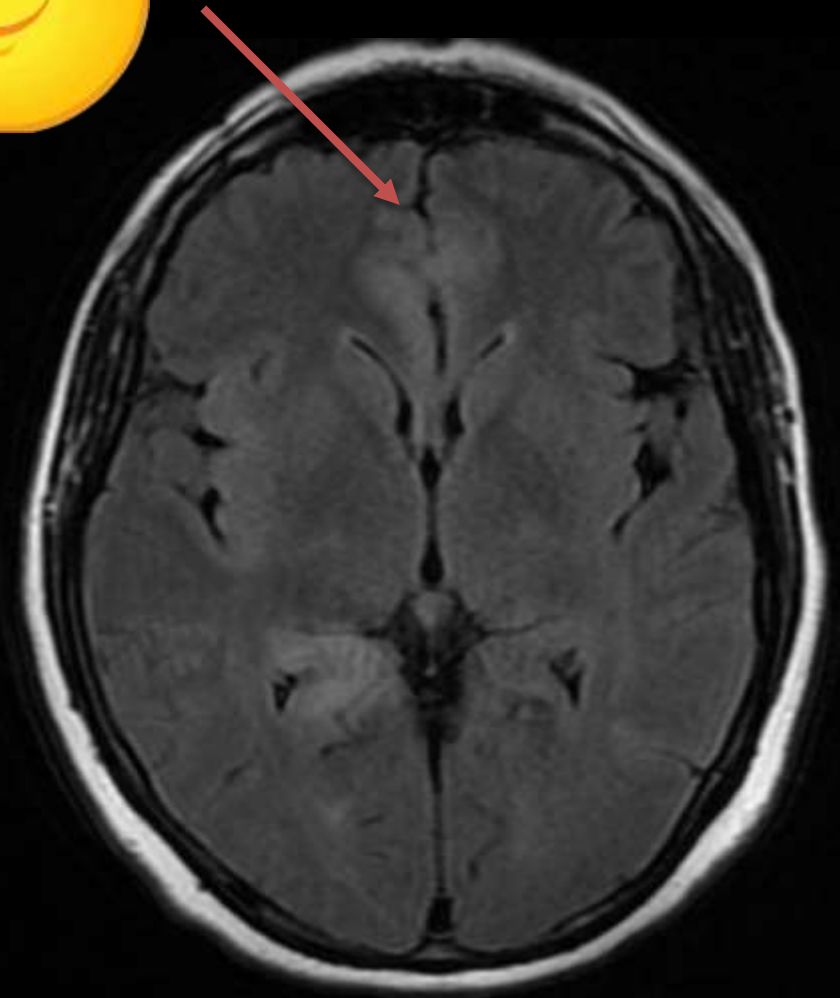
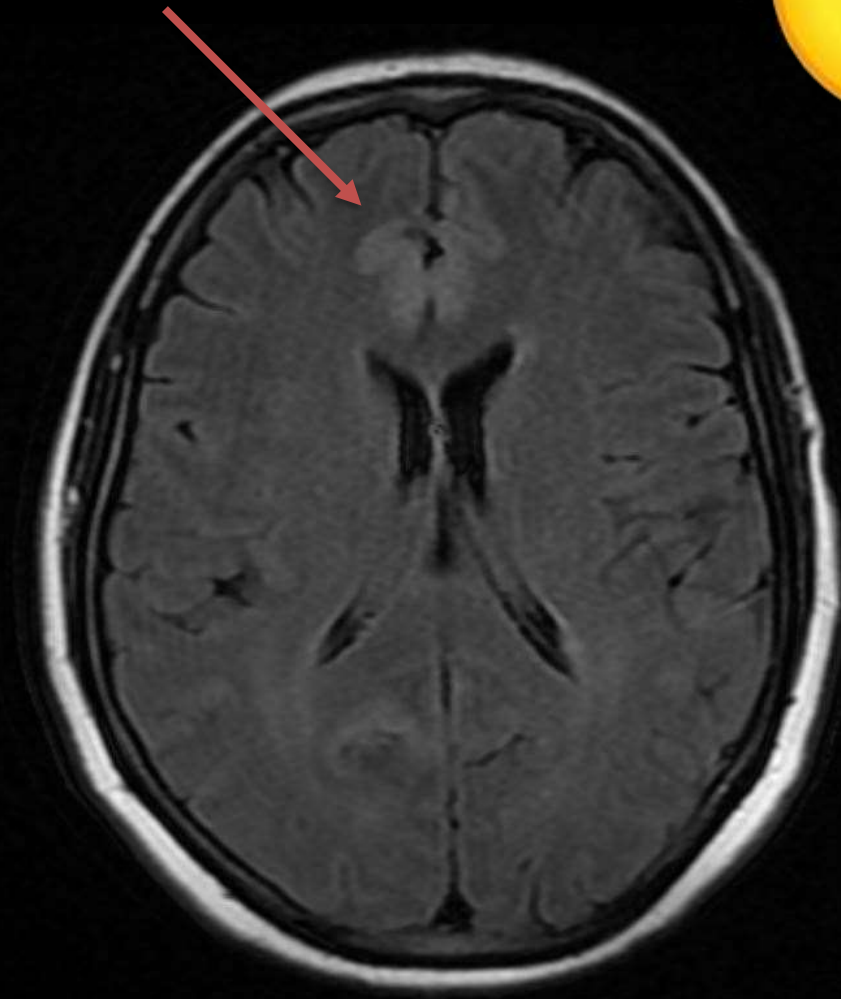


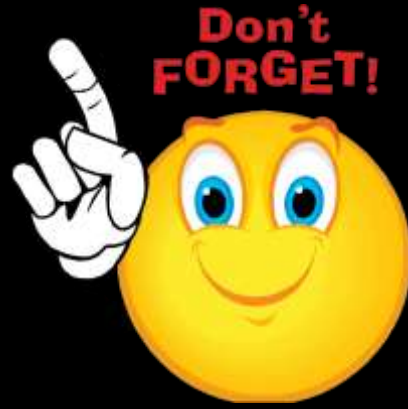3 hafta
sonraki
izlem MRG



Singulat girus
tutulumu

Don't
FORGET!





Takip bulguları/ tedavi sonrası görüntüleme özellikle önemli

Volüm azalması, sulkal derinleşme
Peteşial kortikal hemoraji
Kontrastlanmanın azalması

Olgu geçmişi

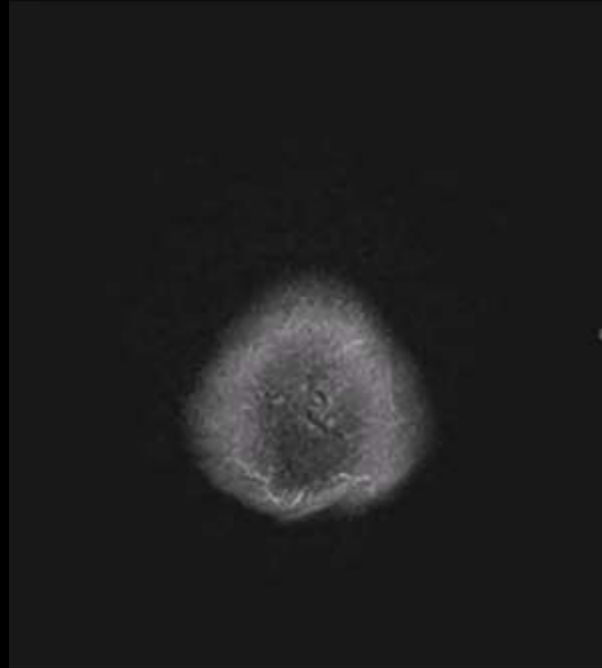
KLINIK BILGI ::ATES, AGIZDA SAPIRDANMA, OROFARINGEAL OTONOMİK HAREKETLER VE SOL KOLDA KAILMA İLE BASVURAN HASTA NOBET ETYOLOJISI ACISINDAN ENSEFALİT? DUSUK GRADE TM? TARAFINIZCA DEGERLENDIRILMESI RICASIYLAHASTADA KALP PILI VAR MI ::YOKSTENT OYKUSU ::YOKSTENT OYKUSU MR UYUMLU MU ::HAYIRMETALIK PROTEZ ::YOKMETALIK PROTEZ MR UYUMLU MU ::HAYIRALERJI OYKUSU VAR MI ::YOKBOBREK YETMEZLIGI ::YOKVARSA, URE-KR DEGERI ::HAMILE OLMA OLASILIGI ::YOK R68-GENEL SEMPTOM VE DİGER BELIRTLERE10.9-IN

Sequence: *f12d1_16
Kest: 5 mm
Dist: 6 mm
TR: 9000
TE: B4
TI: 2500
AC: 1

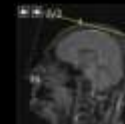C: 109.0, W: 274.0
Algot: 1/4
3.0

4.12_he_dark-fluid_br ->

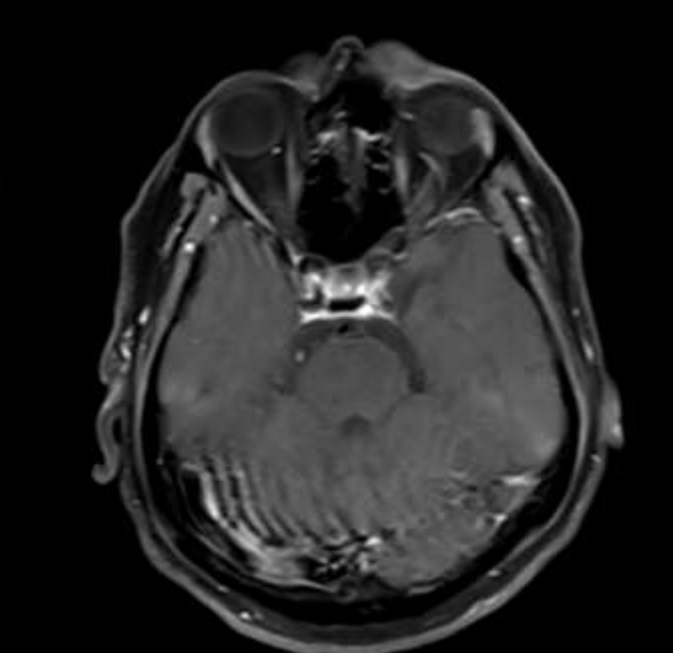
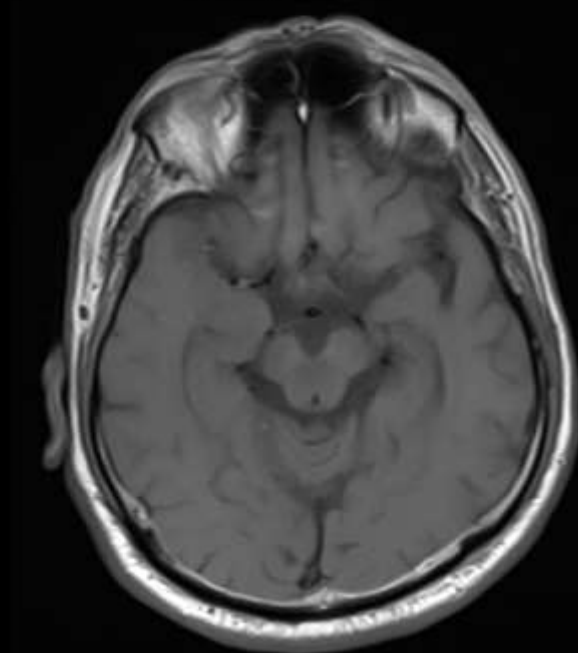
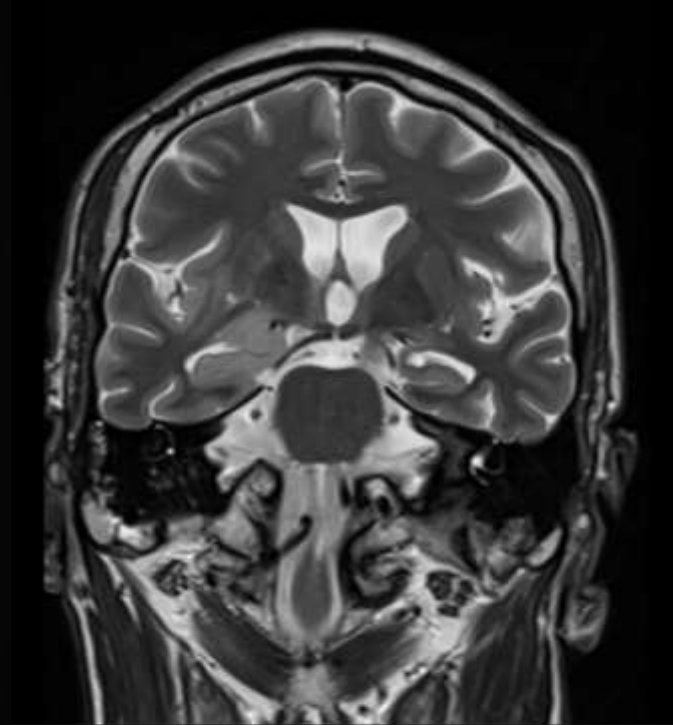
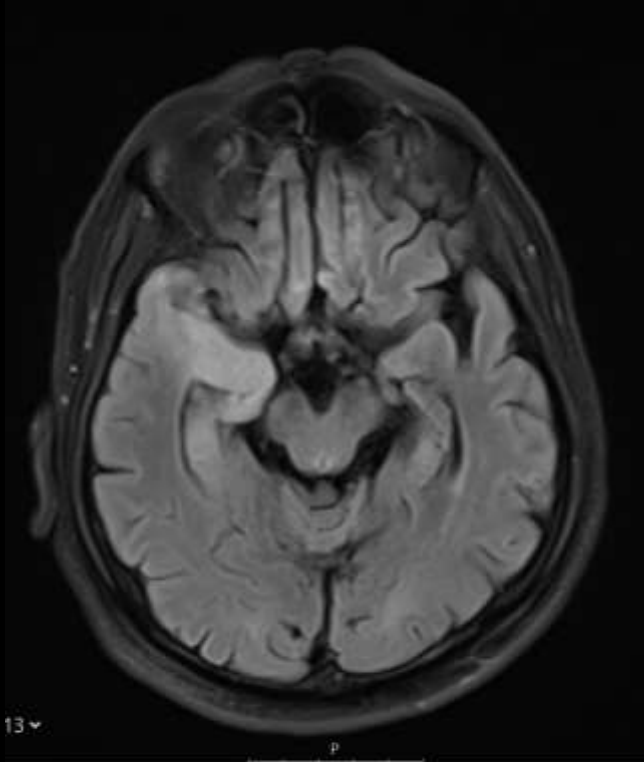
54y; E



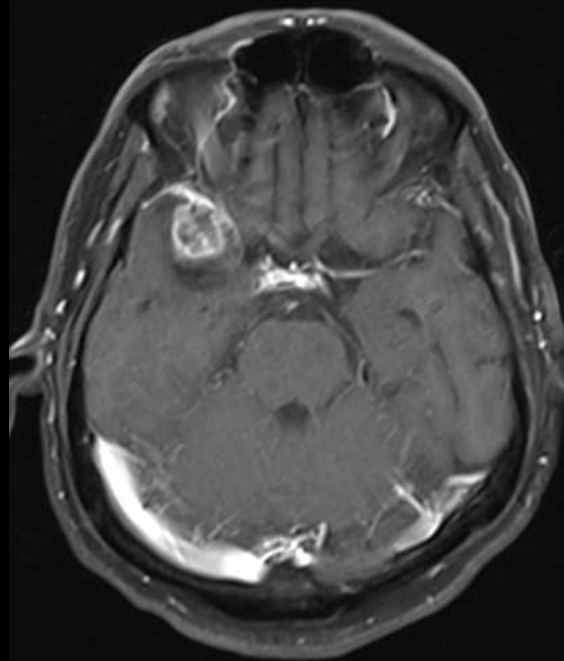
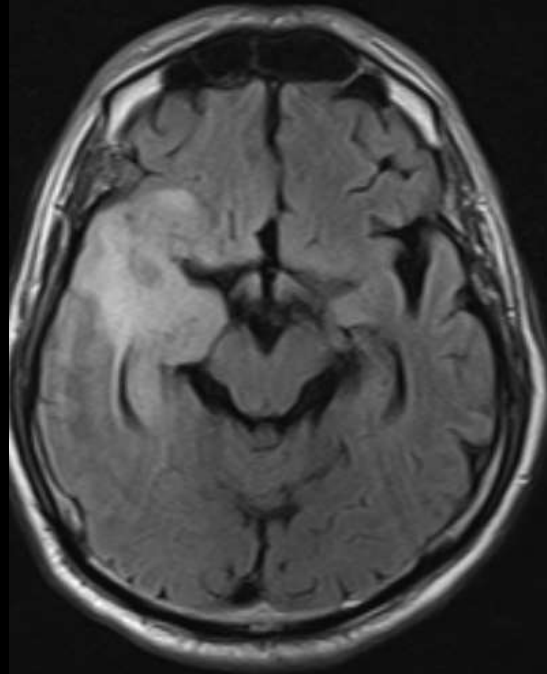
Poc HRS
Image nr: 25
Toplam 25 görüntüden 1.
▶ 28.07.2020, 19:49:48
SIEMENS, Aera

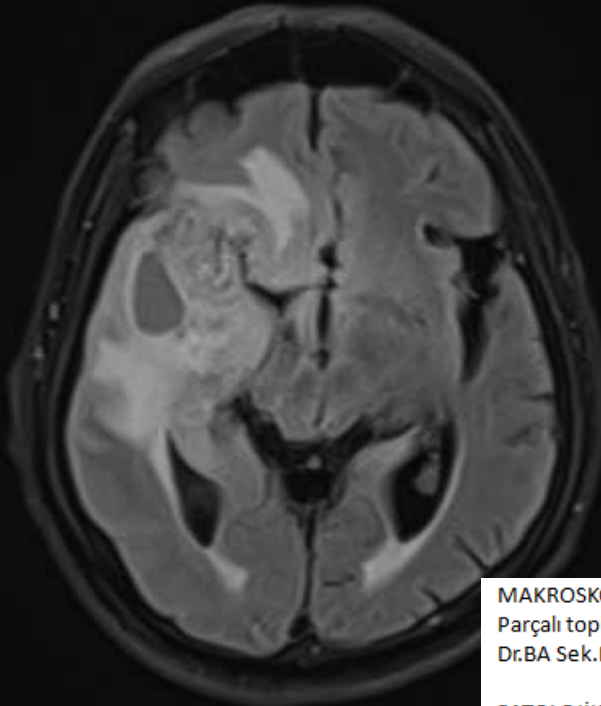


1 ay sonra

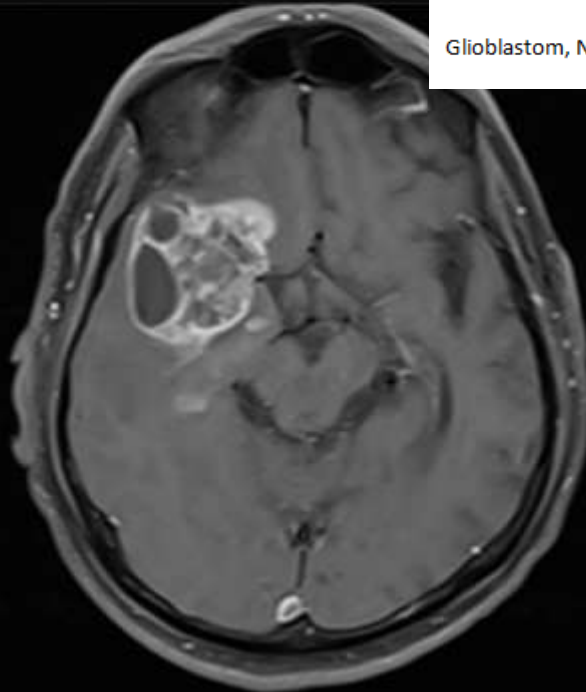


7 ay sonra





8 ay sonra



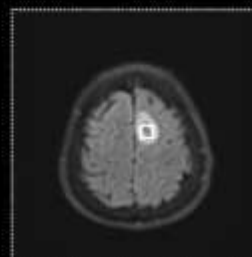
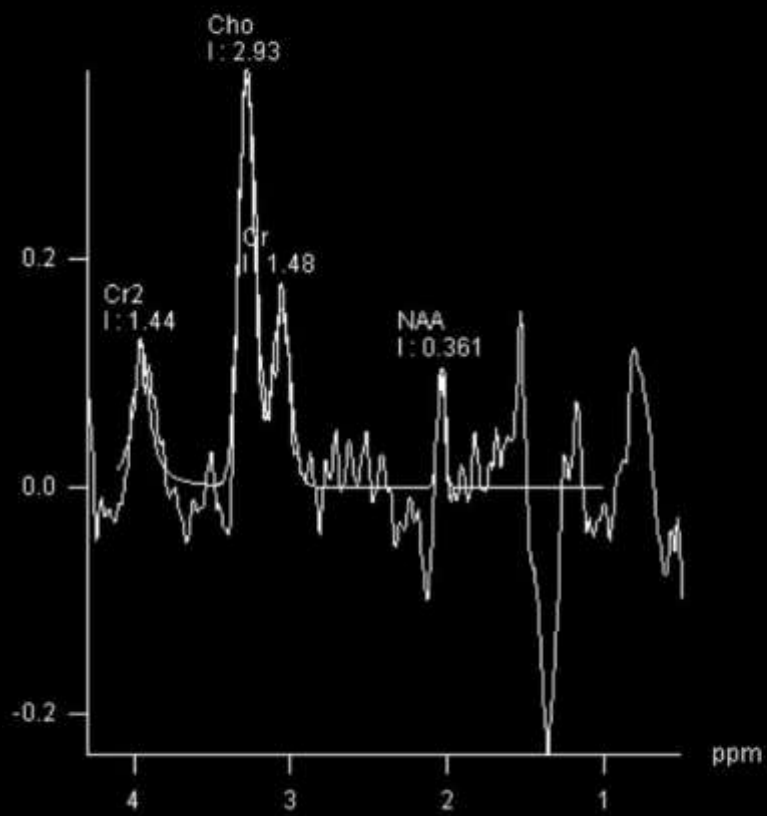
MAKROSKOPİ :

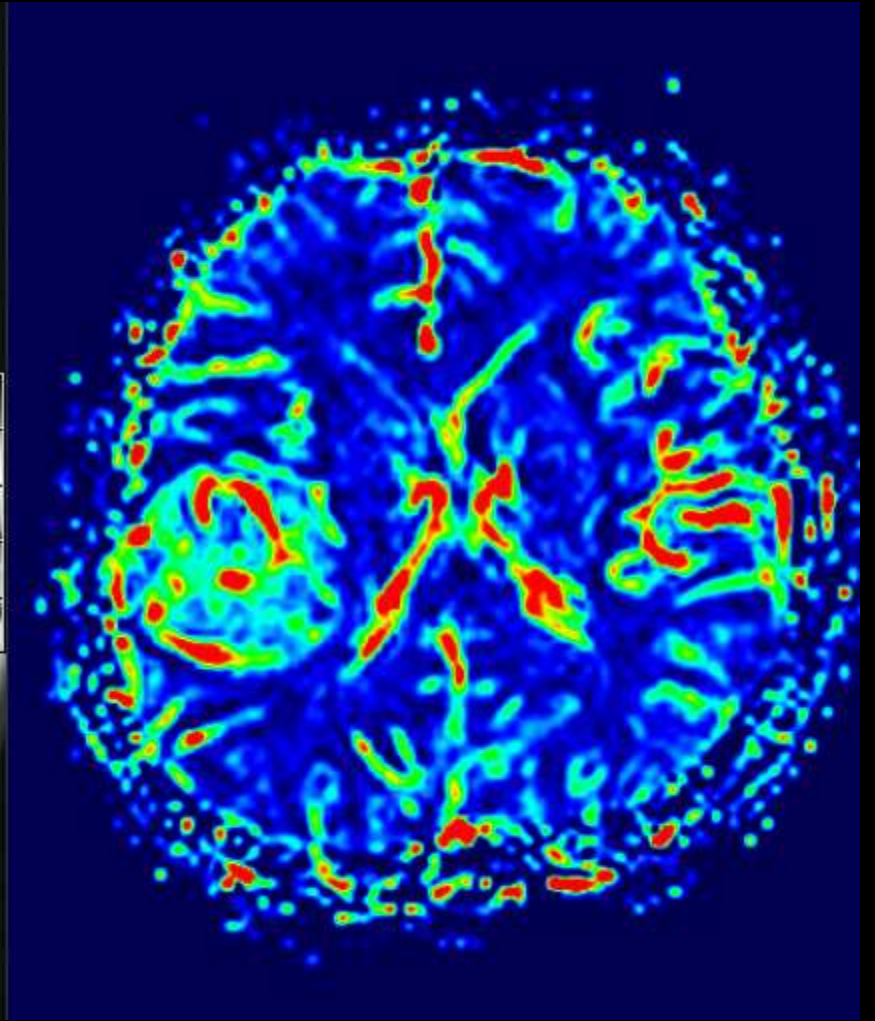
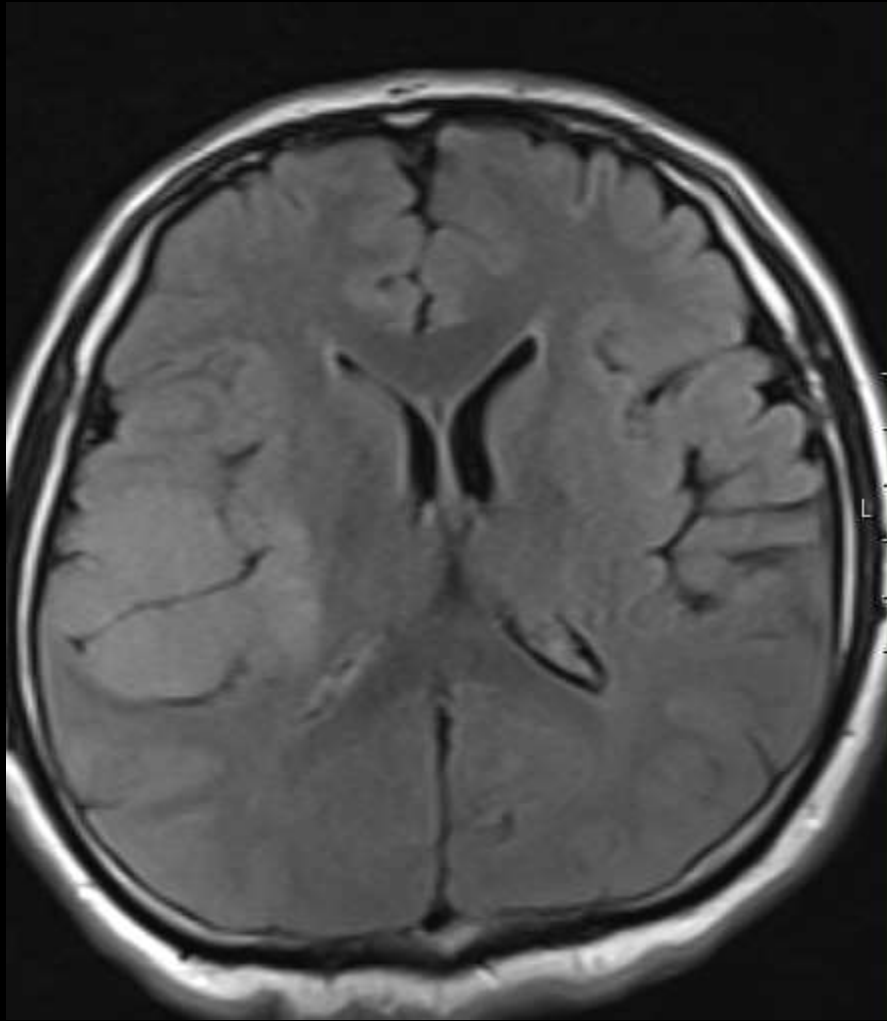
Parçalı topluca 6 cc hacminde krem renkte kanamalı yumuşak operasyon materyali T 2K 06.04.2021
Dr.BA Sek.NG

PATOLOJİK TANI :

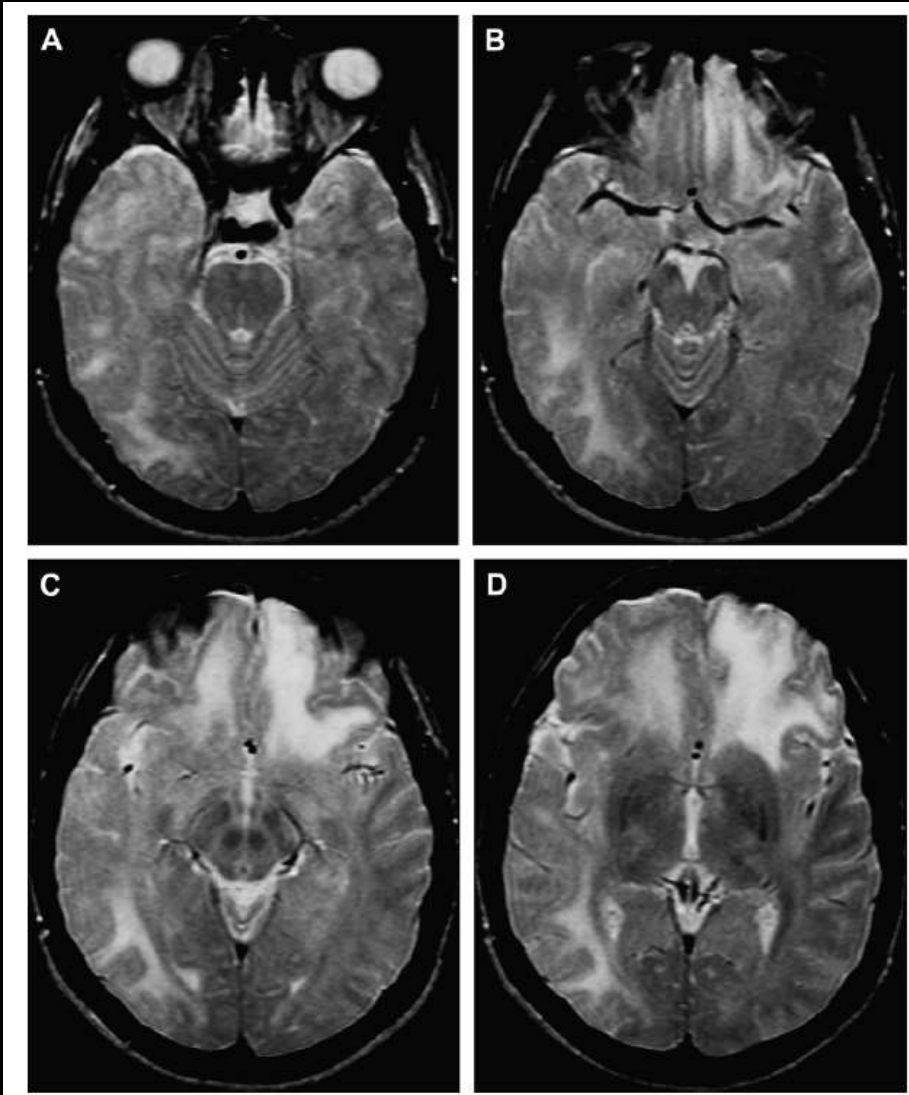
Glioblastom, NOS Derece IV, (WHO 2016) sağ frontotemporal bölge, eksizyonel biyopsi


I: Integral





HSV 2 Ensefaliti



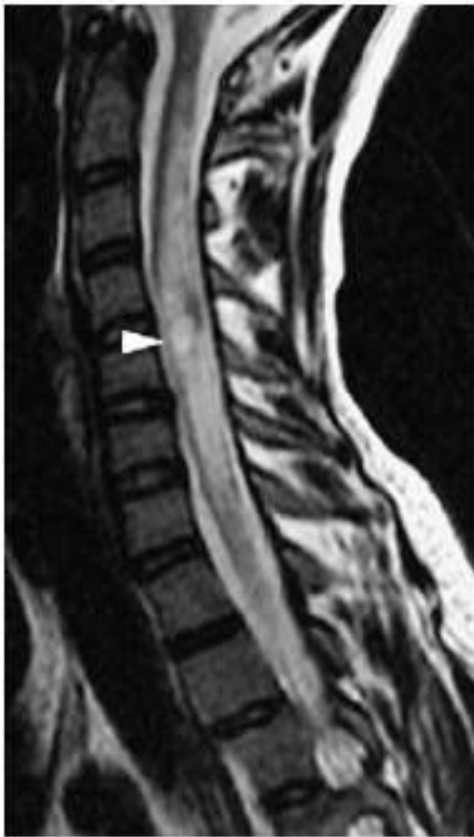 NEUROIMAGING
CLINICS
OF NORTH AMERICA

Neuroimaging Clin N Am 18 (2006) 53-84

**Central Nervous System Infections
of Herpesvirus Family**

Nail Bulakbasi, MD*, Murat Kocaoglu, MD

VZV Myelitis



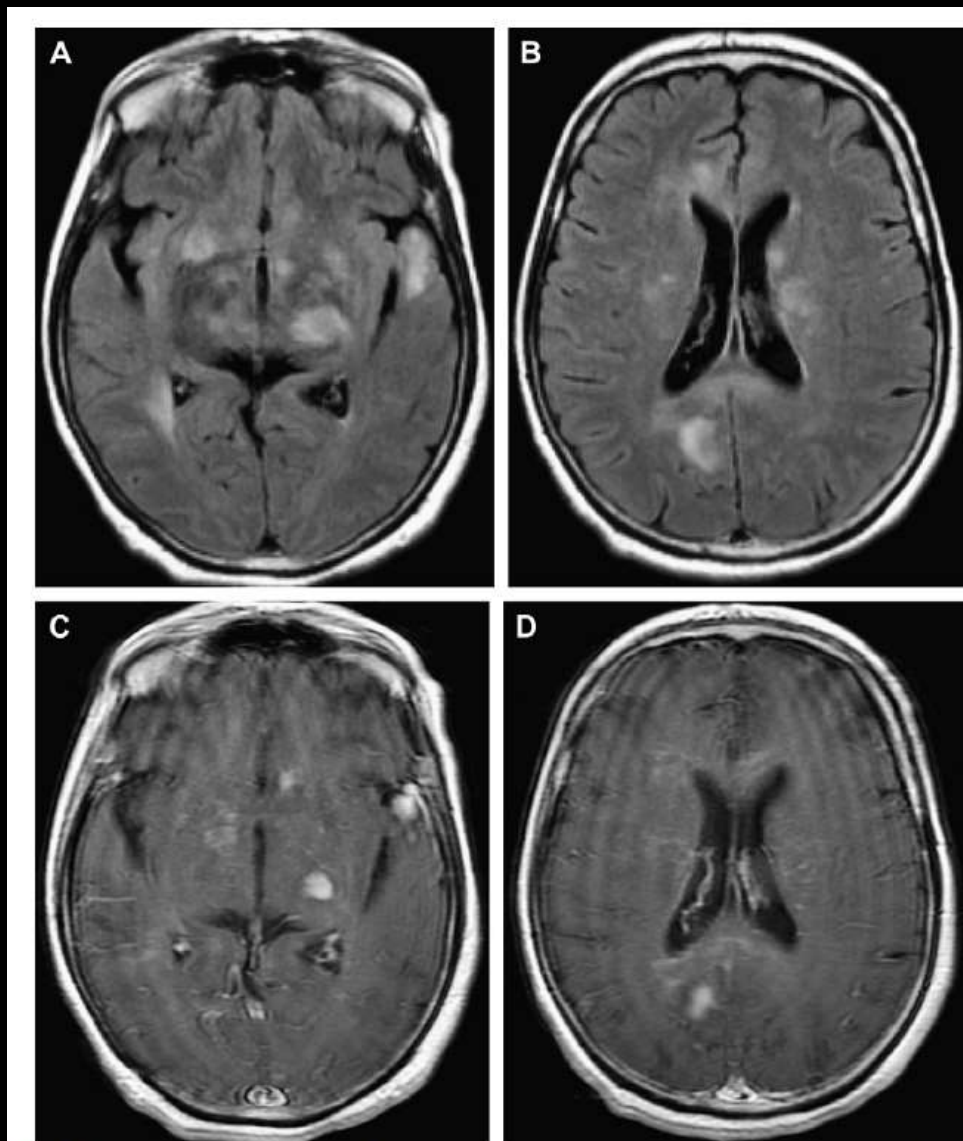
NEUROIMAGING
CLINICS
OF NORTH AMERICA

Neuroimaging Clin N Am 18 (2006) 53-64


Central Nervous System Infections of Herpesvirus Family

Nail Bulakbasi, MD*, Murat Kocaoglu, MD

EBV ensefaliti



20. EBV-related encephalitis. Consecutive axial images of FLAIR (A–B) and contrast-enhanced T1W

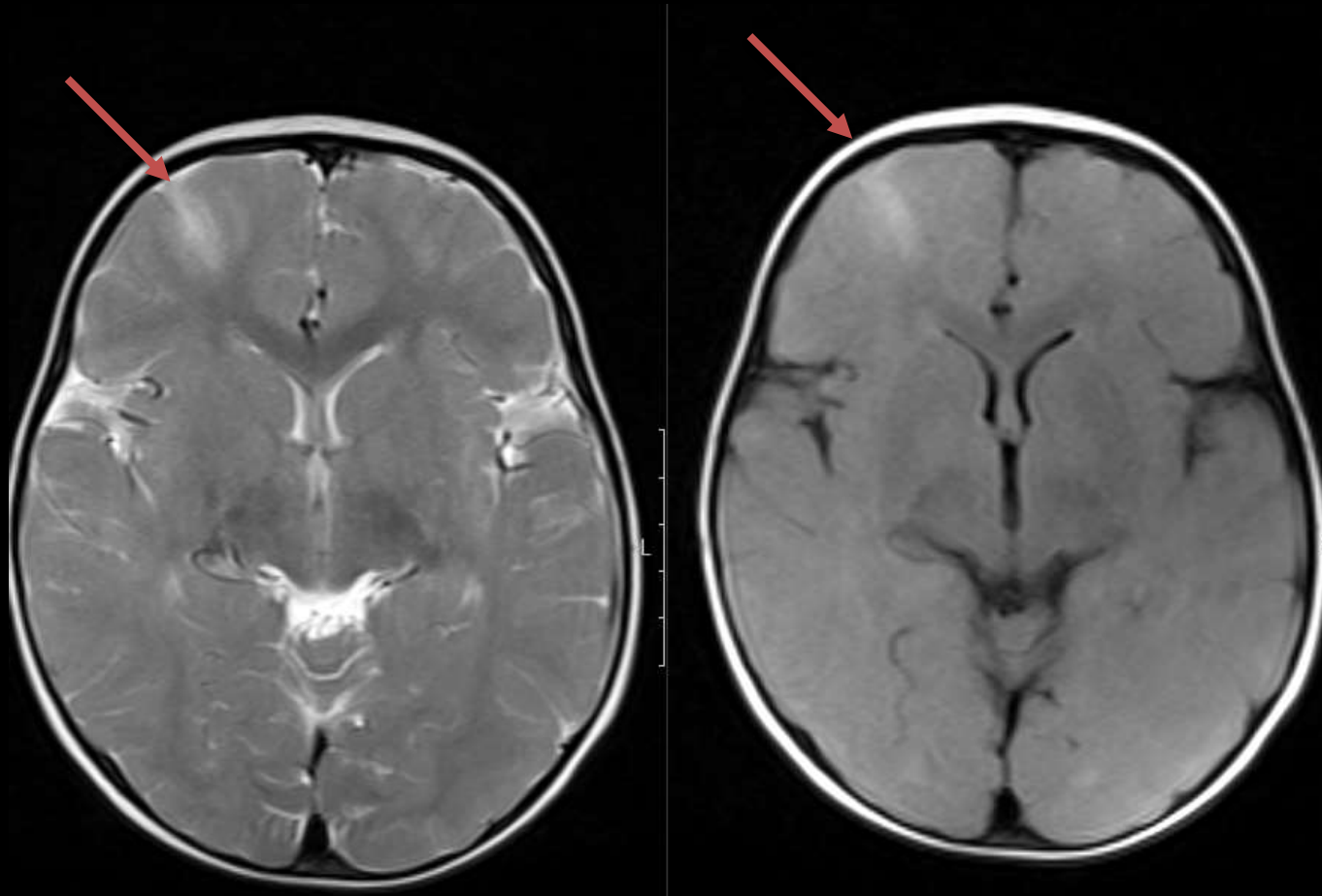
 NEUROIMAGING
CLINICS
OF NORTH AMERICA

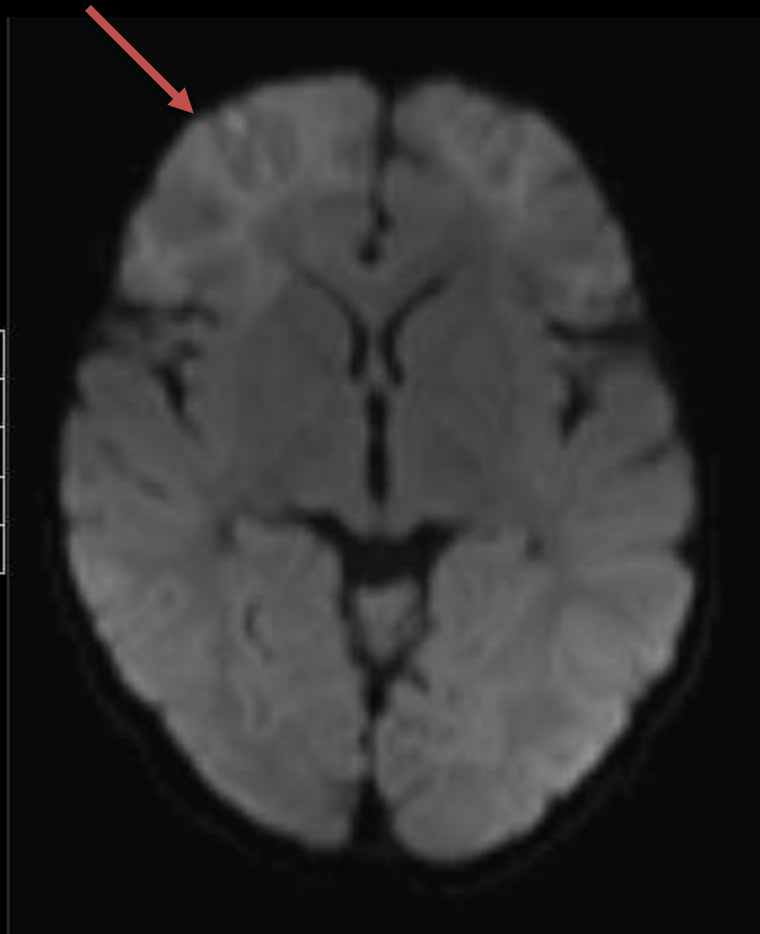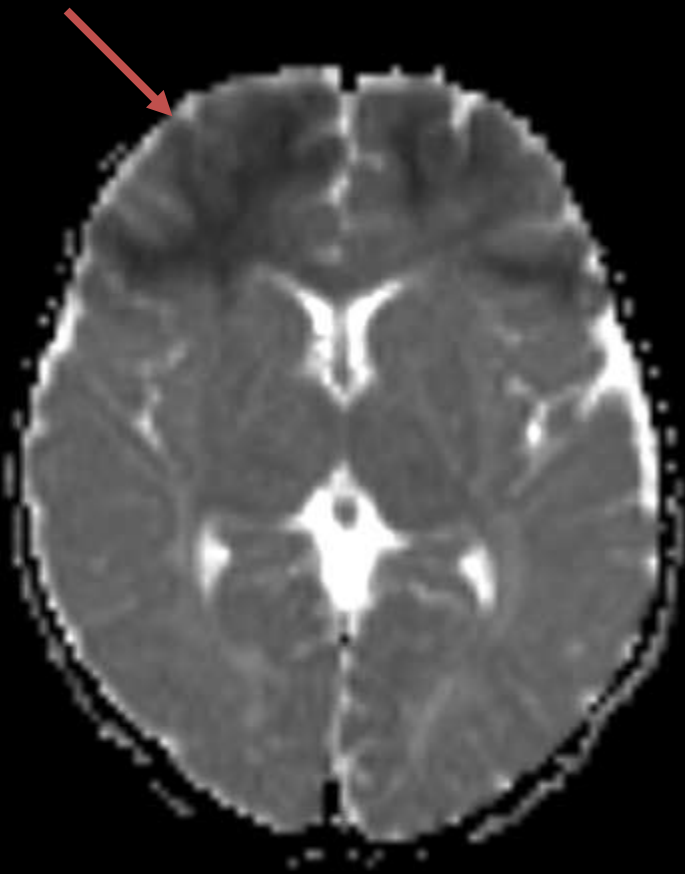
Neuroimaging Clin N Am 18 (2006) 53–84

**Central Nervous System Infections
of Herpesvirus Family**

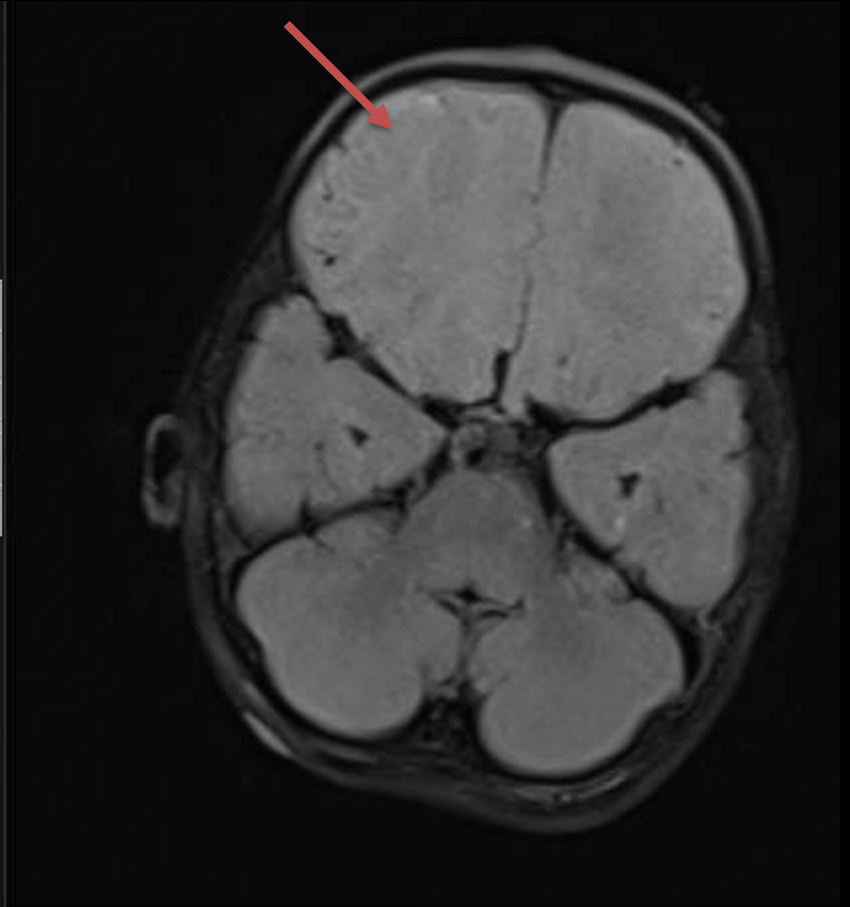
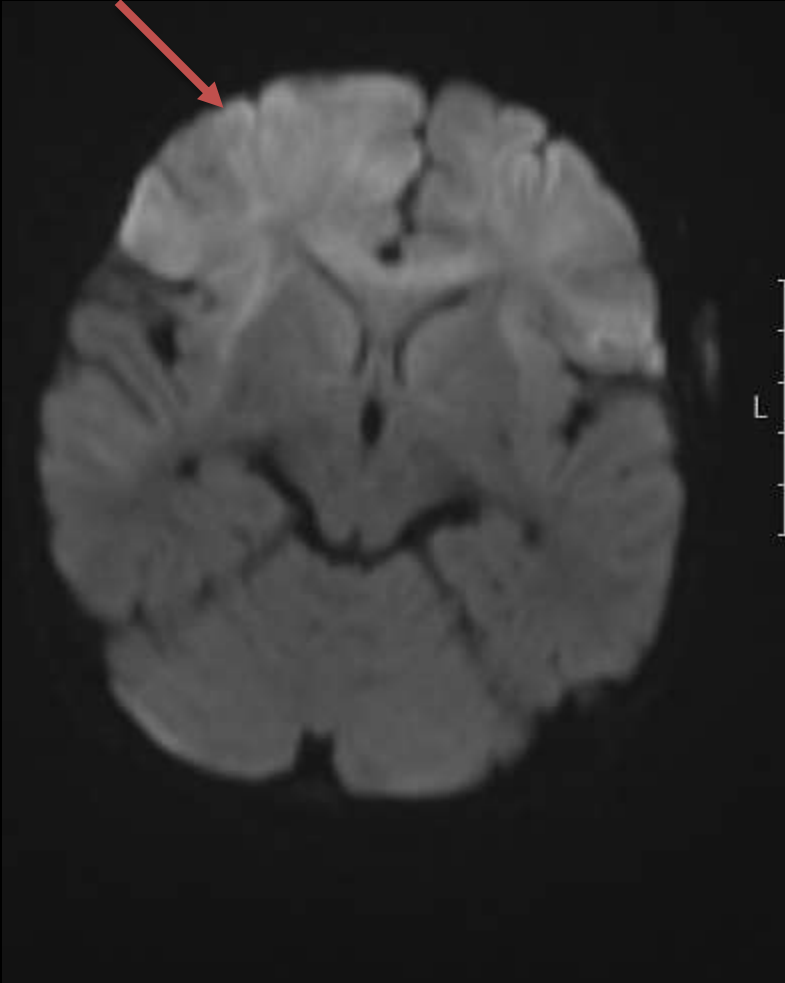
Nail Bulakbasi, MD*, Murat Kocaoglu, MD

Otoimmün ensefalitler

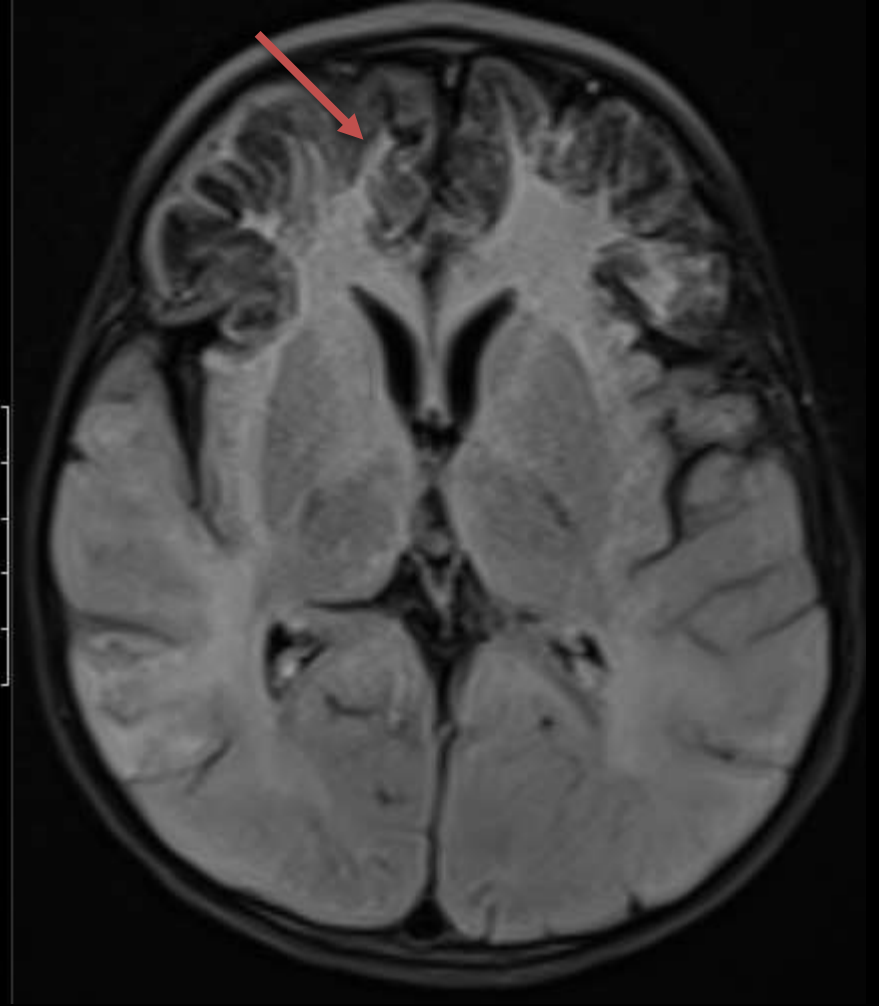
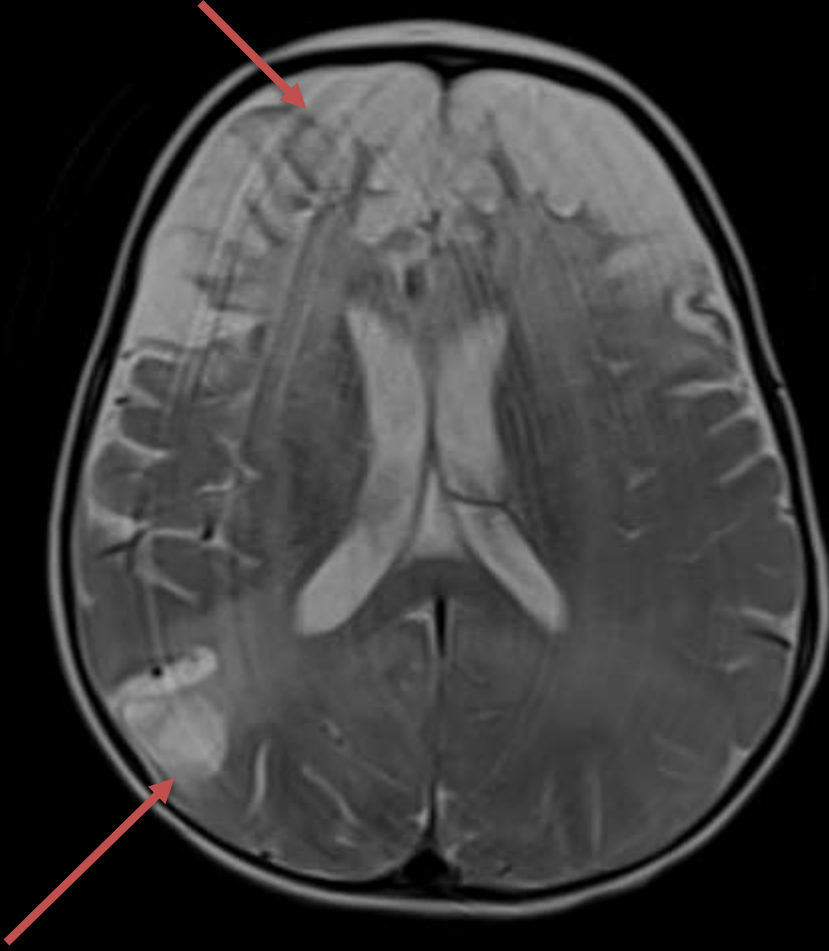




1 hafta sonra



45 gün sonra



NMDA pozitif otoimmün
ensefalit

Antigenic target	Neuronal localisation	Presenting symptoms	Tumour associations	Differential diagnosis	Prognosis
NMDAR	Hippocampal neurons	Psychosis, involuntary movements (dyskinesia), catatonia, mutism, paranoia, depression, reduced consciousness, seizures, cognitive impairment	Ovarian teratomas (less than 50%); occasionally other tumours in patients over 45 years	Viral encephalitis, autoimmune encephalitis associated with Hashimoto's thyroiditis, Wernicke–Korsakoff syndrome, Creutzfeldt–Jakob disease, non-convulsive status epilepticus, metabolic or drug-related	Early tumour removal and immunosuppression associated with good prognosis Non-paraneoplastic cases are thought to be chronic and relapsing
LG11 (VGKC-complex)	Hippocampal neurons	Amnesia, seizures (mainly faciobrachial), encephalopathy, hyponatraemia	Rare	As above	Usually monophasic even without long-term immunosuppression
CASPR2 (VGKC-complex)	Hippocampal neurons	Encephalopathy, autonomic disturbance, insomnia, pain, amnesia (Morvan's syndrome)	Thymoma, small cell lung cancer	Motor neuron disease, fatal familial insomnia (prion disease), heavy metal poisoning, pheochromocytoma	In the absence of tumours, good response to immunotherapy and also spontaneous improvement in some patients
AMPA	Widespread in CNS	Amnesia, psychosis, seizures	Thymoma, breast or lung (50%)	Similar to NMDA receptor limbic encephalitis	Respond to immunosuppression, but relapses common
GABA-BR	Widespread in CNS	Mainly seizures with other limbic encephalitis features	Thymoma and lung (80%)	Similar to NMDA receptor limbic encephalitis	Tumour treatment essential, some patients respond to immunosuppression
GAD	Inhibitory interneurons	Complex partial seizures, cognitive impairment	Rare	Temporal lobe epilepsy, also broader limbic encephalitis syndromes as above	Chronic; role of long-term immunosuppression not known
GlyR	Inhibitory interneurons (mainly in spinal cord and brainstem)	Stiffness, exaggerated startle reflexes, rigidity, rarely cognitive impairment	Rare	Stiff-person syndrome, hereditary glycine receptor mutations, tetanus	Good response to early immunotherapy

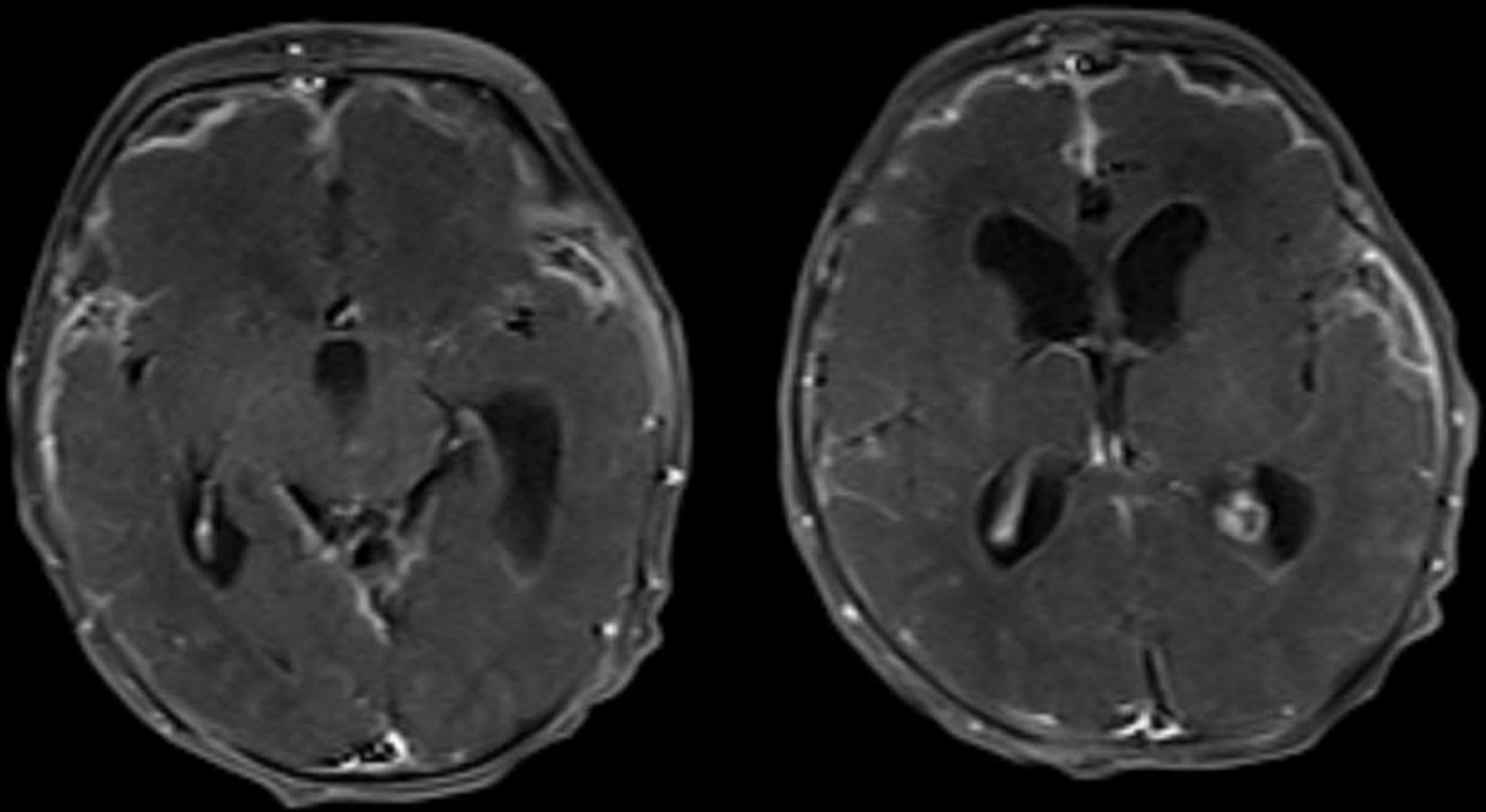
Advances in psychiatric treatment (2014), vol. 20, 337–350. doi: 10.1193/apr/ap.113.011284

ARTICLE

Autoimmune encephalitis: a potentially treatable cause of mental disorder

Hugh Rickards, Saiju Jacob, Belinda Lennox & Tim Nicholson

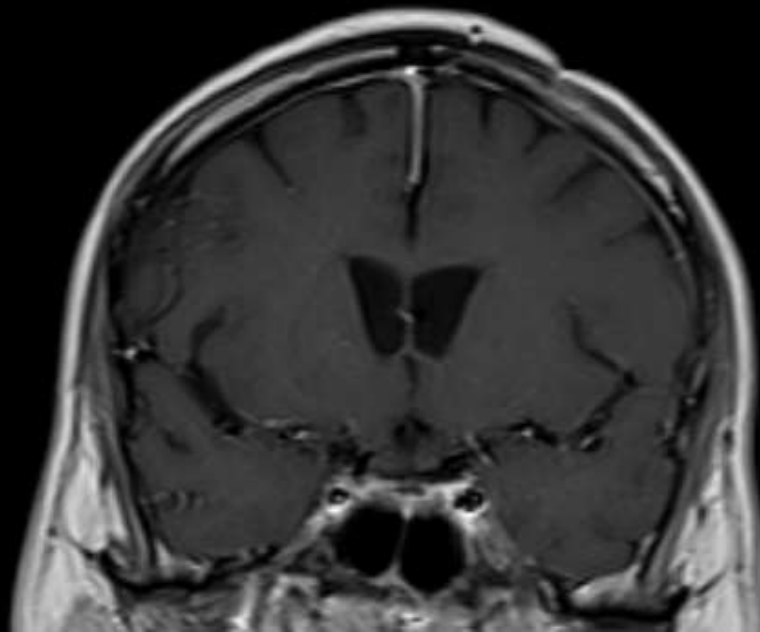
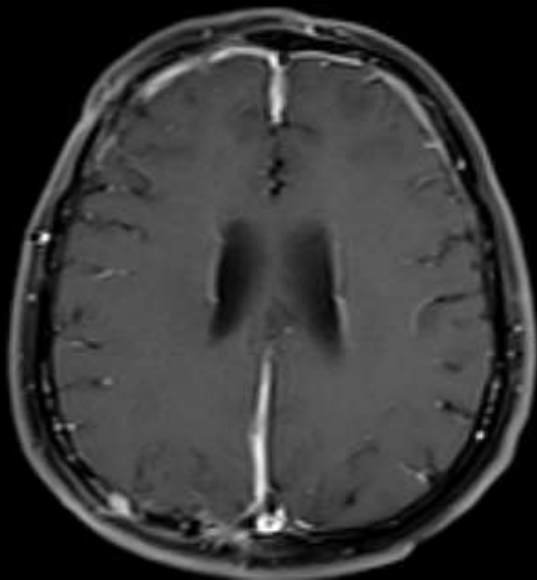
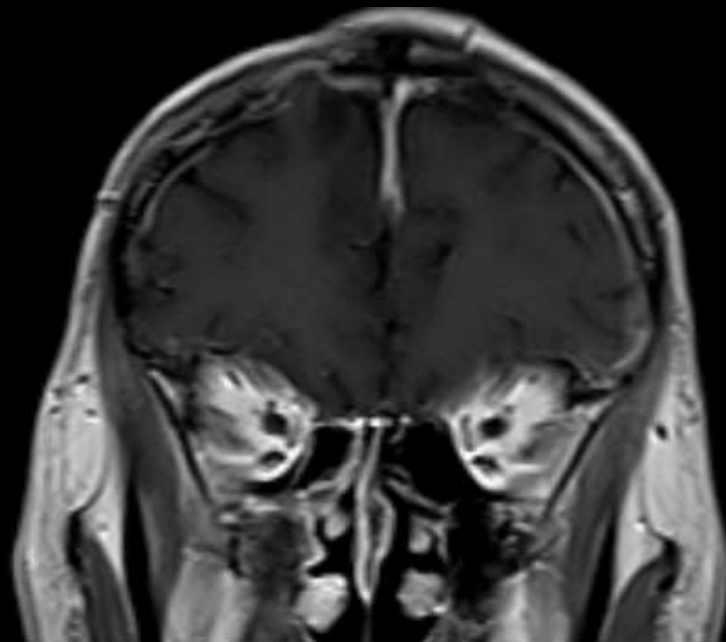
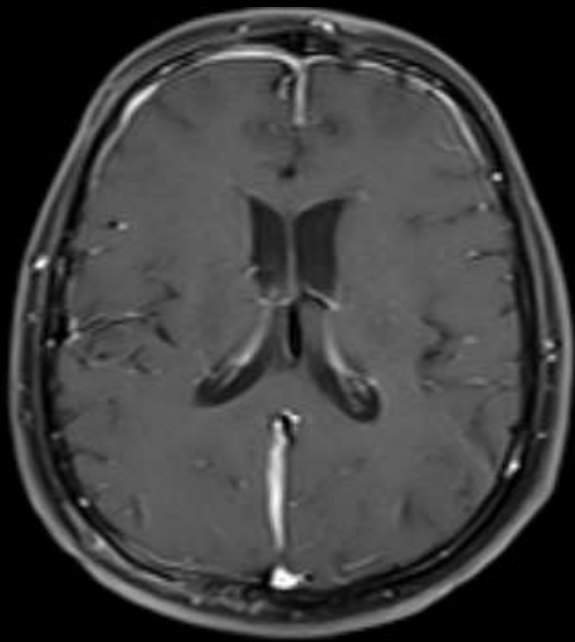
Leptomeningeal enhancement



Leptomeningeal enhanceman

- Enfeksiyöz süreçler
- Malign infiltrasyonlar (Diffüz leptomeningeal glionöronal tümör; leptomeningeal karsinomatosis; lenfoma)
- Vaskülitik/inflamatuvar
- Sturge-Weber
- Post operatif / post travmatik

Dural enhancement



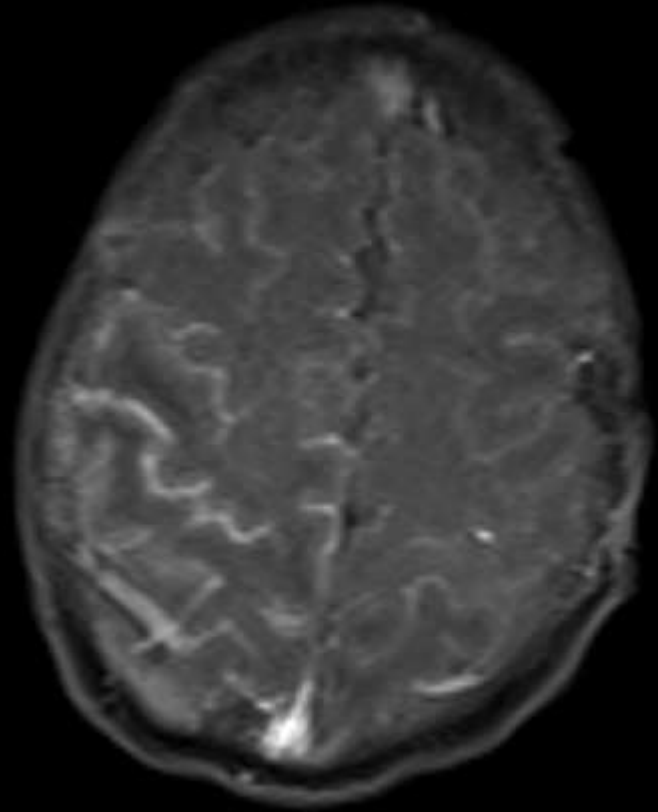
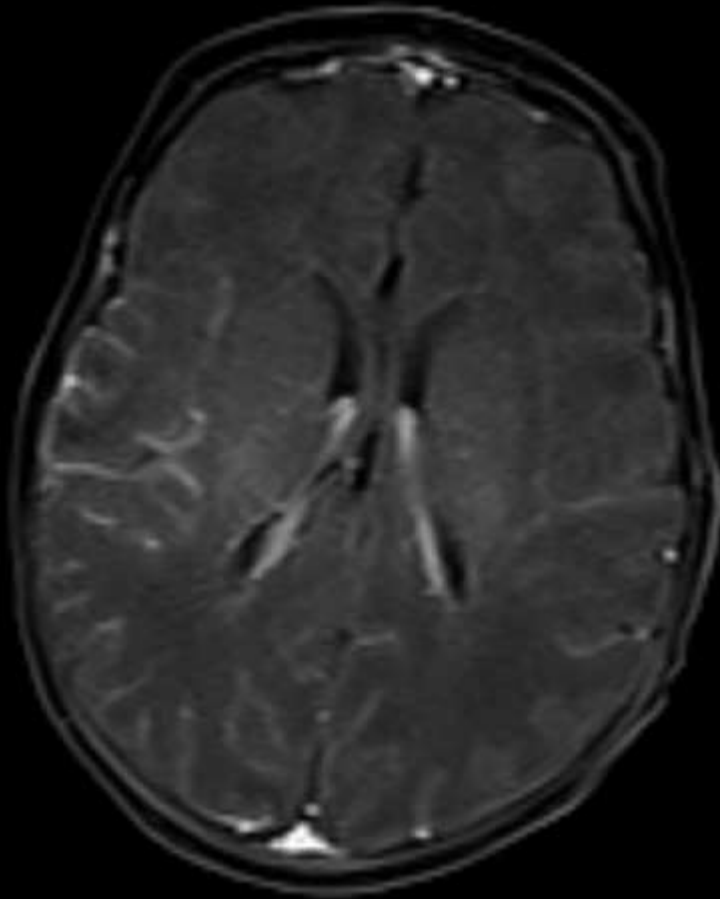
Dural (pakimeningeal) enhansman

- Enfeksiyöz süreçler
- Malign infiltrasyonlar (Pakimeningeal karsinomatosis; dural metastaz)
- Venöz tromboz
- SIH
- İdiopatik pakimeningeal
- Wegener granülomatosisi
- RA
- Post operatif / post travmatik

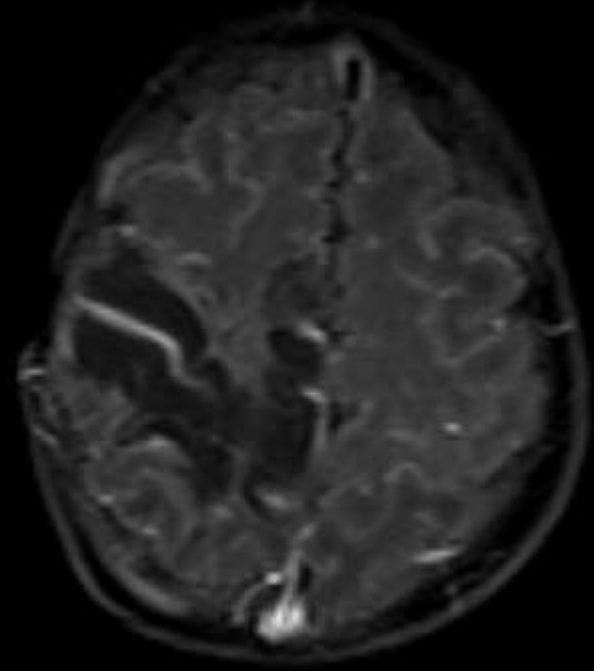
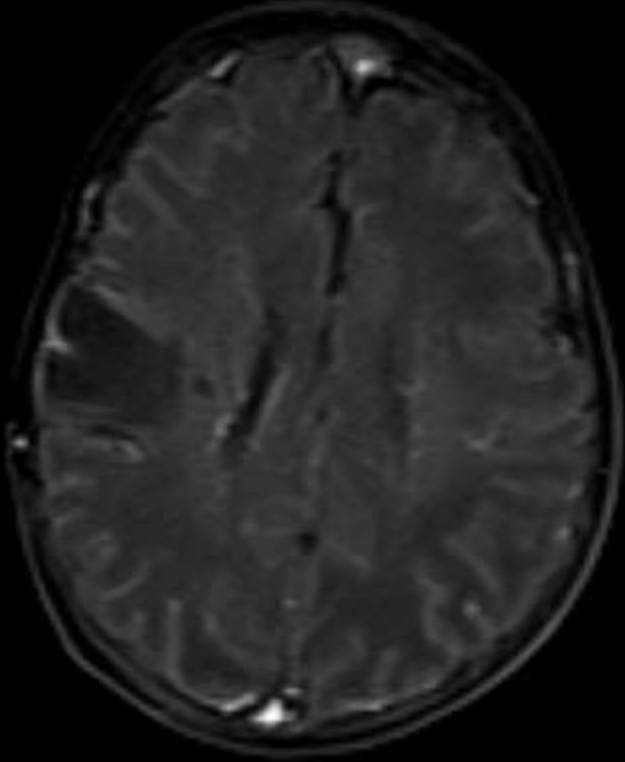
Akut bakteriyel menenjitler

- Komplikasyonlar ??
 - Hidrosefali
 - Ampiyem
 - Serebrit / Apse formasyonu
 - Vasküler tutulum → İskemi & enfarkt
 - Sekel değişiklikler

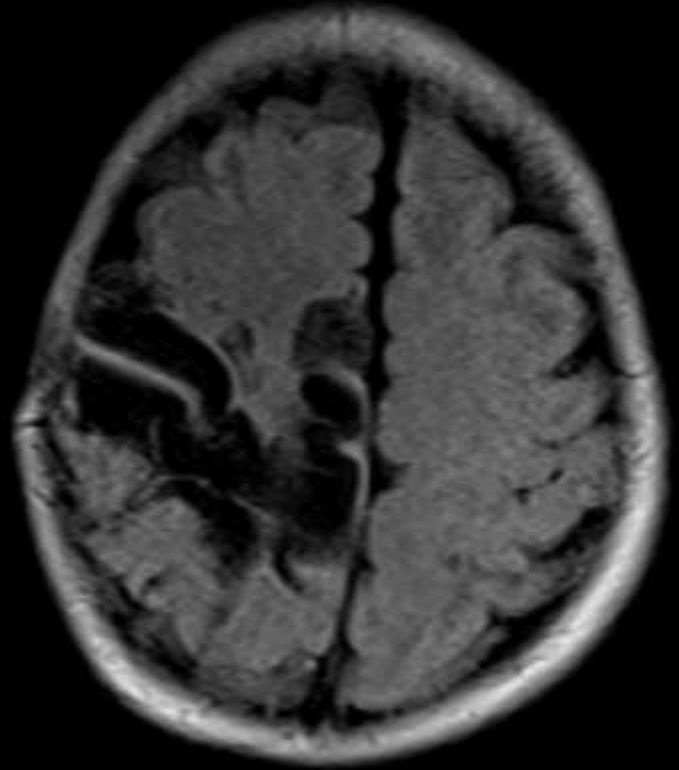
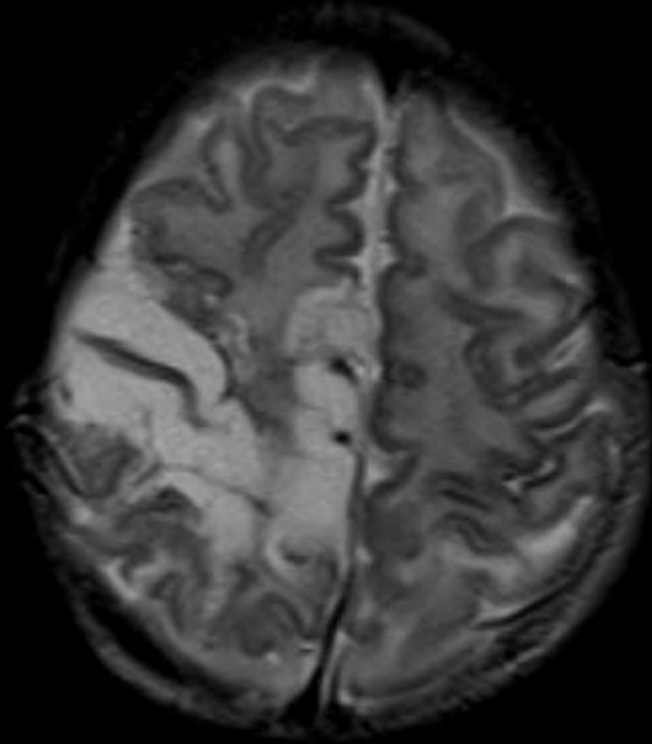
26 gün, Erkek



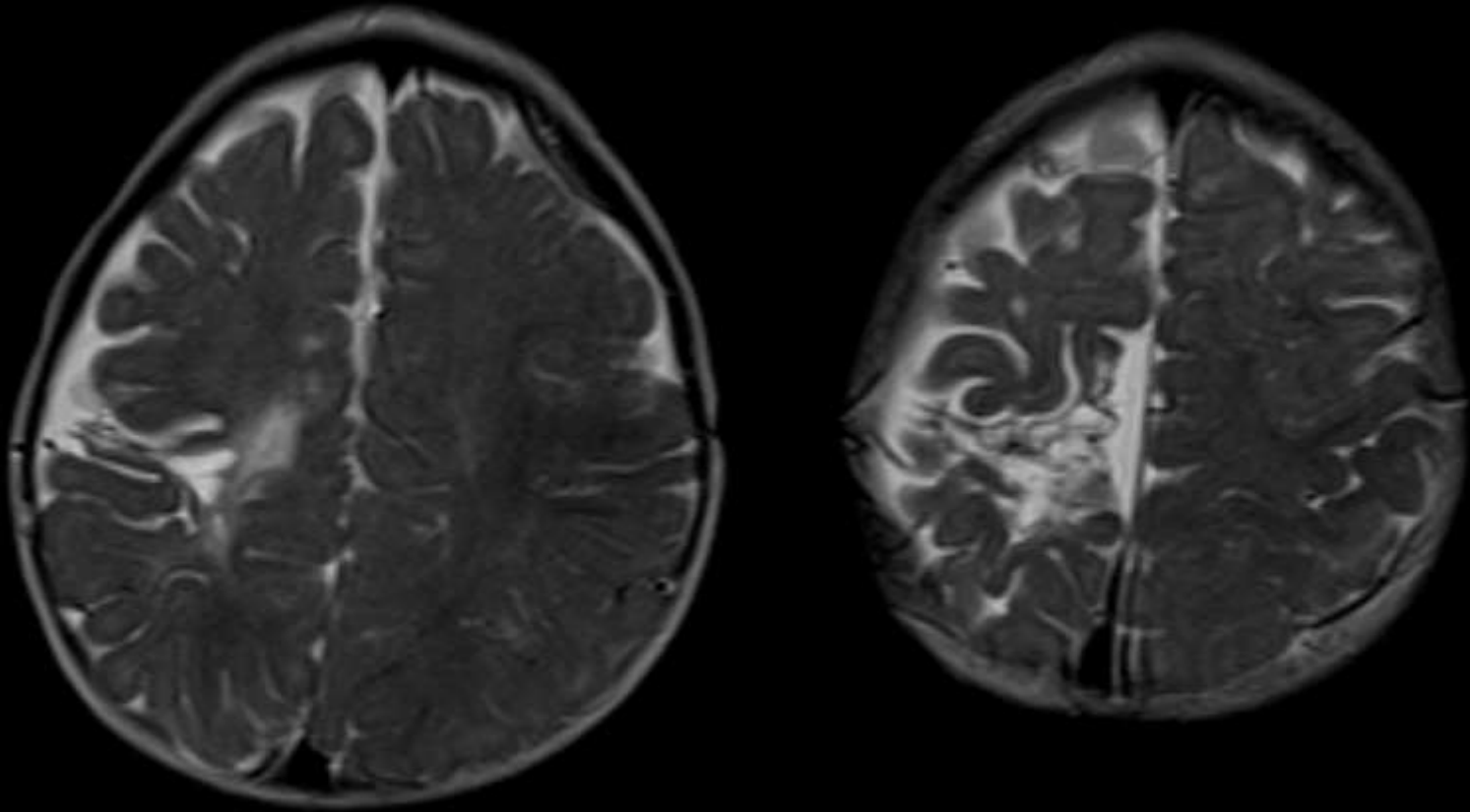
9 gün sonraki takip MRG



9 gn sonraki takip MRG



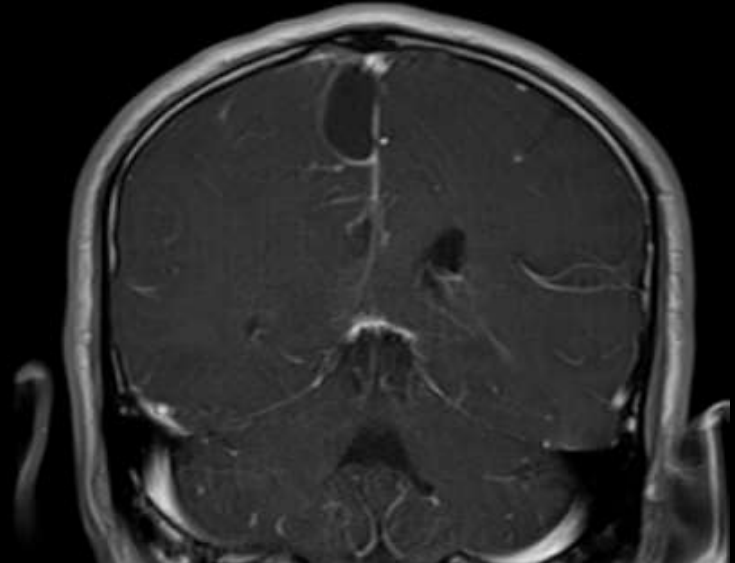
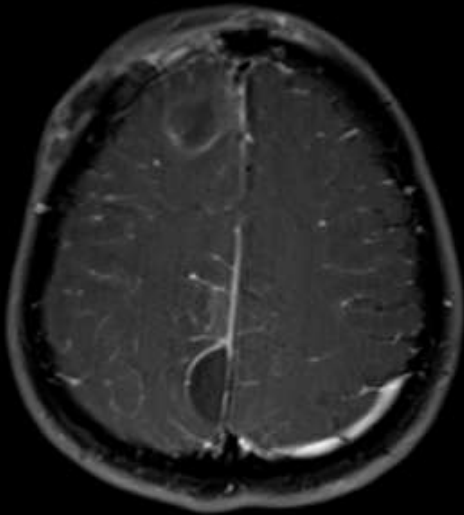
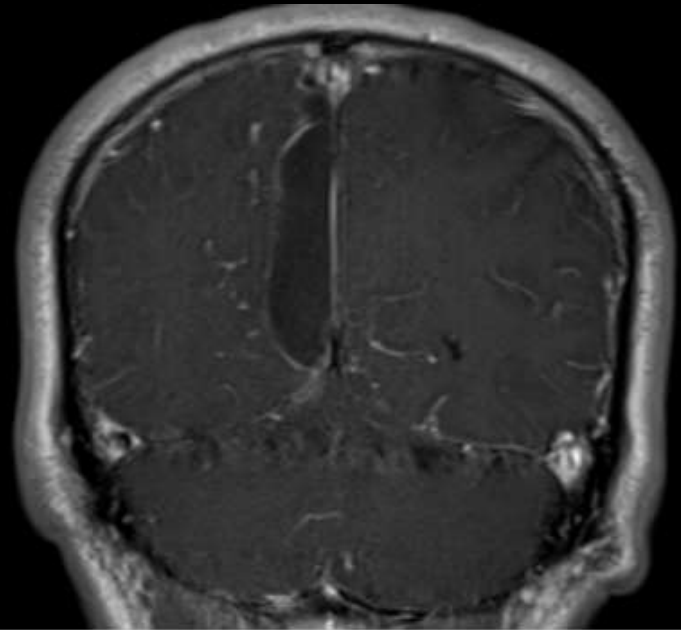
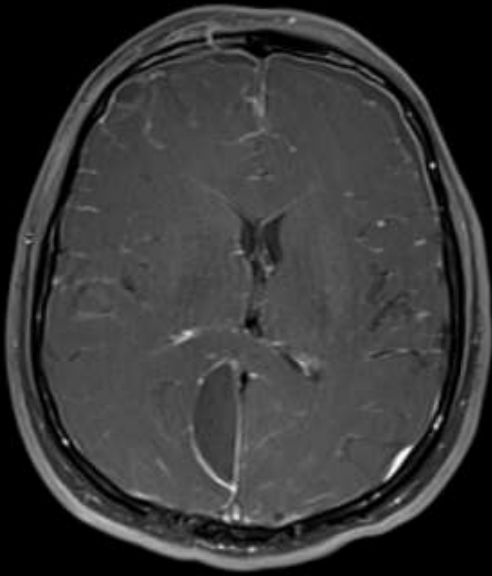
Bir yıl sonraki takip MRG

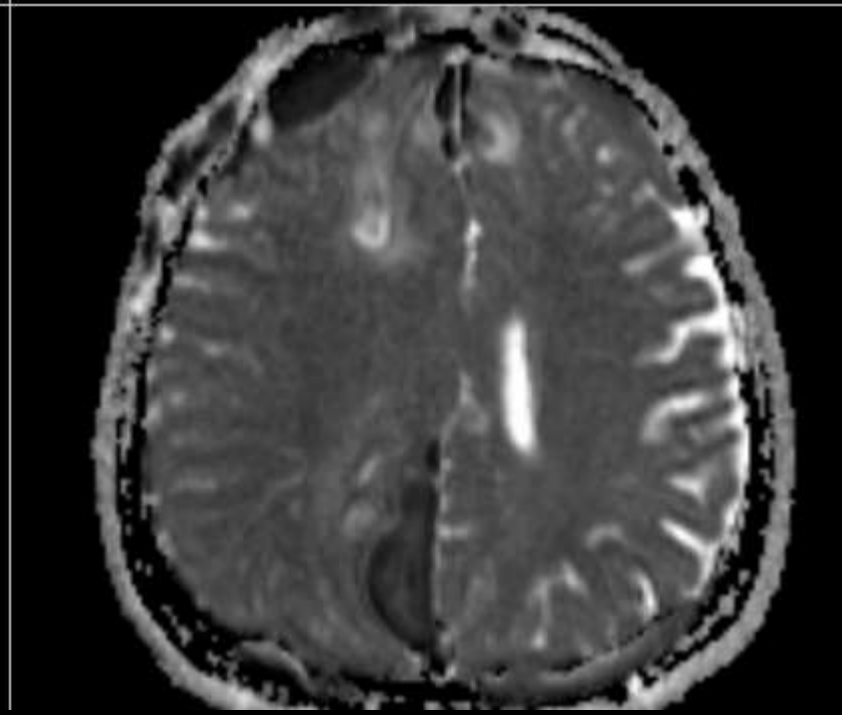
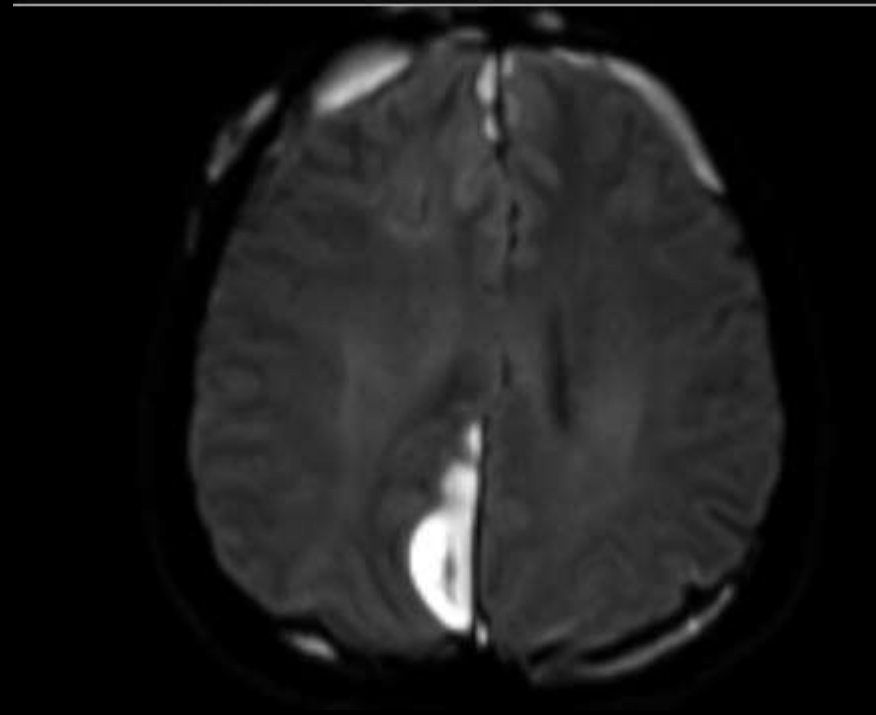
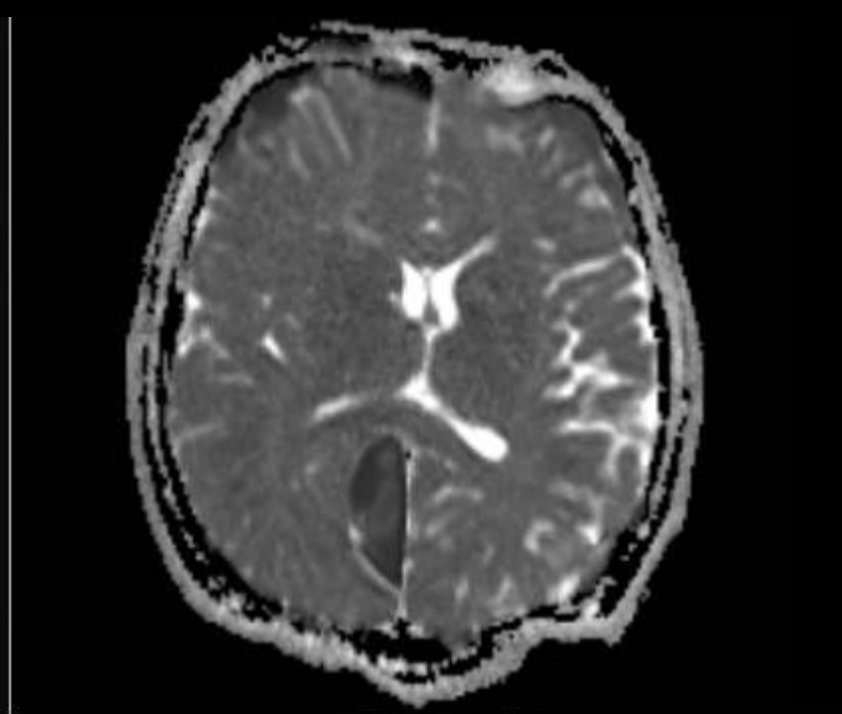
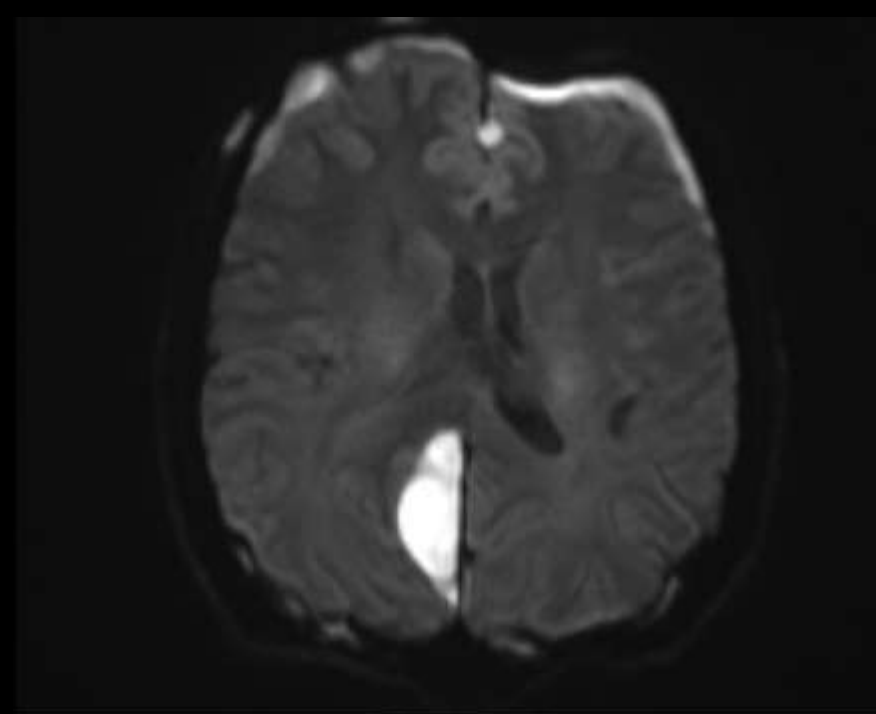


Ampiyem

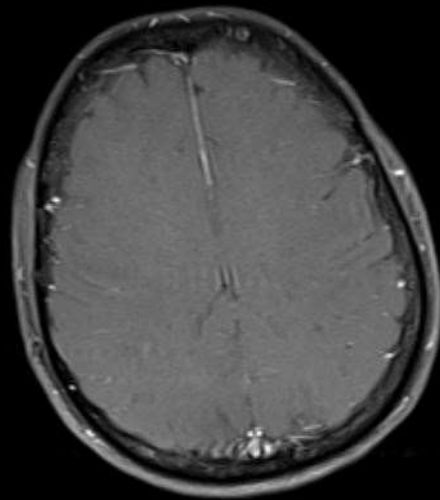
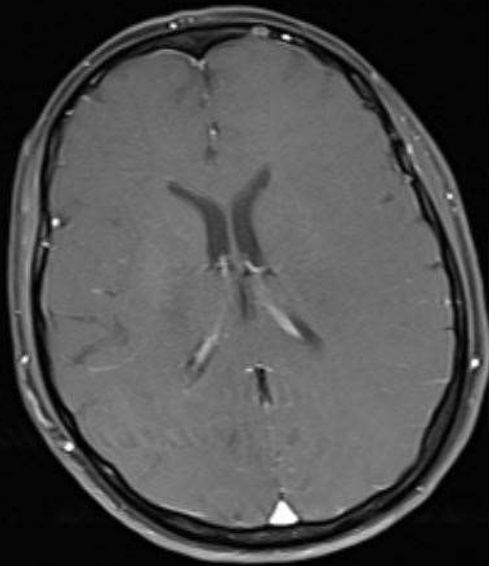
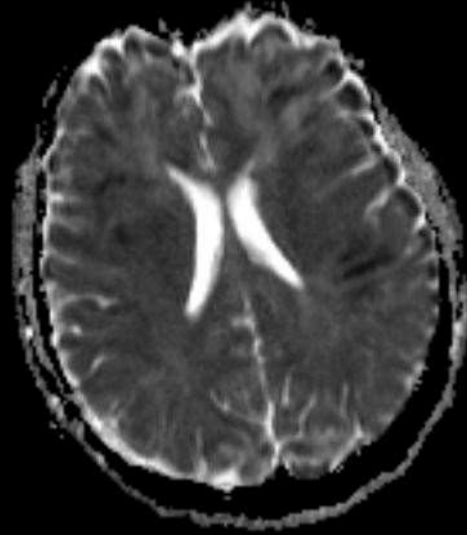
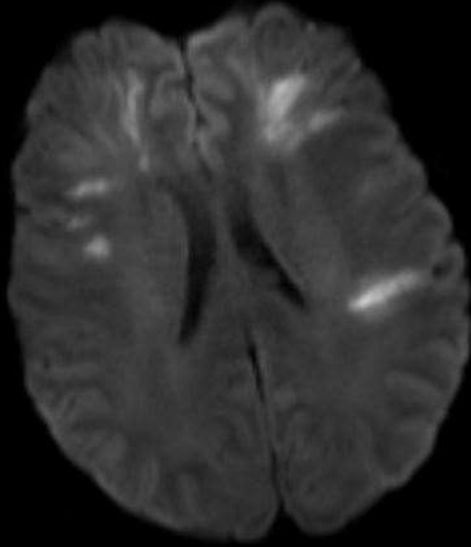
- Subdural ya da epidural mesafede olabilir
- Subdural çok daha sık
 - Sinüzit
 - Mastoid hücrelerde enfeksiyon
- Epidural
 - Benzer nedenler
 - Post operatif

44 y, Erkek

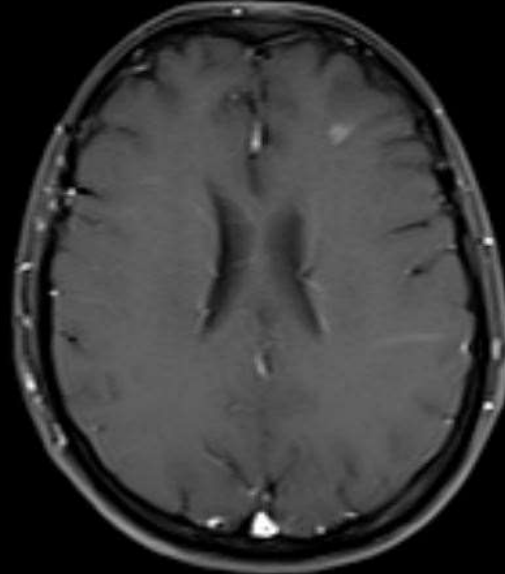
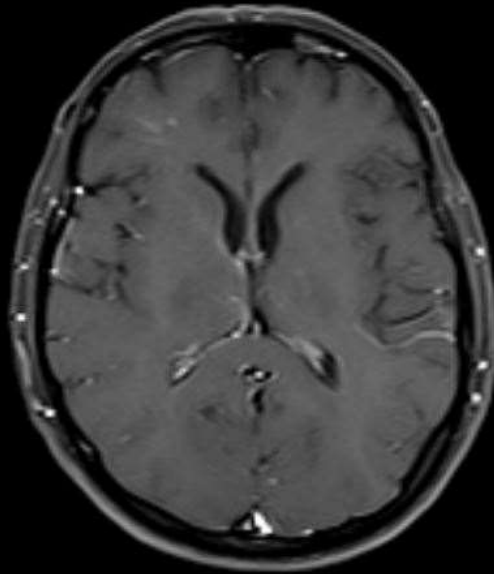
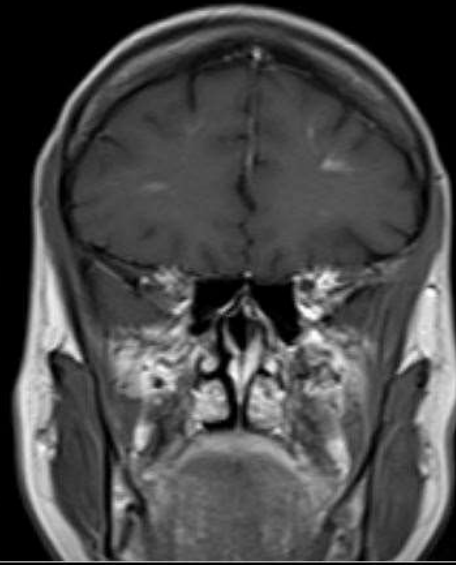
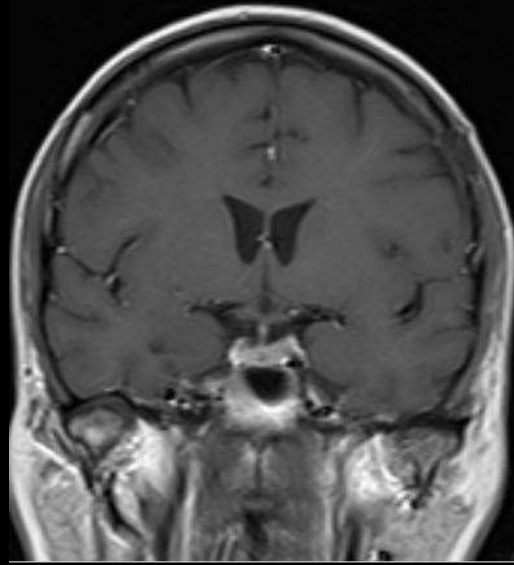




37 y, K, septik tablododa



Üç hafta sonraki MRG



Serebrit ve Apseler

- Büyük kısmı bakteriyel
- Sinüsler, mastoid hücreler, diş köklerinden direkt yayılım
- Hematojen yayılım (endokardit, pnömoni, karın içi enfeksiyonlar ...)
- Travma & cerrahi sonrası

