Vasküler Greft İnfeksiyonlarının Tanı ve Tedavisinde Yeni Ne Var?

Doç. Dr. Ümit KERVAN
Sağlık Bilimleri Üniversitesi,
Ankara Şehir Hastanesi,
Kalp Damar Cerrahisi Kliniği

Ekonomik Yük

Table 1. Clinical and Economic Consequences of Infections Associated with Surgical Implants.*

Implant	Implants Inserted in the U.S. Annually	Projected Infections of Implants Annually	Average Rate of Infection†	Preferred Practice of Surgical Replacement	Estimated Average Cost of Combined Medical and Surgical Treatment
	no.		*%*	*no. of stages*	*U.S. $*
Cardiovascular					
Mechanical heart valve	85,000	3,400	4	1	50,000
Vascular graft‡	450,000	16,000	4	1 or 2	40,000
Pacemaker–defibrillator	300,000	12,000	4	2	35,000§
Ventricular assist device	700	280	40	1	50,000
Orthopedic					
Joint prosthesis	600,000	12,000	2	2	30,000
Fracture-fixation device¶	2,000,000	100,000	5	1 or 2	15,000
Neurosurgical — ventricular shunt	40,000	2,400	6	2	50,000
Plastic — mammary implant (pair)	130,000	2,600	2	2	20,000
Urologic — inflatable penile implant	15,000	450	3	2	35,000

Darouiche et al. N Engl J Med 2004; 350:1422-9

Swiss federal office of Statistics, 2013

Mortalite - Morbidite

Femoropopliteal grafts: 4%

Aortic grafts: 0.5-2%

Darouiche et al. N Engl J Med 2004; 350:1422-9

Legout et al Clin Microbiol Infect 2012:18:352:18: 352-8

Hasse et al. Swiss Medical Weekly 2013

TANIM: Vaküler bir konduitin, yamanın veya endovasküler protezin tamamının veya bir kısmını içeren sepsis



Sentetik Materyal

– PET	Polyethylenterephthalate	Dacron
– PTFE	Polytetrafluoroethylen	Gore-Tex

Biyolojik Materyal

– Animal	Heterologous	Xenografts
– Cryopreserved cadaveric arteries	Homologous	Homograft
– Produced naturally in the body	Autologous	Autograft

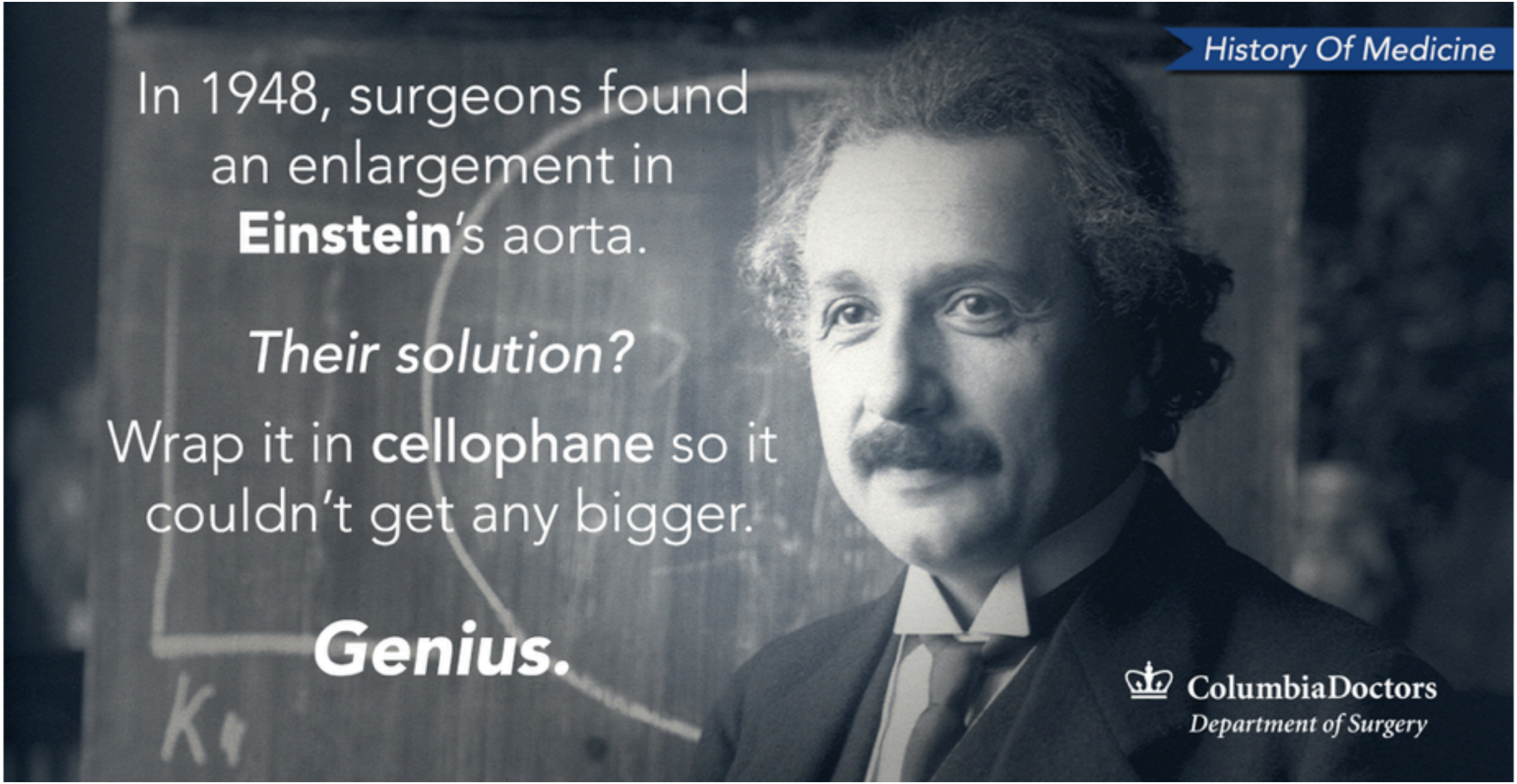
History Of Medicine
In 1948, surgeons found an enlargement in **Einstein**'s aorta.
Their solution?
Wrap it in **cellophane** so it couldn't get any bigger.
Genius.
ColumbiaDoctors
Department of Surgery

Bölgeye Göre İnsidans

Infection	Incidence (%)
Graft Implant Site	
Descending thoracic aorta/thoracoabdominal	0.5-1.9
Aortoiliac	0.2-1.3
Aortofemoral	0.5-3
Femorofemoral	1.3-3.6
Axillofemoral	5-8
Femoropopliteal	0.9-4.6
Femorotibial	2-3.4
Carotid patch	0.25-0.5
Carotid-subclavian	0.5-1.2
Axilloaxillary	1-4
Endovascular Device	
Aortic stent-graft	0.1-1.2
Peripheral stent	<0.1

- **5%**
- Erken (<30-gün) greft enf.→ **1%**
  - Acil girişimler

    rüptüre AAA, akut arteriyal iskemi
  - Femoral bölgede greft
  - Subkutaneous tünnel

    axillofemoral or cross-femoral bypass

Sınıflandırma

Zamana Göre Sınıflama:

Erken : < 4 ay

Geç : > 4 ay

Postoperatif Yara Enfeksiyonuna Göre (SZILAGYI'S CLASSIFICATION)

Grade I : Cilt enfeksiyonu

Grade II : Subkutan doku enfeksiyonu

Grade III: Vasküler protezi de içine alan enfeksiyon

Greftdeki Uzanım,Tutulum Miktarı (BUNT'S CLASSIFICATION)

1. Periferik Greft Enfeksiyonu

P0 graft infection	Involving cavitary grafts	e.g. aorto-femoral bypass
P1 graft infection	Involving extra-cavitary grafts	e.g. femoro-popliteal bypass
P2 graft infection	Involving extra-cavitary part of a cavitary graft	e.g. infected groin segment of an aorto-femoral bypass
P3 graft infection	Involving a prosthetic patch	e.g. carotid patch

2. Greft – enterik erozyon (GEE)

3. Greft – enterik fistül (GEF)

4. Entefte aortik greft çıkartıldıktan aortik güdük sepsisi

Samson Sınıflaması

- **Grade 1:** Yüzeyel cilt ve/veya ciltaltı dokularda enfeksiyon
- **Grade 2:** Fasya ve kasları da içeren derin doku tutulumu ve apse varlığı
- **Grade 3:** İnfeksiyon var ama çevre dokulara yayılım yok
- **Grade 4:** İnfeksyion ile birlikte çevre dokulara yayılım var ama anastomoz yok
- **Grade 5:** İnfeksiyon ile birlikte anastomoz varlığı

PATOGENESİS

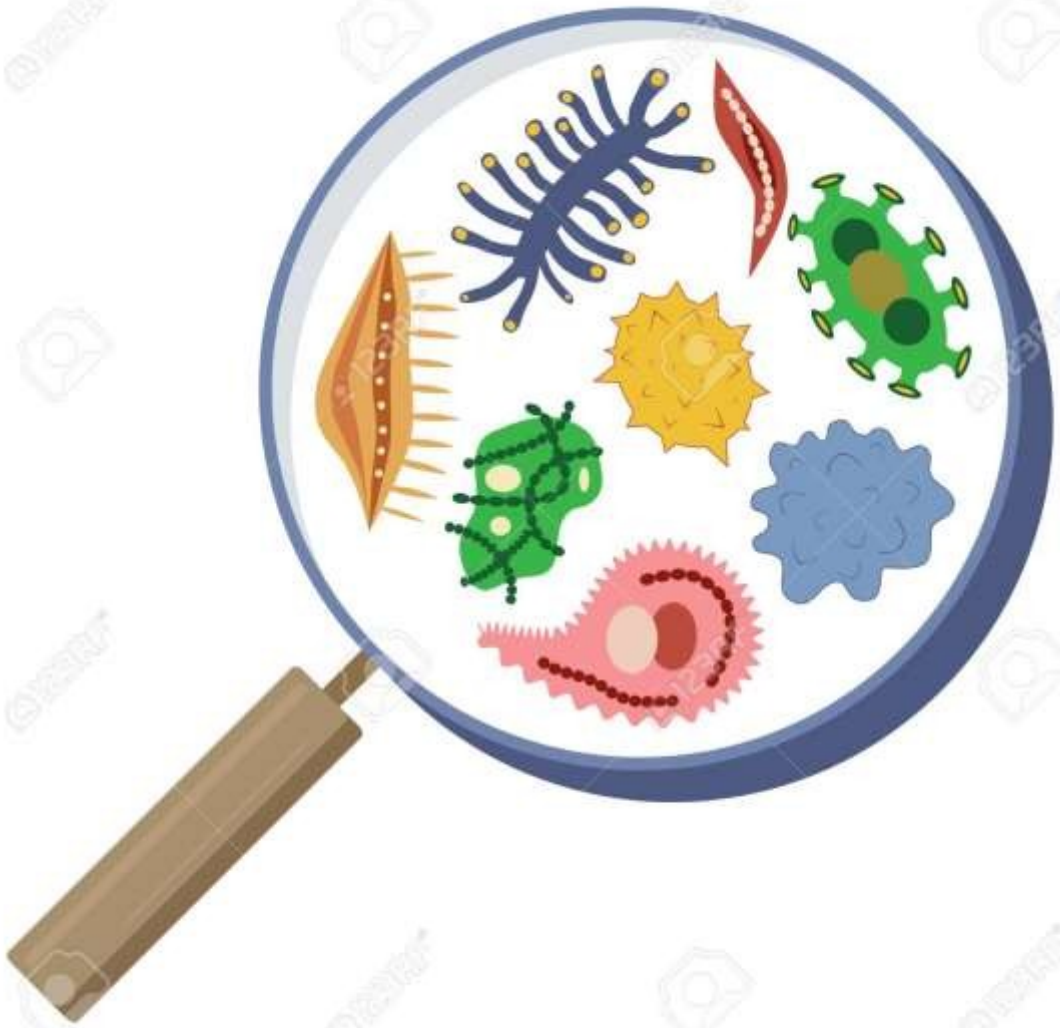

Enfeksiyonun Klinik Kaynakları

- Perioperatif kirlenme
- Biyomateryalin bakteriyemi ile teması
- Bağırsak / genitoüriner / cilt içine mekanik erozyon
- savunmasını bozma

Mekanik Erozyon

- GEE / GEF, aort greftin bağırsaklara karşı pulsatil hareketinin, yeterli retroperitoneal yumuşak doku ile doldurulmadığı sonucu gelişir.
- İnsidans GEE/GEF aortik greft :

  0.4-2%

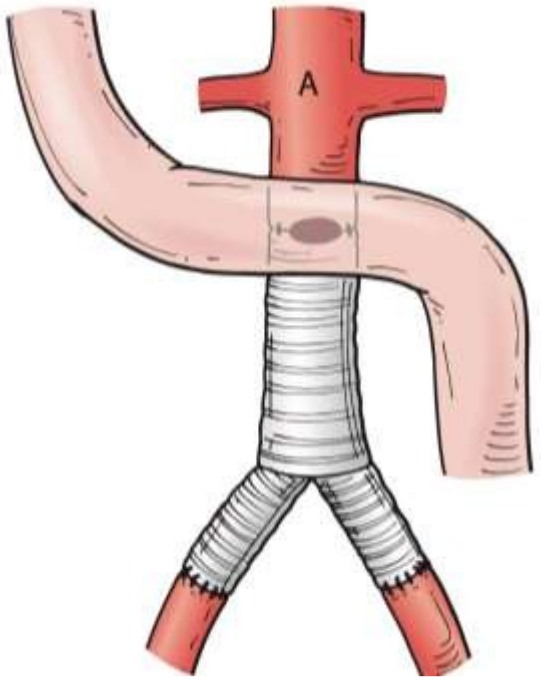

GEF : Graft enteric fistula

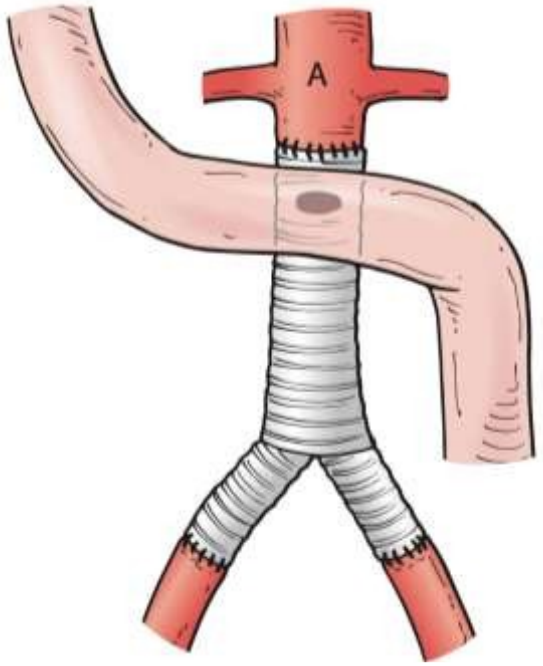

GEE : Graft enteric erosion

Bakteriyoloji

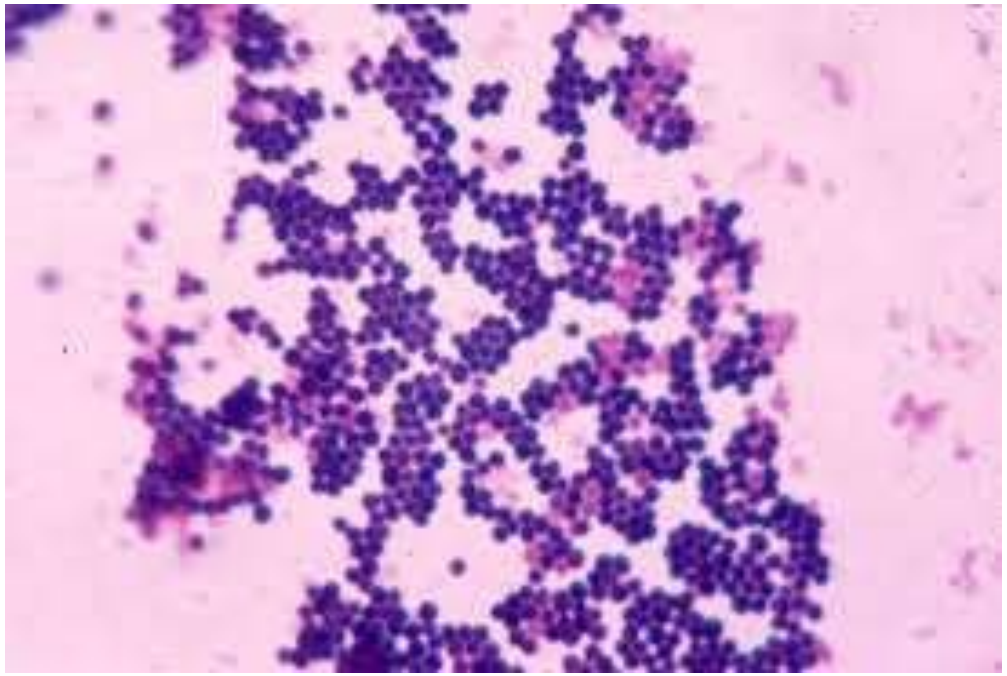

Staphylococcus aureus %20-50

Coagulase negative Staphylococci %15

Enterobacteriaceae %14-41

Anaerobes %5

Fungi %1-2

Polymicrobial Enfeksiyonlar 20%

FitzGerald et al. Journal of Antimicrobial Chemotherapy (2005) 56, 996–999

Microbiology of PPM/ICD Infections (n=189)

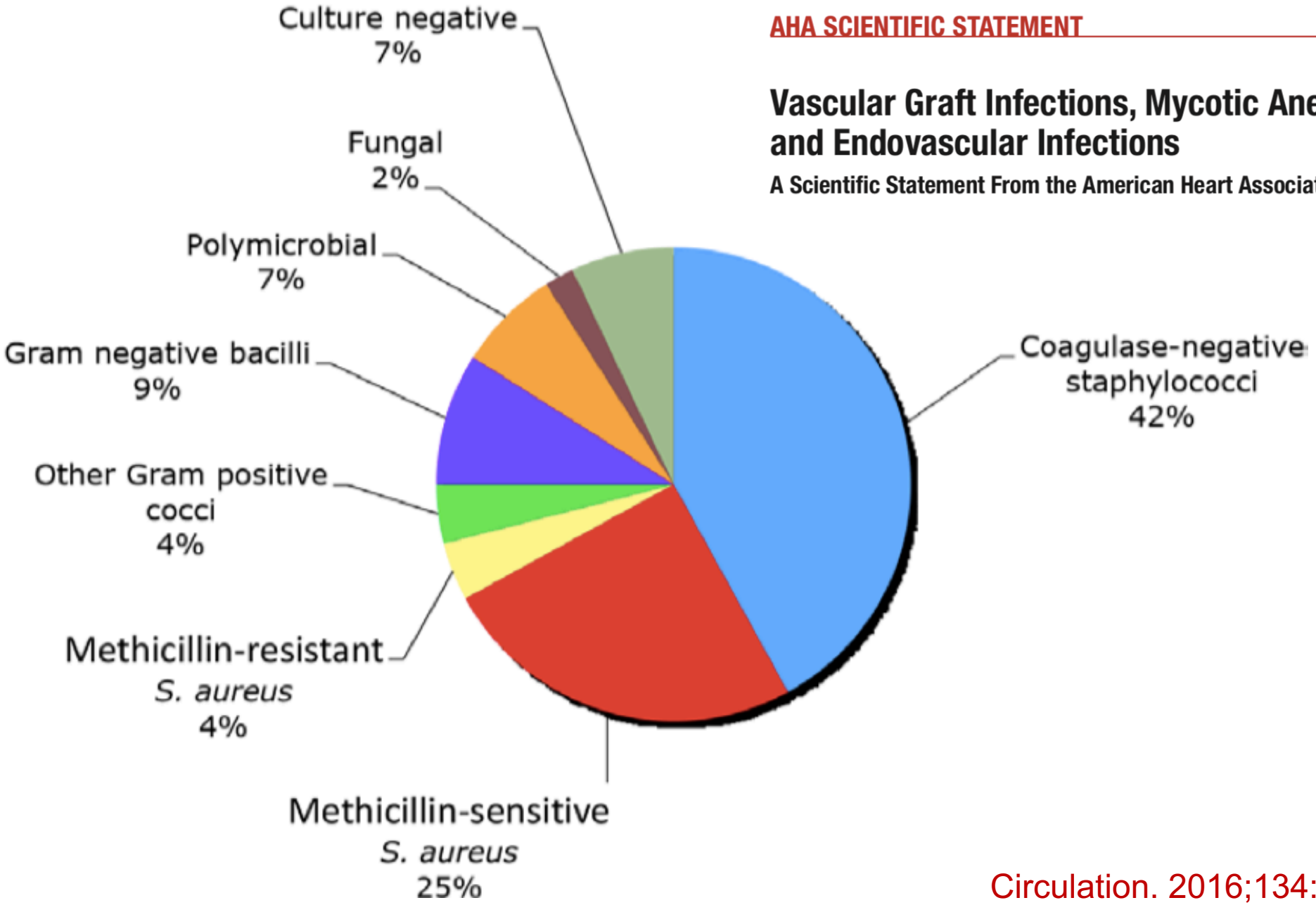

AHA SCIENTIFIC STATEMENT

Vascular Graft Infections, Mycotic Aneurysms, and Endovascular Infections

A Scientific Statement From the American Heart Association

Circulation. 2016;134:e412-e460

Korunma Yöntemleri

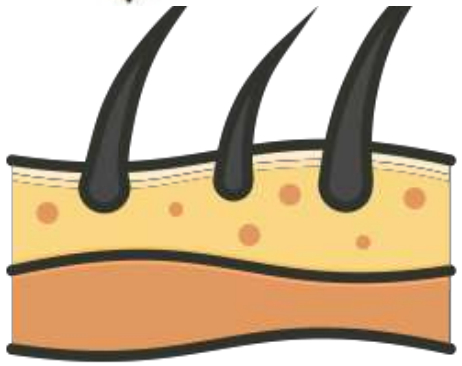

- Uzun hastane yatışından kaçınmak
- Banyo, antibakteriyal sabun ile yıkanma
- Tıraş, temizlik
- Vasküler greftlerin cilt ile temasının engelenmesi (iodine-impregnated plastic drapes)

- Batın kontaminasyonundan kaçınmak
- 30-60 dk önce profilaktik antibiyotik
- MRSA Kontrol: disposable önlük, eldiven, maske

Tanı

Erken Enfeksiyonlar

- 4 ay içinde
- Ateş, bakteremi, ağrı eritem
- şişlik, ısı artışı
- Lokal Kanamalar
- Ülser Oluşumu
- Pulsatil Kitleler

Geç enfeksiyonlar

- 4 ay sonra
- Semptomlar siliktir
- Sırt, karın ağrısı fistül oluşumu,
- greft oklüzyonu,
- Asemptomatik pseudöanevrizma oluşumu
- Sistemik bulgular genellikle yoktur
- Kan kültürü genellikle negatiftir

Diagnostic Appraisal

Clinical presentation



White cell count
ESR
C-reactive protein
Procalcitonin
Blood cultures
Pus swab
Aspirates for culture



Duplex Ultrasound

MDCT Angiogram
MRI

Catheter angiography

Upper endoscopy

- Gallium 69 citrate scan
- Indium 111-labelled leukocyte scan
- Technetium 99m hexametazime–labelled leukocyte scan
- 18F-FDG PET scan

PET –CT scan

Recommendations for Imaging in Diagnosis of extracavitary VGI

1. It is reasonable to consider **ultrasonography** as the initial imaging procedure of choice *(Class IIa; Level of Evidence B)*.

2. It is reasonable to consider **CTA or MRI** when **extracavitary graft** infection is suspected and there are indeterminate findings on ultrasonography *(Class IIa; Level of Evidence B)*.

3. **A PET/CT** or **indium-labeled white blood cell** study scan <u>may be considered when extracavitary graft infection</u> is suspected and ultrasonography, CTA, or MRI findings are indeterminate *(Class IIb; Level of Evidence B)*.

Modality	Advantages	Disadvantages
Ultrasound	Most useful for extracavitary Can be performed at bedside Inexpensive No contrast kidney injury Aspiration for analysis, culture Detect pseudoaneurysm	Limited use for intracavitary VGI Cannot discriminate seroma, hematoma, abscess
CT	Sensitivity 85%–100%; specificity 85%–94% Rapid result Less expensive than MRI, PET/CT Aspiration for analysis, culture CTA useful for surgical planning	Contrast kidney injury Noncontrast with renal disease less diagnostic Might not differentiate hematoma from inflammation, especially low-grade inflammation Images degraded by metallic clips, spinal hardware
Magnetic resonance	Sensitivity 68%–85%; specificity 97%–100% Use when CT nondiagnostic No contrast kidney injury Differentiate hematoma, inflammation, infection Good soft tissue resolution MRI/MRA can detect mycotic aneurysm, bleeding, enteric fistula	More expensive than CT No guided aspiration Limited use in patients with intracardiac devices Gadolinium fibrosing dermopathy in renal disease
Indium-labeled WBC scan (In-scan)	Sensitivity 67%–73%; specificity 87% No contrast kidney injury Use when CT, MRI nondiagnostic	Results take ≥24 h Decreased sensitivity with recent antimicrobial therapy False-positive result in early postoperative period Use in combination with other imaging
PET	Sensitivity 78%–96%; specificity 70%–93% No contrast kidney injury	Less experience than with other imaging Does not identify specific anatomic location Expensive Use in combination with other imaging

- Tek başına kullanılan İndiyum taramaları, VGI'yi önerecek bir bulgusu olmayan hastalarda VGI'yi tanımlamak için kullanışlı değildi.
- İndiyum taramaları postoperatif erken dönemde **yanlış pozitif** olabilir ve mevcut veya yeni antimikrobiyal tedavi alan hastalarda hassasiyeti azalttı.
- Bu çalışmalarda ve diğer çalışmalarda görüntüleme teknikleri ve hasta seçiminde değişkenler olmasına rağmen, PET / BT'nin duyarlılığı ve özgüllüğü VGI tanısı için standart BT ile bildirilenlere benzerdi
- PET / BT, VGI'ın anatomik yerini belirlemek için konvansiyonel BT'den daha az hassas olabilir.
- Bir kan damarı üzerinden doğrusal, dağınık, homojen bir tutulum VGI'ın göstergesi değildir, oysa PET / BT'deki bir kan damarı üzerinde odaklanma VGI'yi yüksek oranda gösterir.

- The administration of antimicrobial therapy before PET/CT decreased the sensitivity and specificity of the diagnosis of VGI.

- **There are currently no published studies that demonstrate a clear benefit of serial PET/CT to follow the response to antimicrobial therapy for VGI.**

Circulation. 2016;134:e412-e460

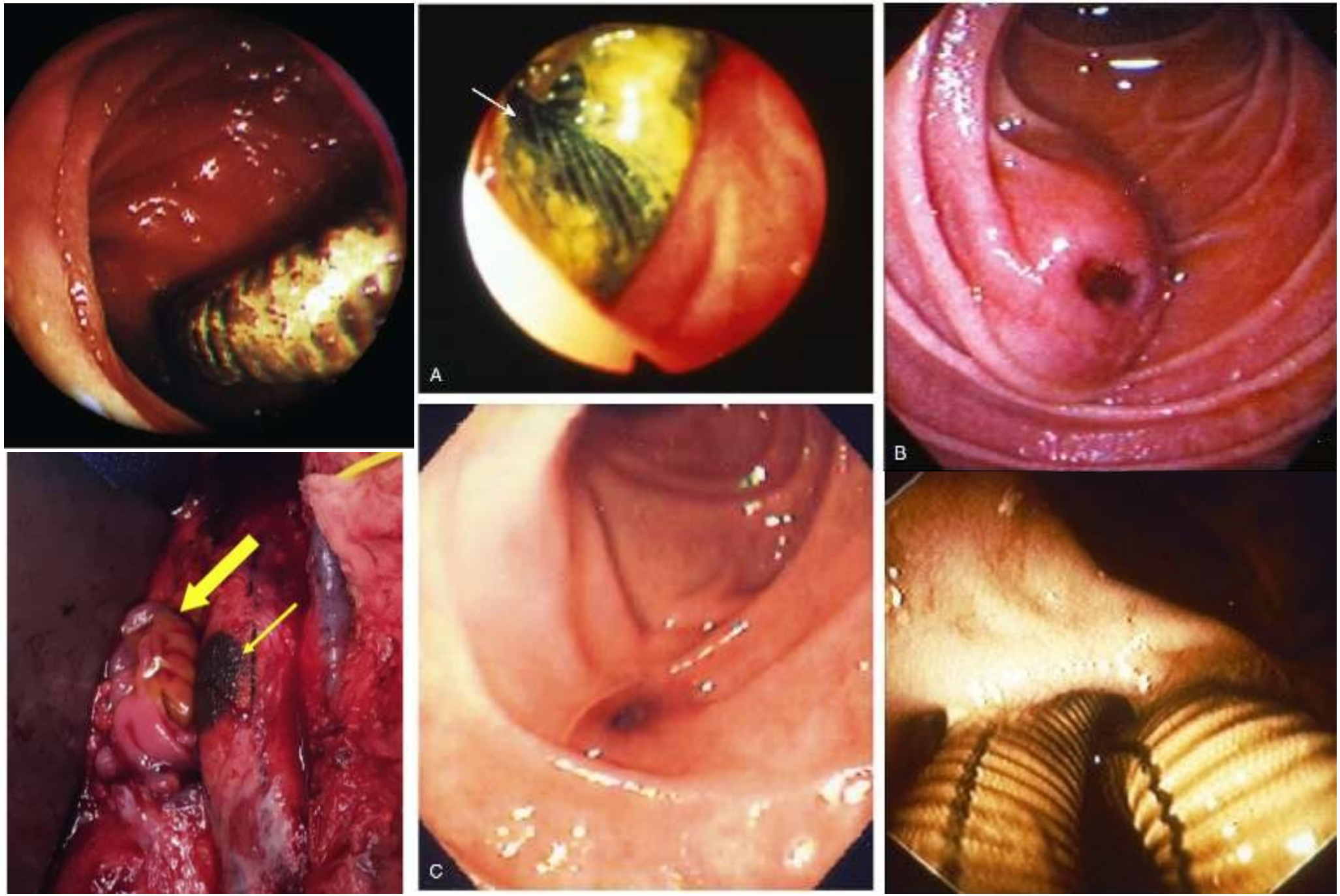
A
B
C

Cerrahi Tedavi ve Sonuçları

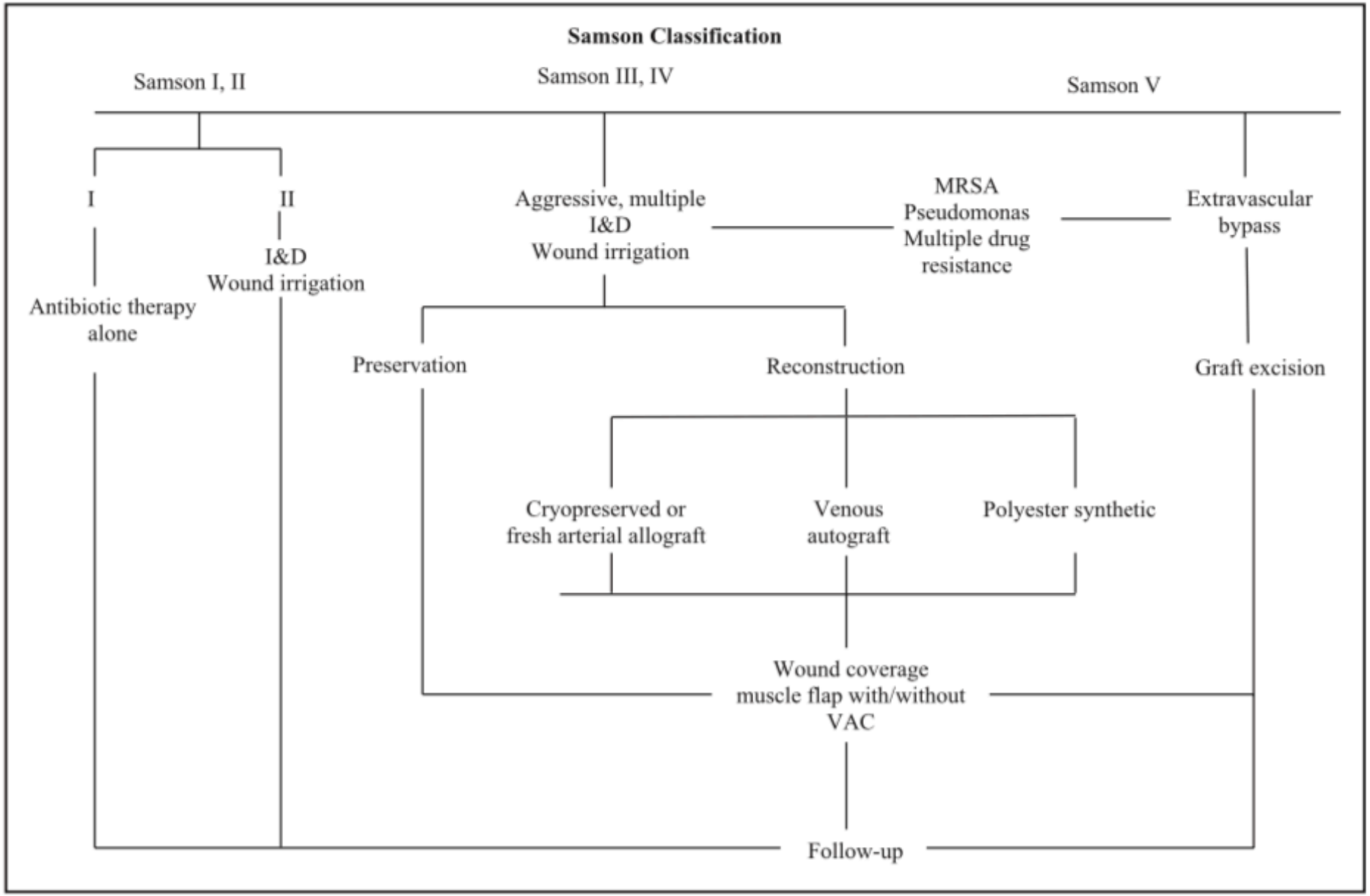

Figure 4. Extracavitary vascular graft infection: algorithm for management.
I&D indicates irrigation and débridement; MRSA, methicillin-resistant *Staphylococcus aureus* infection; and VAC, vacuum-assisted closure device.

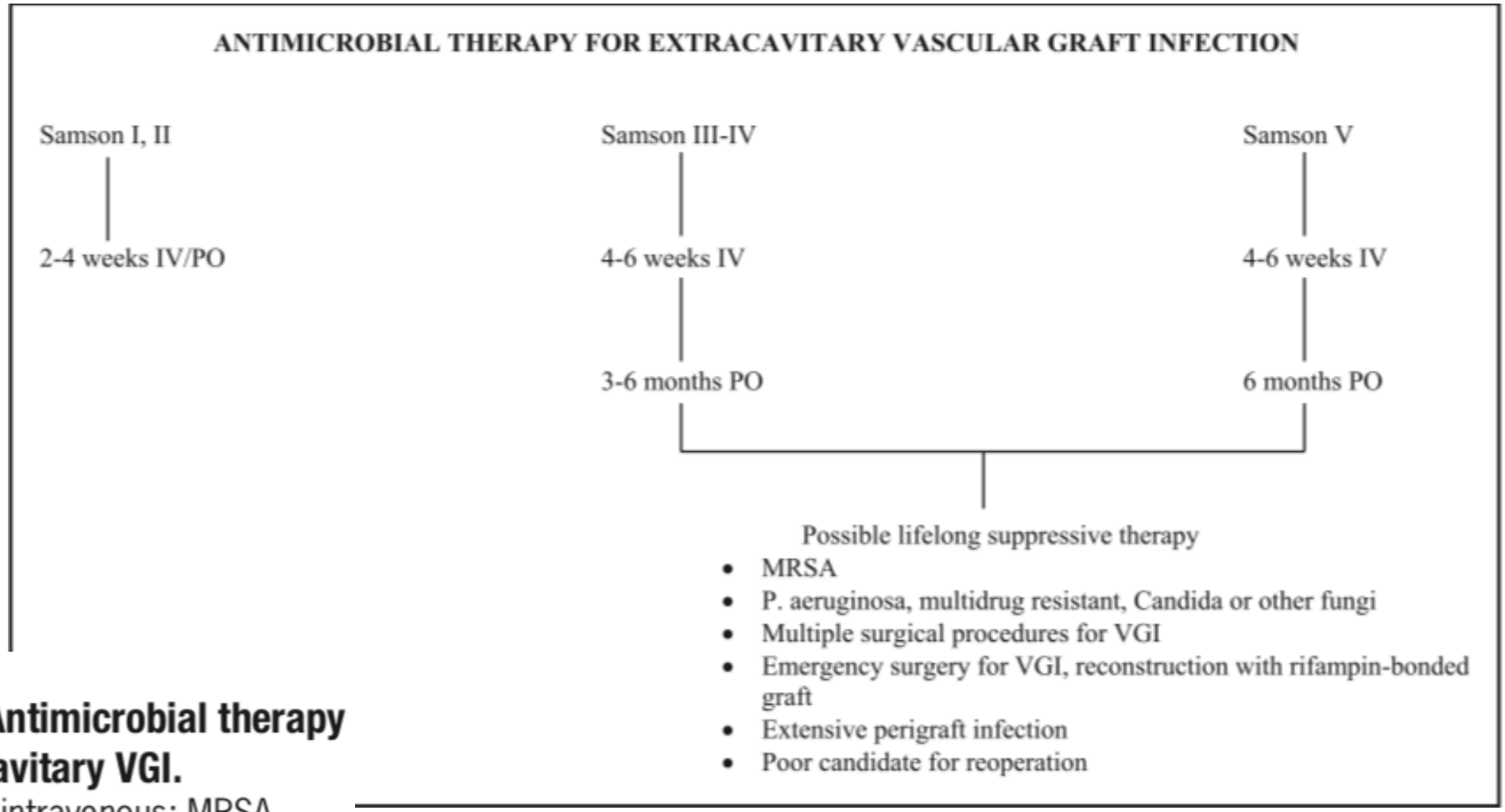

Figure 5. Antimicrobial therapy for extracavitary VGI.
IV indicates intravenous; MRSA, methicillin-resistant *Staphylococcus aureus;* PO, oral; and VGI, vascular graft infection.

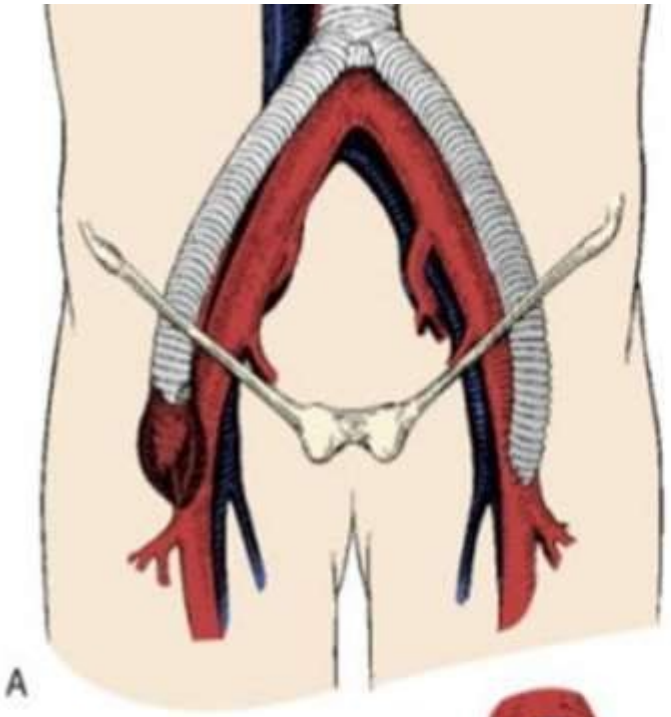
A

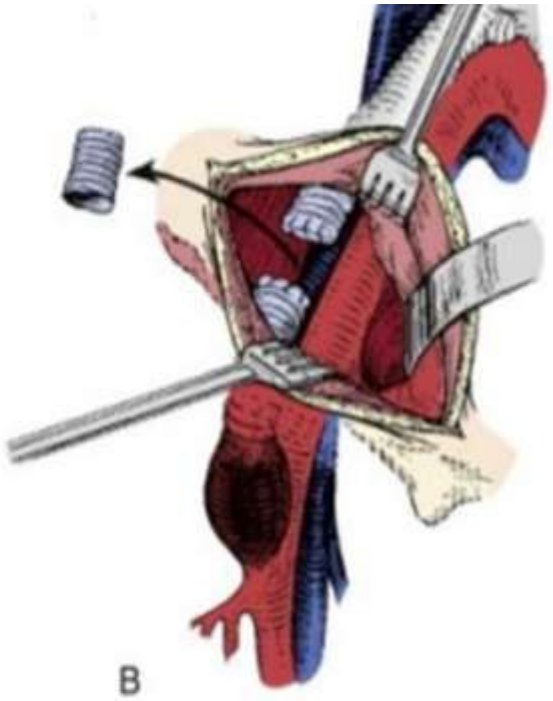
B

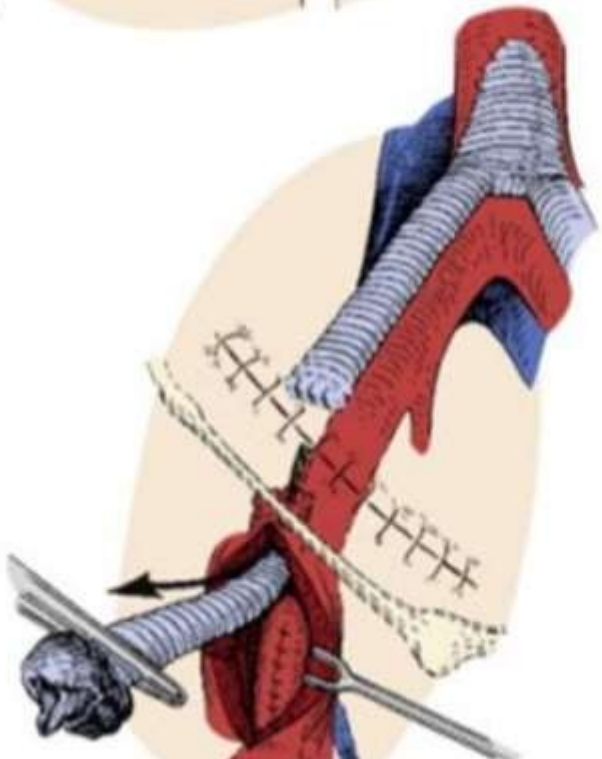

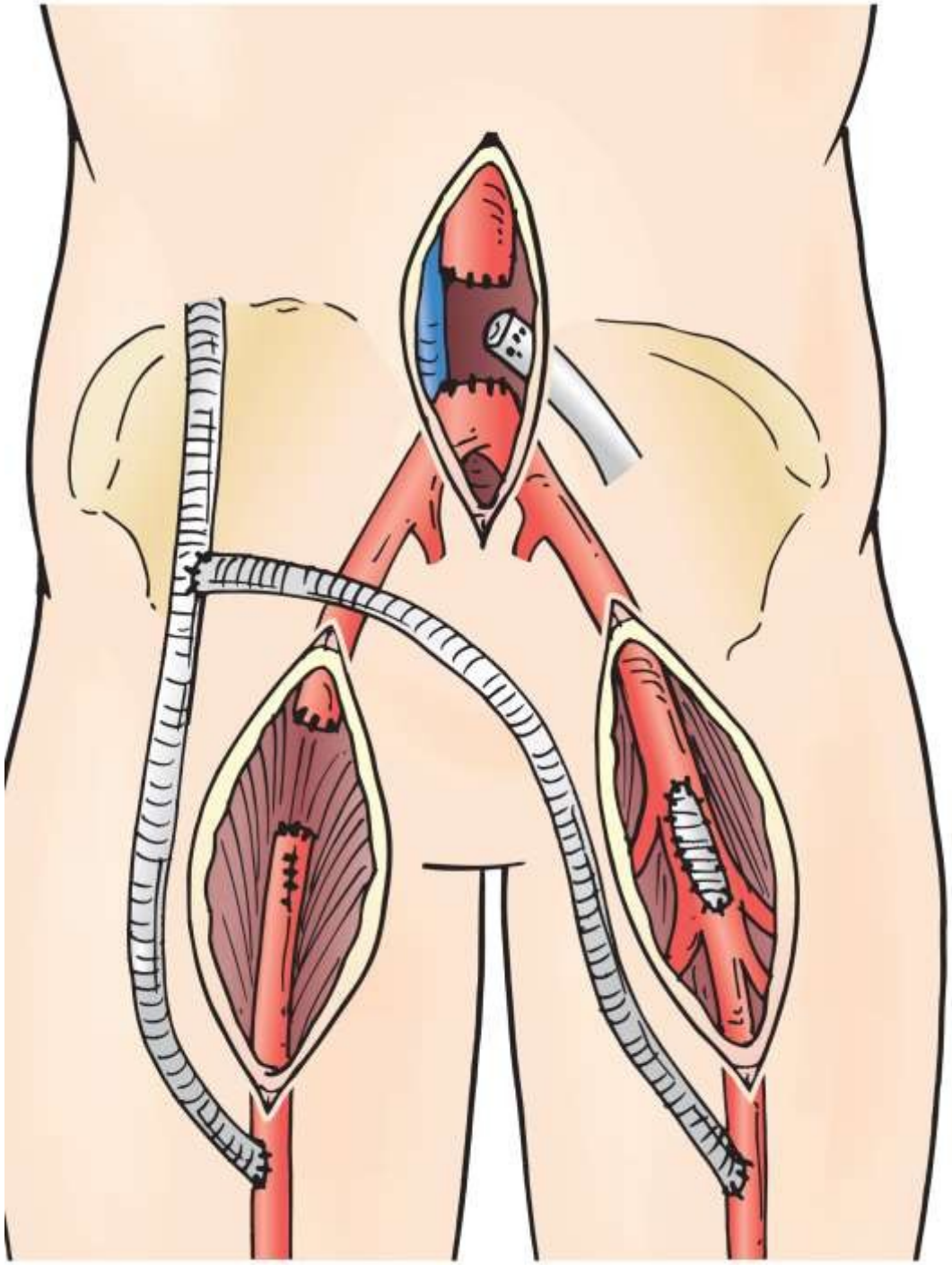

Rifampin-bonded / silver-coated Sentetik Greftler

- Bu greftler, arteriyel allogreftler veya in situ yapılan rekonstrüksiyonda otojen ven ven grefti için sıklıkla gerekli olan uzun süreli ameliyatı tolere edemeyen hastalar için tercih edilir.
- Rifampin bağlı veya gümüş kaplamalı sentetik greftlerle reinfeksiyon oranlarının düşük olduğu bildirilse de, arteriyel allogreftler veya venöz otogreftler, rifampin bağlı sentetik greftlere göre daha dirençlidir.
- Bulaşıcı oranları gümüş kaplı greftlerle karşılaştırmak için yeterince yayınlanmış veri yoktur.

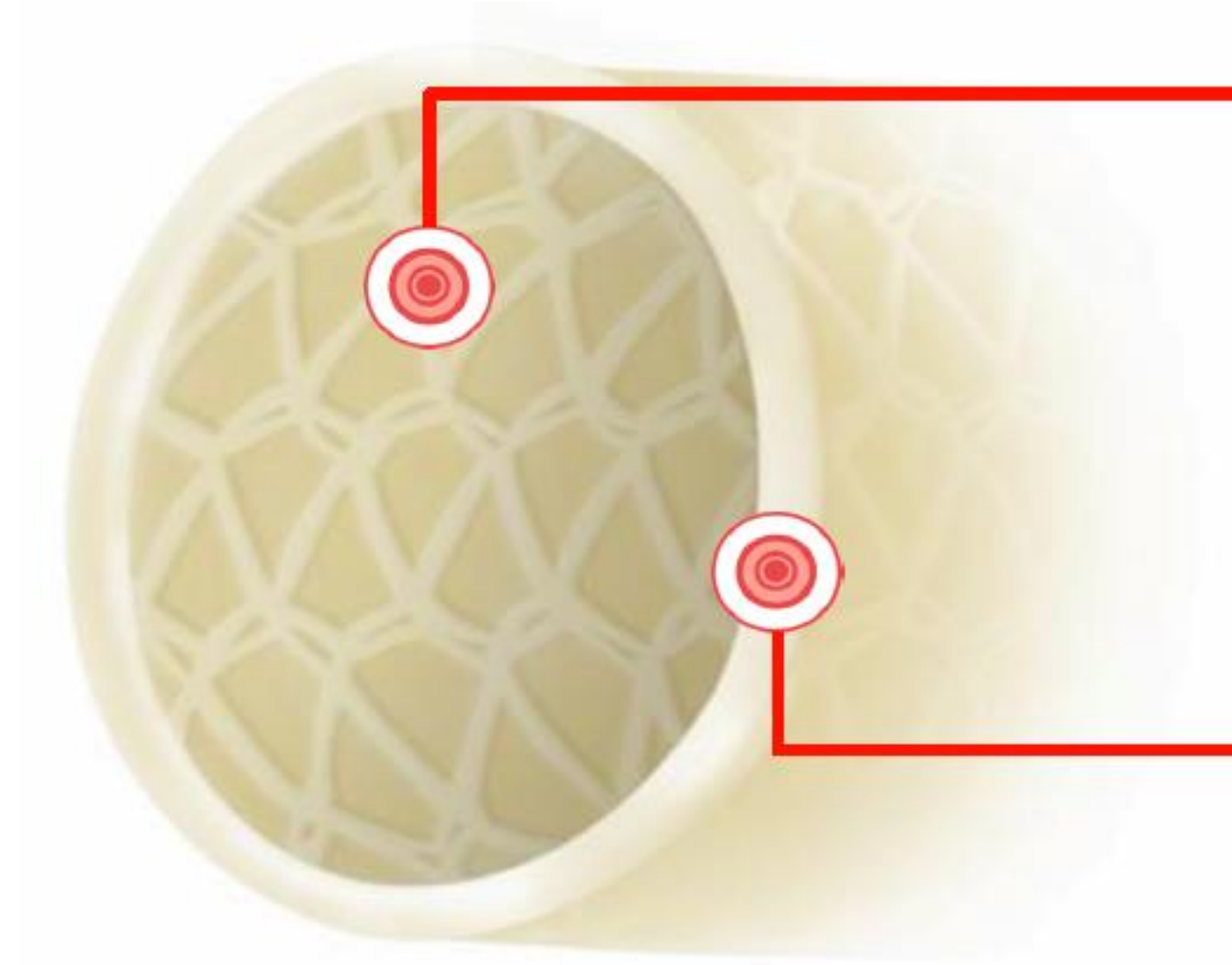

Flow surface

- Smooth
- Non-thrombogenic
- Non-porous

Composite wall

- Crosslinked ovine collagen
- Reinforcing polyester mesh

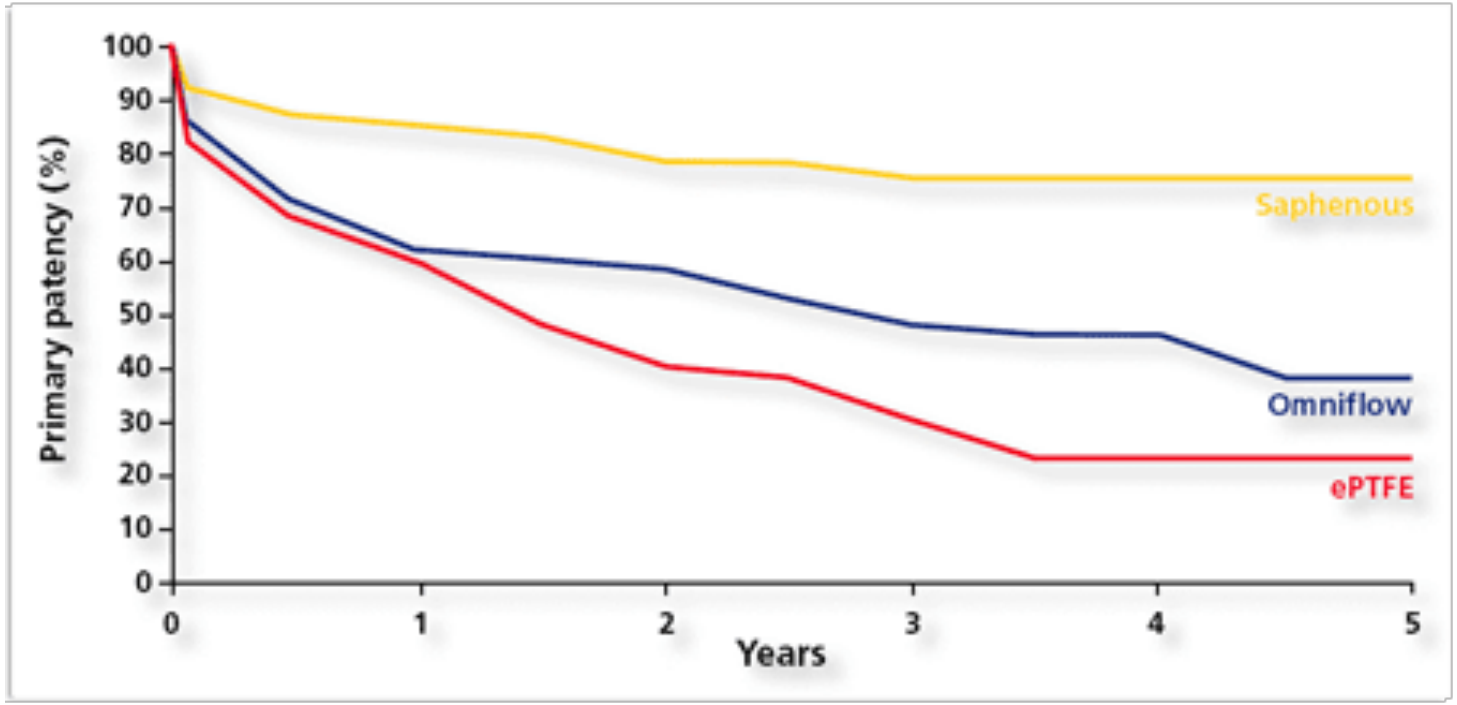
Primary patency (%)
100
90
80
70
60
50
40
30
20
10
0
0
1
2
3
4
5
Years
Saphenous
Omniflow
ePTFE

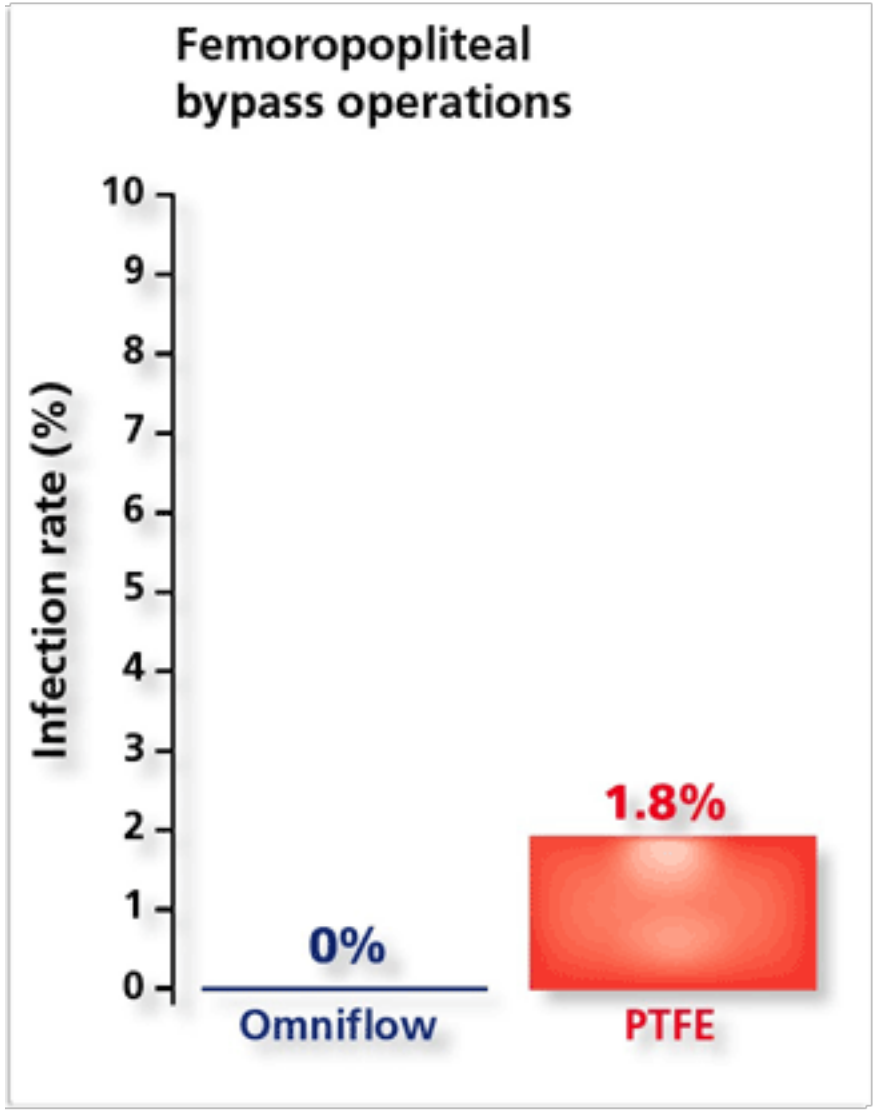
Femoropopliteal
bypass operations
Infection rate (%)
10
9
8
7
6
5
4
3
2
1
0
0%
1.8%
Omniflow
PTFE

Kriyopreserv / taze arteriyel allogreftler / otojen yüzeyel femoral venöz greftler.

- Bu greftler yerinde yeniden yaygın olarak kullanılmıştır.
- Arteriyal allogreftleri ve otojen venöz greftler, rifampin bağlı greftler gibi sentetik materyal ile meydana gelenlerden daha düşük bir enfeksiyon oranıyla ilişkilidir.
- Otojen venöz greftler, arteriyel allogreftlerle zaman içinde meydana gelen greft dejenerasyonu nedeniyle arteriyel allogreftlere göre daha uzun bir açıklığa sahip olabilir.
- Venöz otogreftler, arteriyel allogreftlerde bulunan HLA sınıf II antijen ekspresyonundan yoksundur.

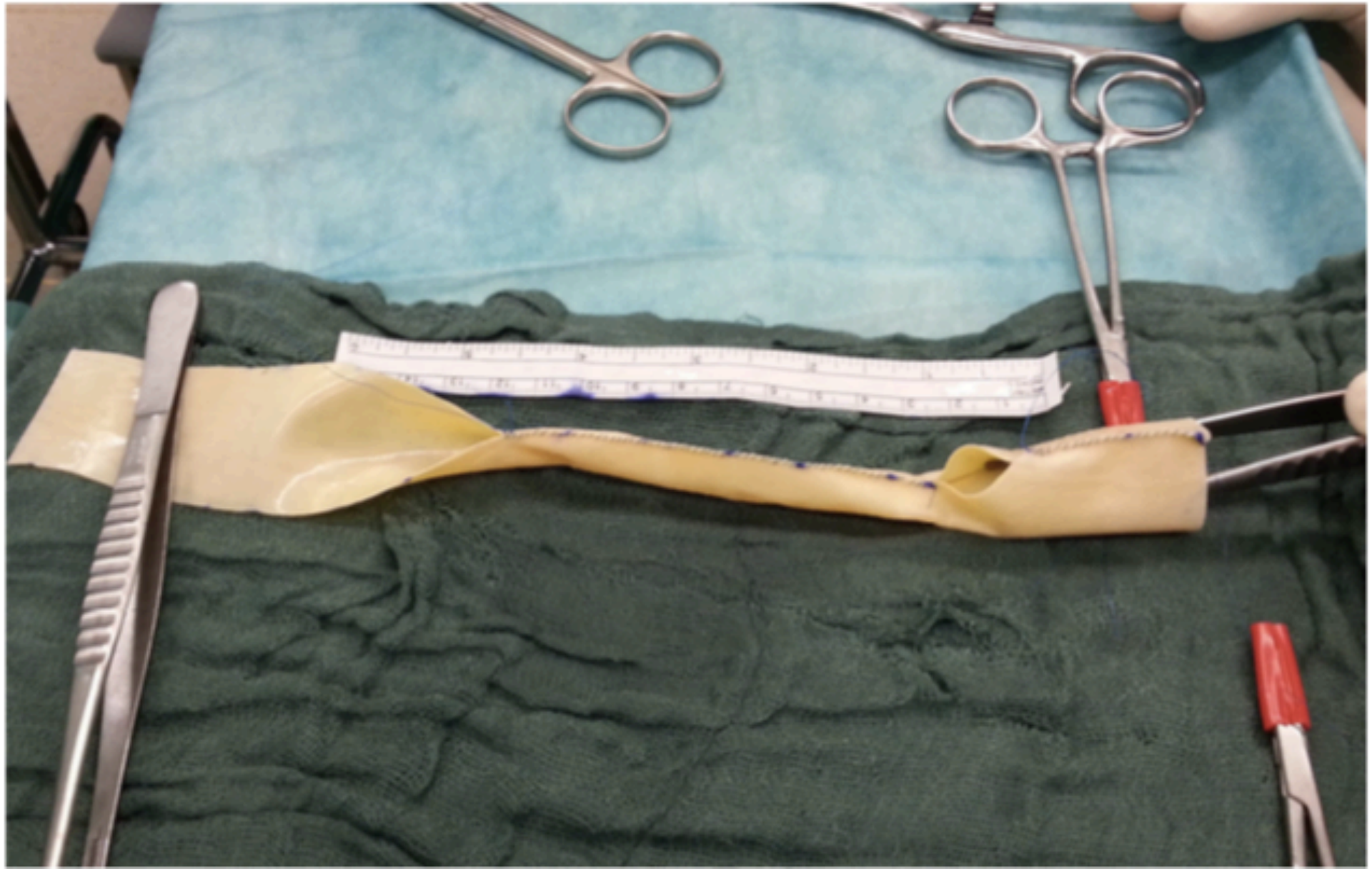

Başlıca dezavantajları şunlardır:

(1) Prostetik greftlere göre daha az dayanıklı olabilirler, çünkü muhtemelen kullanımdan önce **uzun süreli depolama** ve aortik allograft dokusunun immün reddi nedeniyle zamanla dejenere olurlar.

(2) Kullanımları, gevreklik ve **anastomoz kanaması nedeniyle** allogreftin intraoperatif rüptürü dahil,% 16 ila% 23 komplikasyon oranları ile ilişkilidir.

(3) Acil durum prosedürleri için uygun olmayabilir, çünkü **önceden sipariş edilmesi** gerekir ve gerekli uzunluk, çap, şekil ve boyutlandırma mevcut olmayabilir

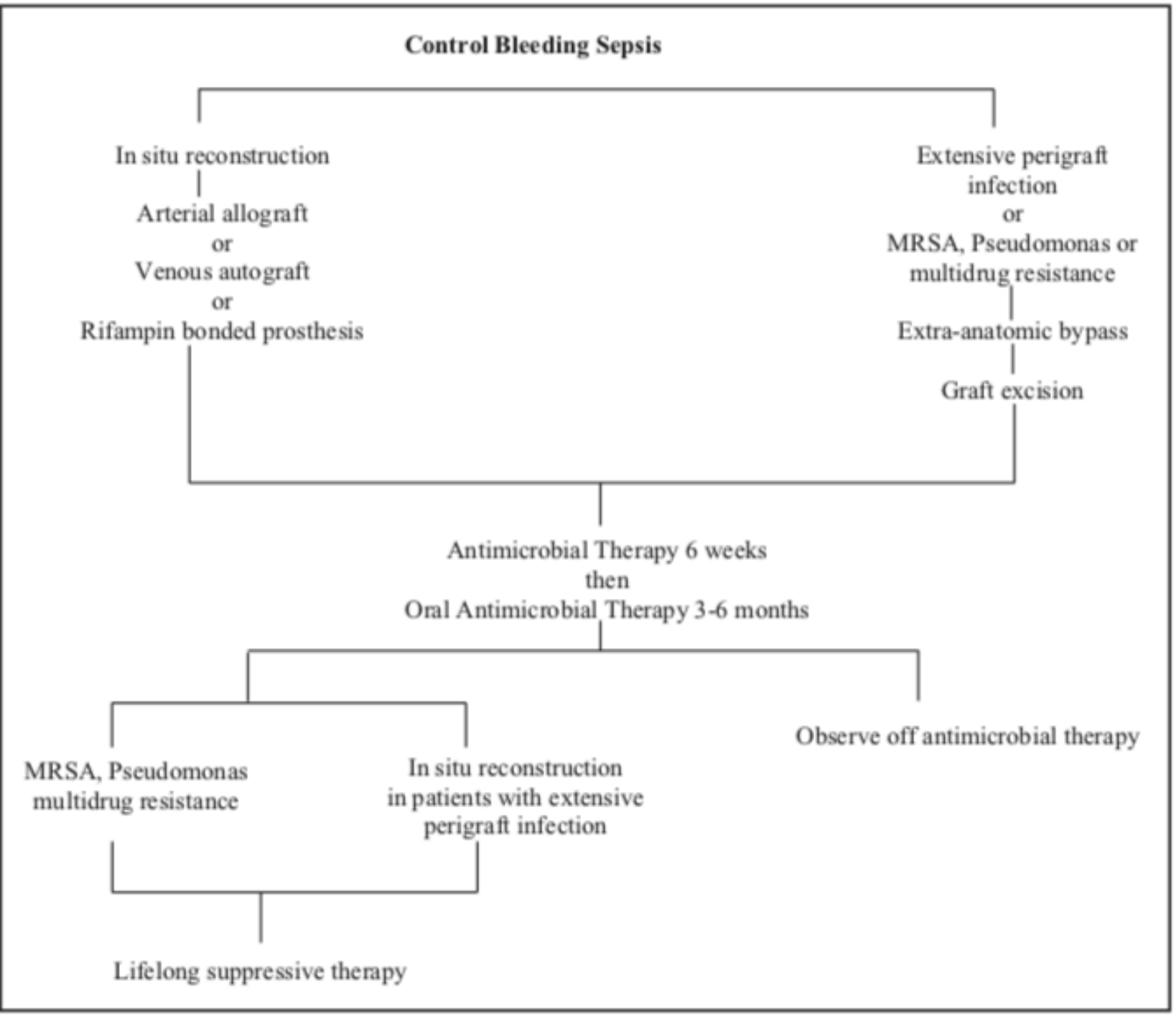

Figure 6. Algorithm for intra-abdominal vascular graft infection management.
MRSA indicates methicillin-resistant *Staphylococcus aureus*.

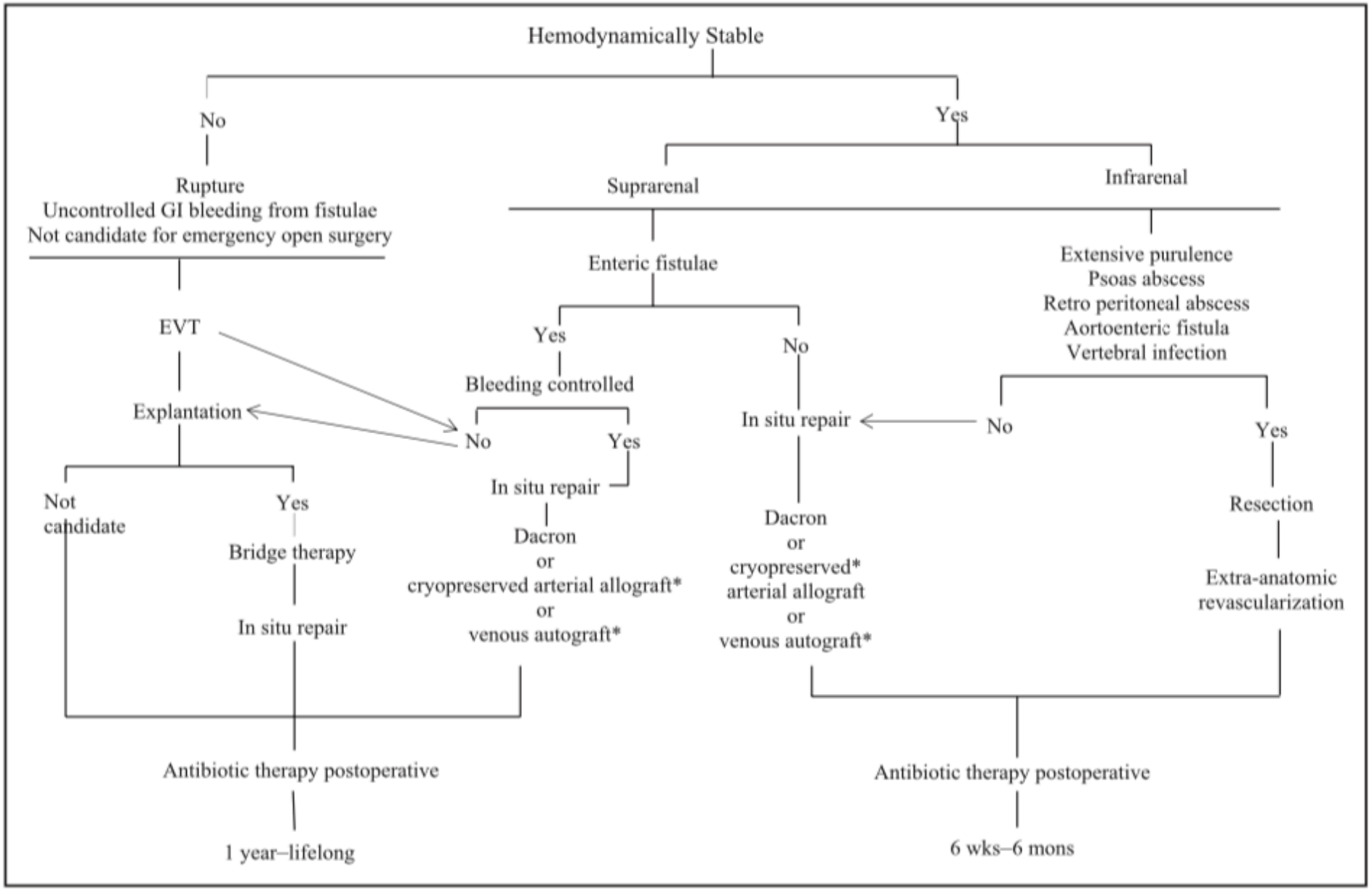

Figure 8. Algorithm for management of intra-abdominal aortic mycotic aneurysms.
*Experience limited with use of cryopreserved arterial allograft or venous autograft.
EVT indicates endovascular therapy; and GI, gastrointestinal.

Endovasküler tedavi

EVT köprü tedavisi olarak düşünülebilir daha sonra bu hastalarda açık cerrahi tedavi (Sınıf IIb; Kanıt Düzeyi C):

i. kararsız hemodinamik rüptürü ile birlikte,

ii. aortoenterik fistül veya aortobronşiyal fistül ile kontrolsüz kanaması olanlar, veya

iii. Altta yatan kompoze koşullar nedeniyle açık cerrahi onarım için uygun olmayanlar.

Endovasküler cihazın ilk yerleştirilmesinden sonra, cihazın çıkarılması, aort MA'nın rezeksiyonu ve aort rekonstrüksiyonu düşünülebilir (Sınıf IIb; Kanıt Düzeyi C).

antibiyotik yüklü polimetil metakrilat (PMMA) boncukları

Takip

- Ekstremite kaybı infected aortofemoral > aortoiliac reconstruction
- Unilateral axillofemoral PFA veya SFA açıklık %94 (6 ay)
- Axillopopliteal bypass açıklık %42 (6 ay)

Diğer Vasküler Greft Enfeksiyonları

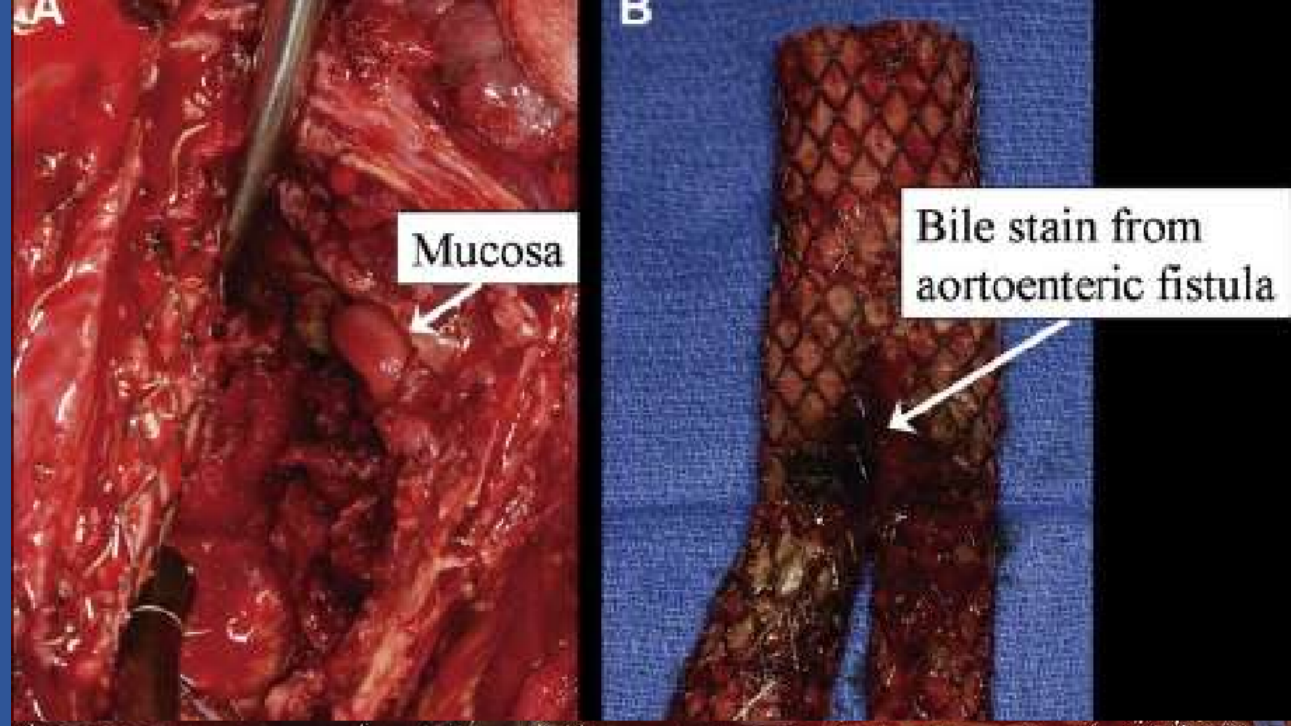

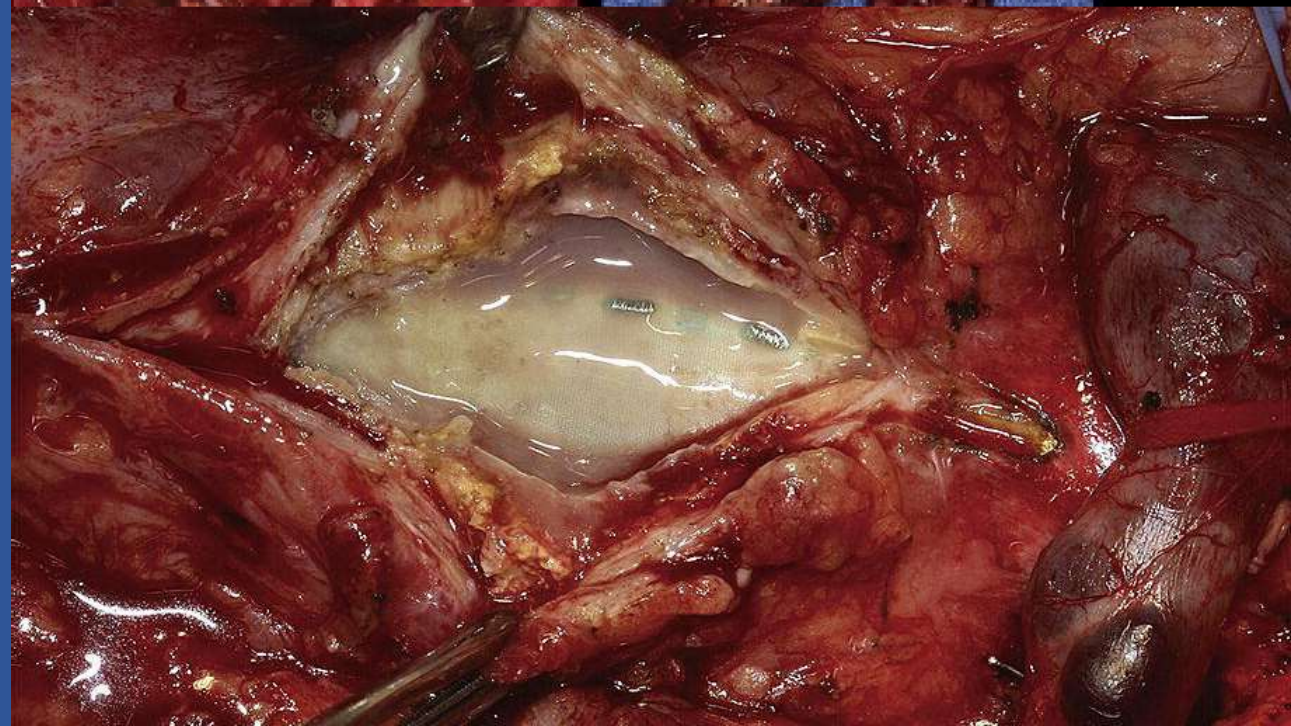

TEVAR

EVAR

Enfeksiyon < 1%

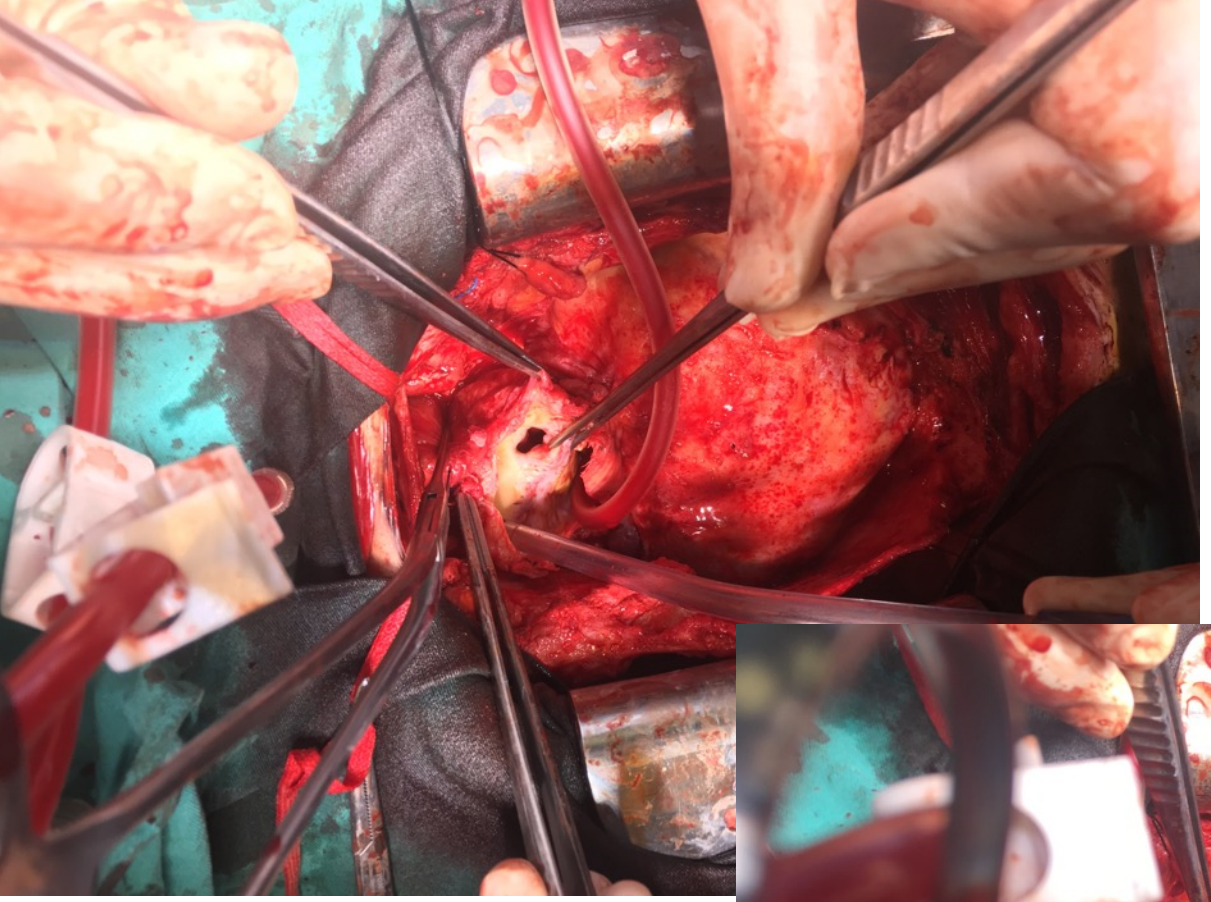

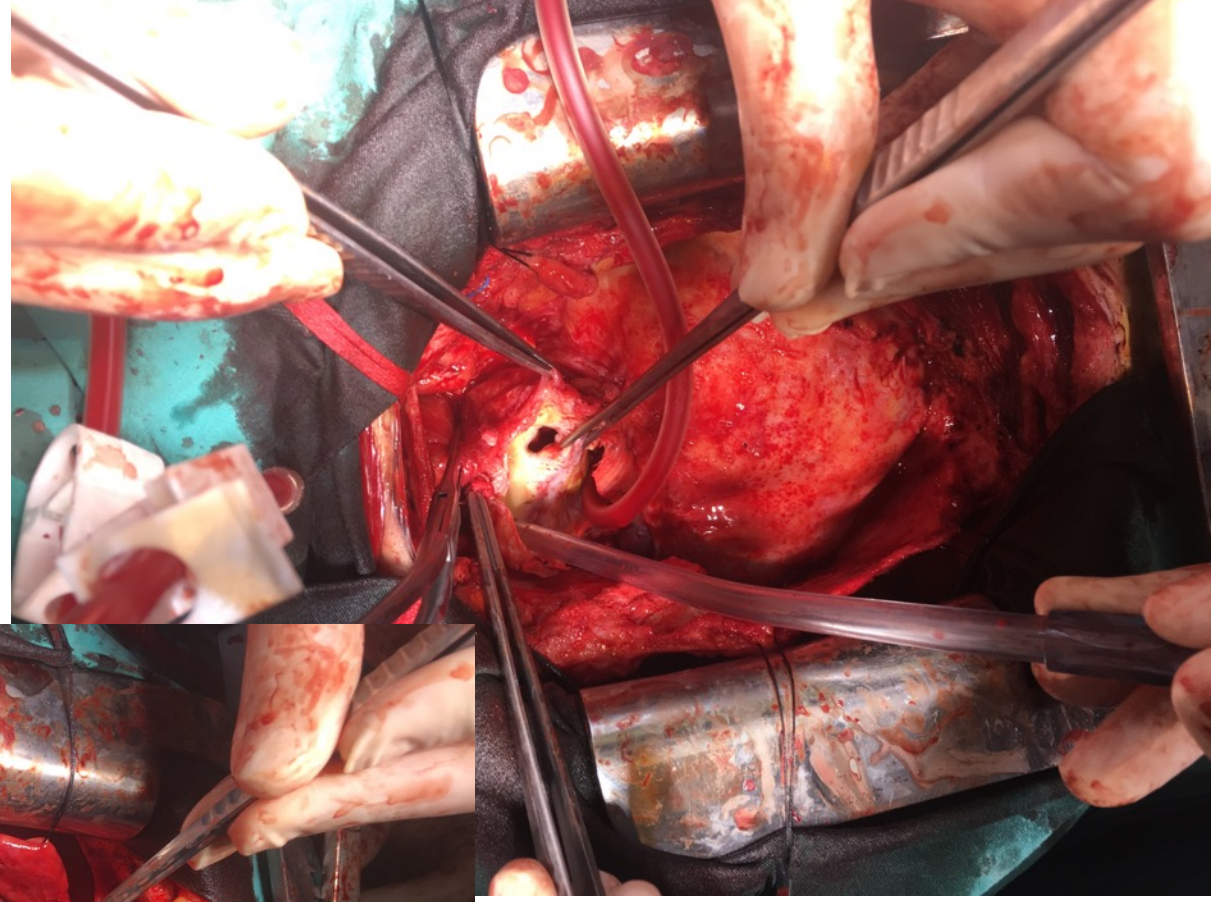

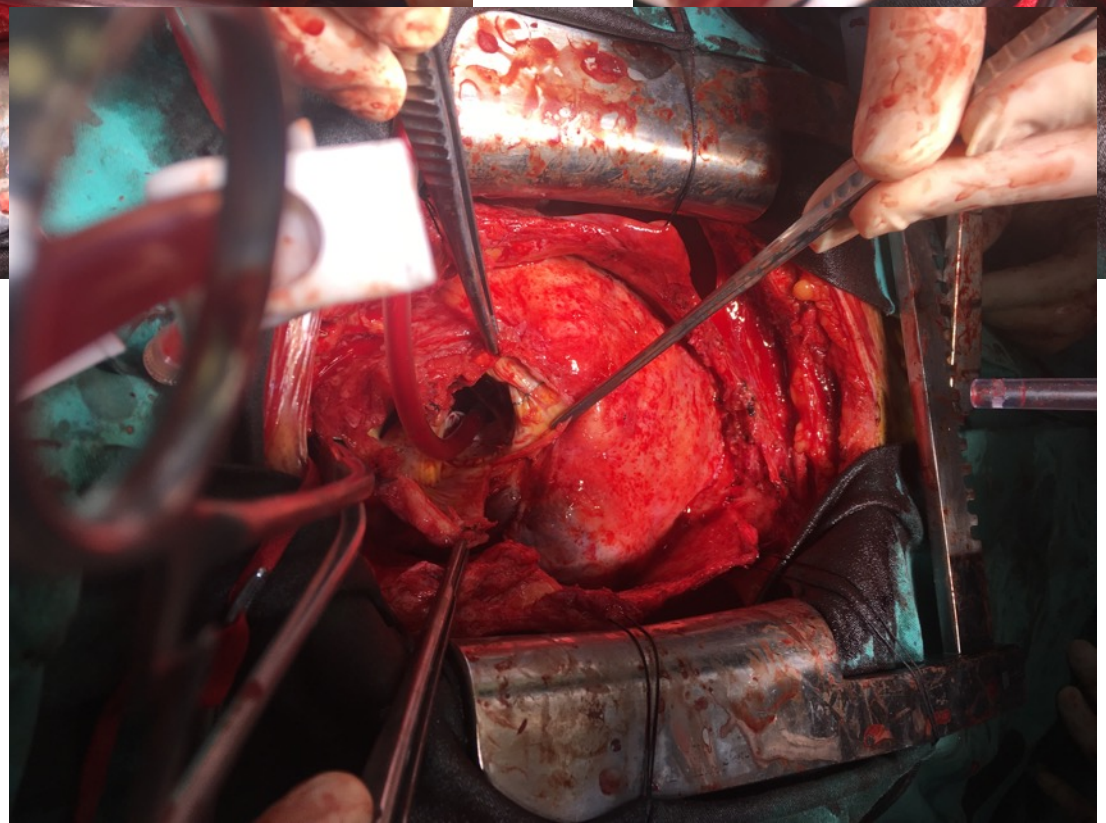

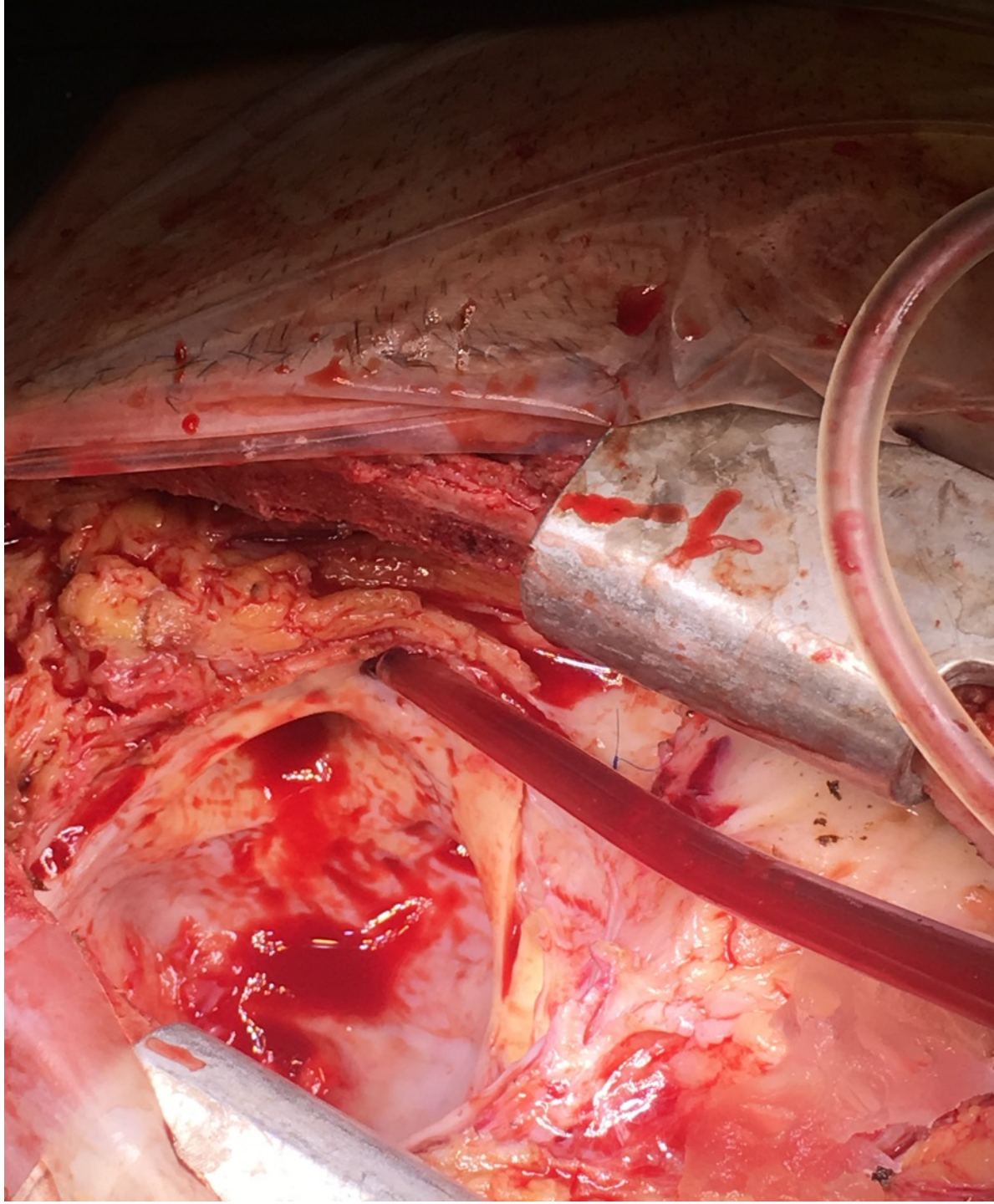

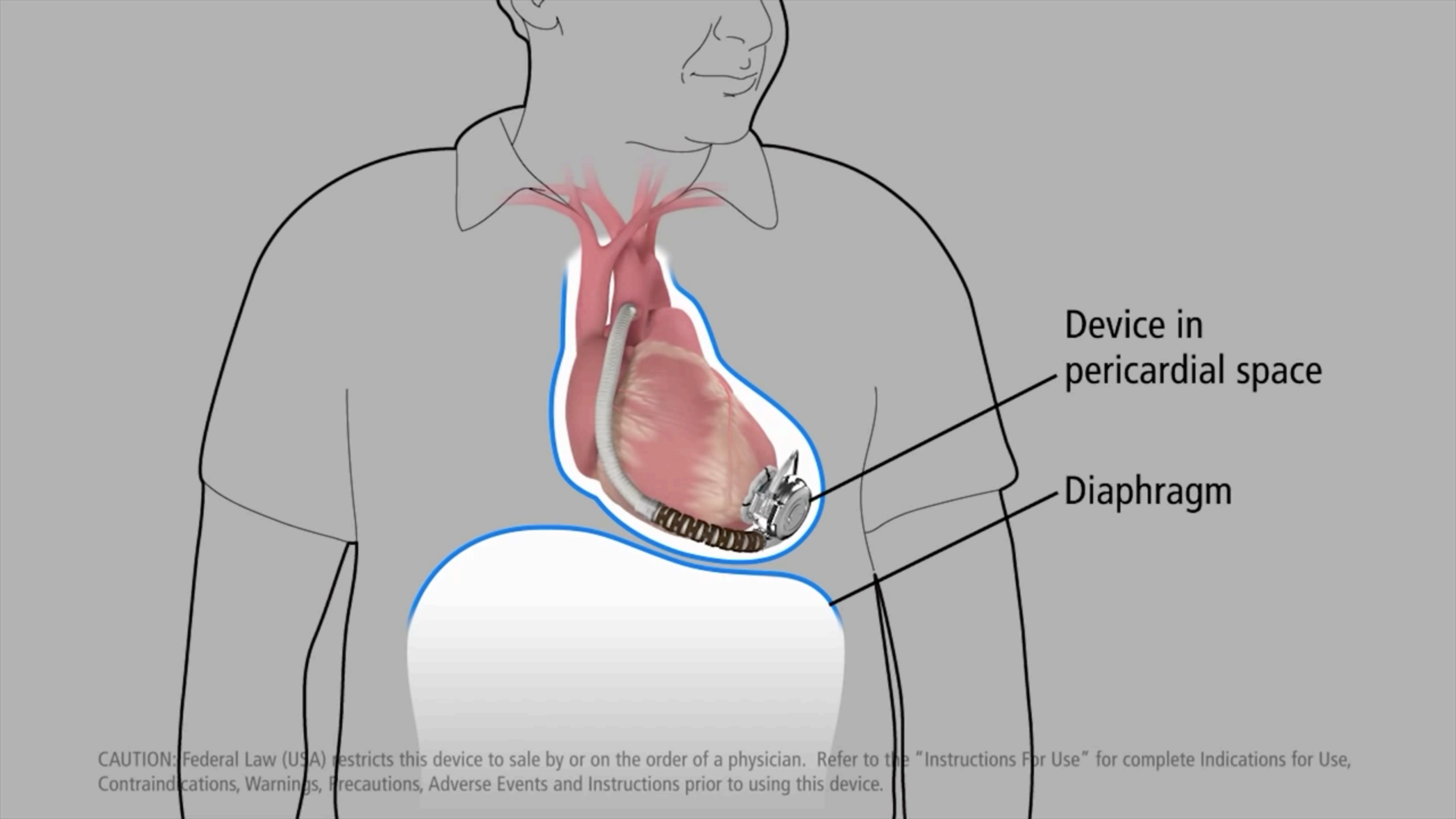

CAUTION: Federal Law (USA) restricts this device to sale by or on the order of a physician. Refer to the "Instructions For Use" for complete Indications for Use, Contraindications, Warnings, Precautions, Adverse Events and Instructions prior to using this device.

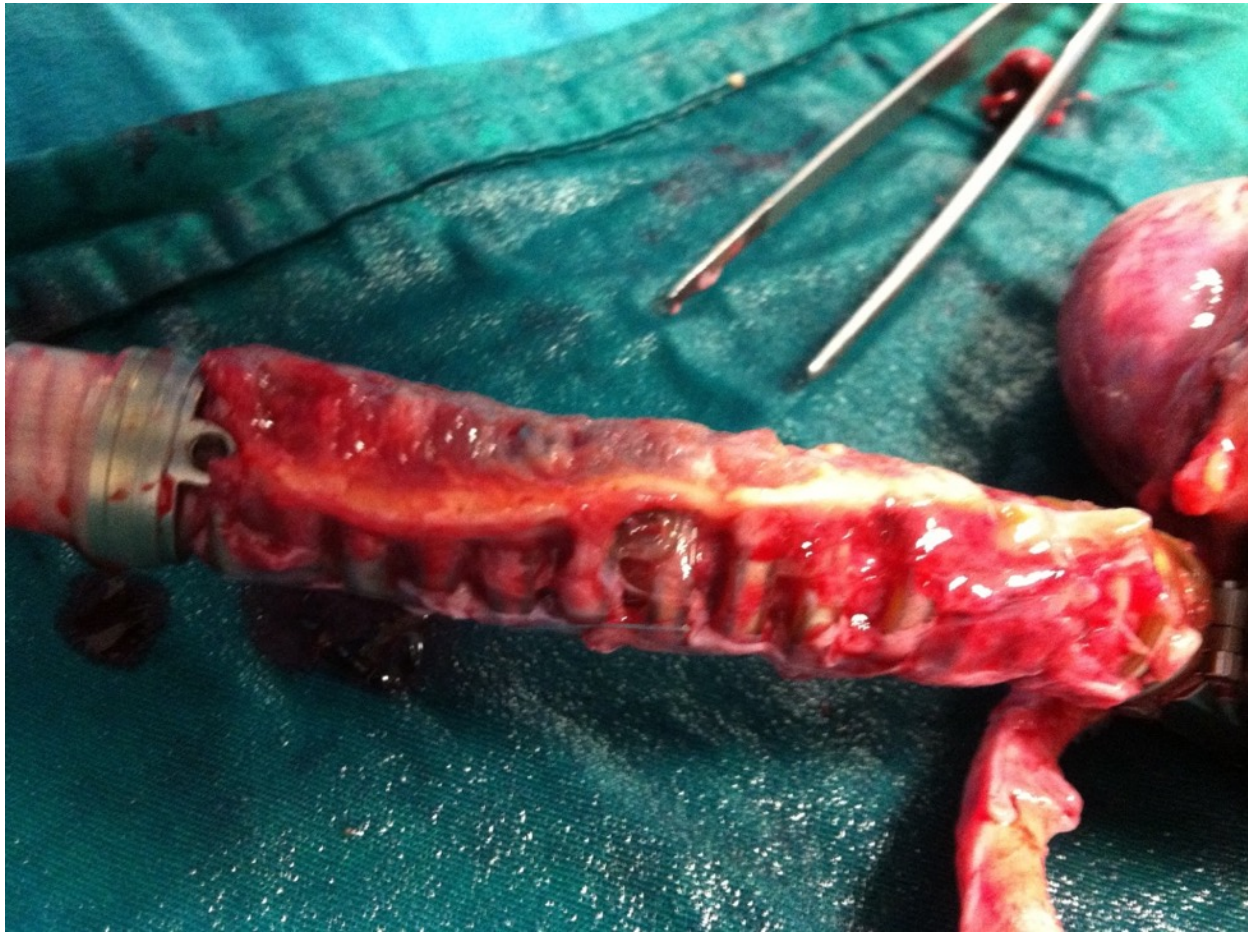

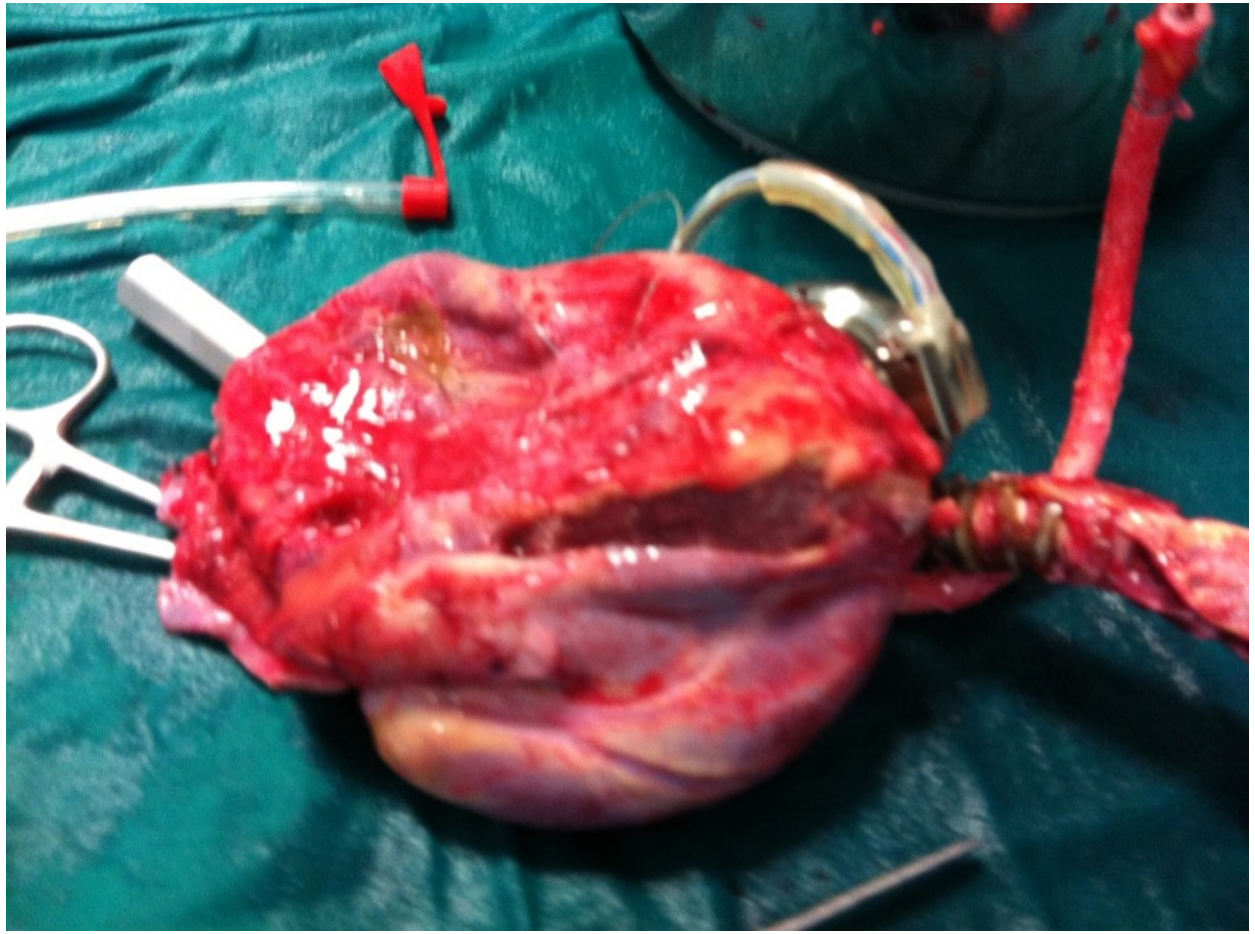

Gsm: 0 505 256 44 38
E mail: drukervan@yahoo.com