Mycobacterium chimaera: Son Durum

Dr Şirin Menekşe
Kartal Koşuyolu Kalp Damar Cerrahi Hastanesi

Sunum Planı

- *Mycobacterium chimaera*
- *Salgınının ortaya çıkışı*
- *Isıtıcı-Soğutucu Cihazlar*
- *Klinik*
- *Tanı- Tedavi*
- *Korunma*
- *Dünya'da durum ne?*
- *Türkiye'de durum ne??????*

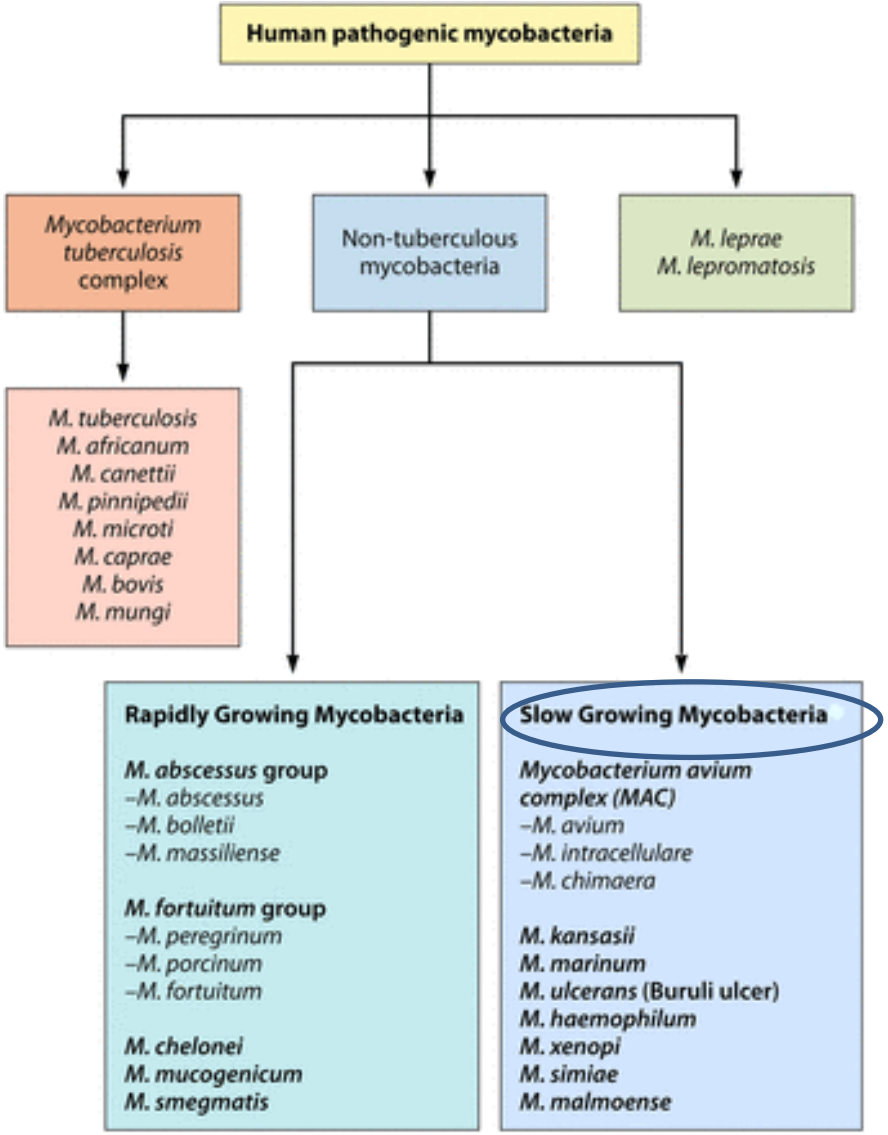
Human pathogenic mycobacteria
Mycobacterium tuberculosis complex
Non-tuberculous mycobacteria
M. leprae
M. lepromatosis
M. tuberculosis
M. africanum
M. canettii
M. pinnipedii
M. microti
M. caprae
M. bovis
M. mungi
Rapidly Growing Mycobacteria
M. abscessus group
–M. abscessus
–M. bolletii
–M. massiliense
M. fortuitum group
–M. peregrinum
–M. porcinum
–M. fortuitum
M. chelonei
M. mucogenicum
M. smegmatis
Slow Growing Mycobacteria
Mycobacterium avium complex (MAC)
–M. avium
–M. intracellulare
–M. chimaera
M. kansasii
M. marinum
M. ulcerans (Buruli ulcer)
M. haemophilum
M. xenopi
M. simiae
M. malmoense

International Journal of Systematic and Evolutionary Microbiology (2004), 54, 1277–1285 DOI 10.1099/ijs.0.02777-0

Proposal to elevate the genetic variant MAC-A, included in the *Mycobacterium avium* complex, to species rank as *Mycobacterium chimaera* sp. nov.

Enrico Tortoli,[1] Laura Rindi,[2] Maria J. Garcia,[3] Patrizia Chiaradonna,[4] Rosanna Dei,[5] Carlo Garzelli,[2] Reiner M. Kroppenstedt,[6] Nicoletta Lari,[2] Romano Mattei,[7] Alessandro Mariottini,[1,8] Gianna Mazzarelli,[1,9] Martha I. Murcia,[3] Anna Nanetti,[10] Paola Piccoli[11] and Claudio Scarparo[11]

The possibility that the strains included within the *Mycobacterium avium* complex (MAC), but not belonging either to *M. avium* or to *Mycobacterium intracellulare*, may be members of undescribed taxa, has already been questioned by several taxonomists. A very homogeneous cluster of 12 strains characterized by identical nucleotide sequences both in the 16S rDNA and in the 16S–23S internal transcribed spacer was investigated. Similar strains, previously reported in the literature, had been assigned either to the species *M. intracellulare* on the basis of the 16S rDNA similarity or to the group of MAC intermediates. However, several phenotypical and epidemiological characteristics seem to distinguish these strains from all other MAC organisms. The unique mycolic acid pattern obtained by HPLC is striking as it is characterized by two clusters of peaks, instead of the three presented by all other MAC organisms. All of the strains have been isolated from humans and all but one came from the respiratory tract of elderly people. The clinical significance of these strains, ascertained for seven patients, seems to suggest an unusually high virulence. The characteristics of all the strains reported in the literature, genotypically identical to the ones described here, seem to confirm our data, without reports of isolations from animals or the environment or, among humans, from AIDS patients. Therefore, an elevation of the MAC variant was proposed and characterized here, with the name *Mycobacterium chimaera* sp. nov.; this increases the number of species included in the *M. avium* complex. The type strain is FI-01069^T (=CIP 107892^T=DSM 44623^T).

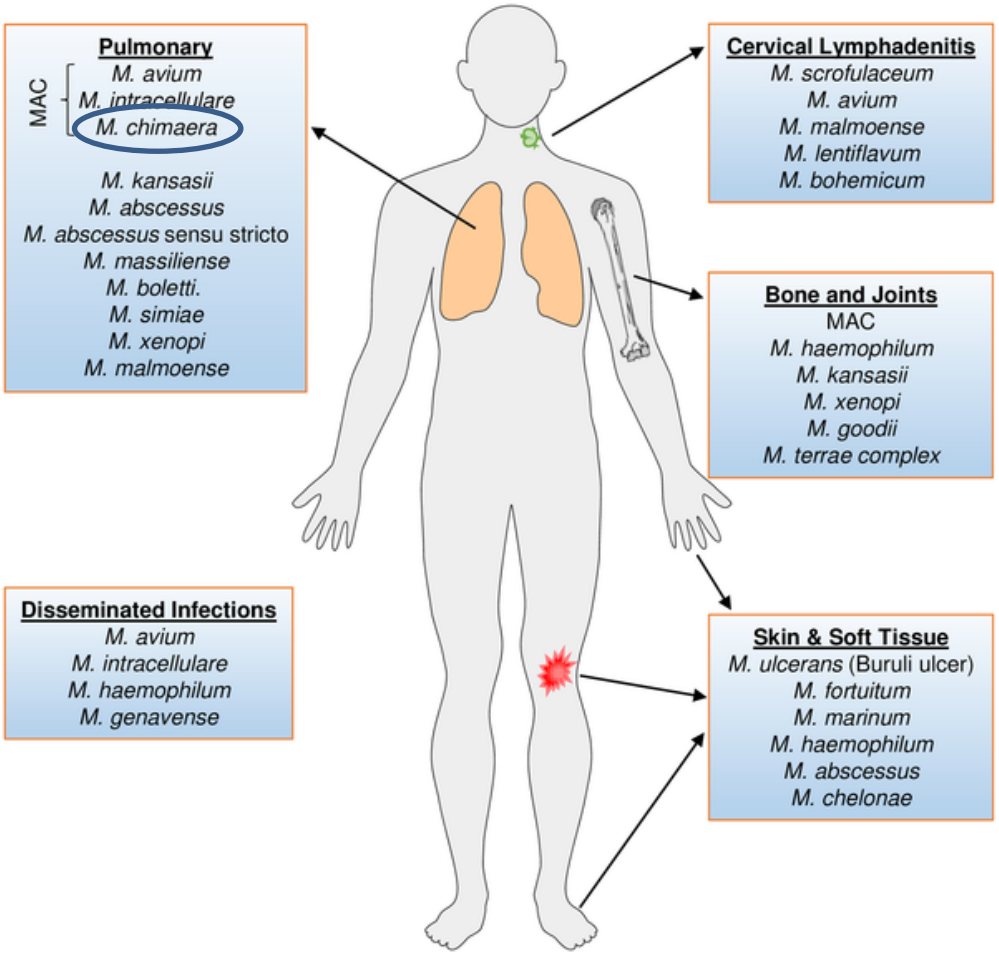
Pulmonary
MAC
M. avium
M. intracellulare
M. chimaera
M. kansasii
M. abscessus
M. abscessus sensu stricto
M. massiliense
M. boletti.
M. simiae
M. xenopi
M. malmoense
Cervical Lymphadenitis
M. scrofulaceum
M. avium
M. malmoense
M. lentiflavum
M. bohemicum
Bone and Joints
MAC
M. haemophilum
M. kansasii
M. xenopi
M. goodii
M. terrae complex
Disseminated Infections
M. avium
M. intracellulare
M. haemophilum
M. genavense
Skin & Soft Tissue
M. ulcerans (Buruli ulcer)
M. fortuitum
M. marinum
M. haemophilum
M. abscessus
M. chelonae

JCM
Journals.ASM.org

Absence of *Mycobacterium intracellulare* and Presence of *Mycobacterium chimaera* in Household Water and Biofilm Samples of Patients in the United States with *Mycobacterium avium* Complex Respiratory Disease

Richard J. Wallace, Jr.,[a] Elena Iakhiaeva,[a] Myra D. Williams,[b] Barbara A. Brown-Elliott,[a] Sruthi Vasireddy,[a] Ravikiran Vasireddy,[a] Leah Lande,[c,d] Donald D. Peterson,[c,d] Janet Sawicki,[d] Rebecca Kwait,[c] Wellington S. Tichenor,[e] Christine Turenne,[f] Joseph O. Falkinham III[b]

Mycobacteria/Nocardia Research Laboratory, The University of Texas Health Science Center at Tyler, Tyler, Texas, USA[a]; Department of Biological Sciences, Virginia Polytechnic Institute and State University, Blacksburg, Virginia, USA[b]; Pulmonary and Critical Care Division, Lankenau Hospital, Wynnewood, Pennsylvania, USA[c]; Lankenau Institute for Medical Research, Wynnewood, Pennsylvania, USA[d]; 642 Park Avenue, New York, New York, USA[e]; Saskatchewan Disease Control Laboratory, Regina, Saskatchewan, Canada[f]

TABLE 3 Species in household water cultures (one culture per site) initially identified as *M. intracellulare* and then retested by ITS sequencing compared to the number of isolates of *M. avium* recovered from the same samples

	No. of isolates identified by nonsequencing methods[a]		No. (%) of isolates identified by ITS sequencing				
Study no.	*M. avium*	*M. intracellulare*	*M. avium*	MAC X	*M. chimaera*	*M. intracellulare*	Reference(s)
1	20	4	3	0	1	0	6
2	64	8	0	3	5	0	L. Lande, unpublished data; 17
3	36	21[b]	0	5	16	0	1
4	18	8	0	0	8	0	R. J. Wallace, Jr., unpublished data
5	3	0	0	0	0	0	2
Total	141	41	3 (7.3)	8 (19.5)	30 (73.2)	0	

[a] Identification by either a DNA probe (AccuProbe; Hologic Gen-Probe Inc.) or 16S rRNA gene PCR (9, 10).
[b] Eighteen additional isolates were not tested.

- Çok yaygın: Yeryüzü sularında, çeşme sularında ve su ile çalışan cihazlarda, toprakta
- **Düşük virülanslı**, fırsatçı patojen

A review of the microbiological problems and biofilms associated with *Mycobacterium chimaera* in heater cooler units used for cardiopulmonary bypass

Jimmy Walker, Ginny Moore, Samuel Collins, Simon Parks, Mark I. Garvey, Theresa Lamagni, Grace Smith, Lincoln Dawkin, Simon Goldenberg, Meera Chand

- Lipit bakımından zengin dış membran-hidrofobik bariyer-yüzeylere yapışma ve dezenfektanlara direnç
- Kalın ekstraselüler biyofilm-Fiziksel-kimyasal bariyer-dezenfektan geçişi için

-biyofilmde 10.000 CFU / cm2

- Dezenfektanlara direnç (klor, kloramin, ozon)
- Su sistemlerinden aerosolizasyon

M. avium complex aerosolize su kabarcıklarında 10.000 kat daha yüksek konsantrasyonda

Daniel Diekema. Mycobacterium chimaera Infections After Cardiovascula Surgery: Lessons From a Global Outbreak . Trans Am Clin Climatol Assoc. 2019; 130: 136–144

JCM
Journals.ASM.org

Prosthetic Valve Endocarditis and Bloodstream Infection Due to *Mycobacterium chimaera*

Yvonne Achermann,[a] Matthias Rössle,[b] Matthias Hoffmann,[c] Vanessa Deggim,[d] Stefan Kuster,[a] Dieter R. Zimmermann,[b] Guido Bloemberg,[d] Michael Hombach,[d] Barbara Hasse[a]

Division of Infectious Diseases and Hospital Epidemiology, University and University Hospital Zurich, Zurich, Switzerland[a]; Institute of Clinical Pathology, University and University Hospital Zurich, Zurich, Switzerland[b]; Division of Infectious Diseases and Hospital Epidemiology, Cantonal Hospital St. Gallen, St. Gallen, Switzerland[c]; Institute of Medical Microbiology, University of Zurich, Zurich, Switzerland[d]

Prosthetic valve endocarditis (PVE) due to fast-growing nontuberculous mycobacteria (NTM) has been reported anecdotally. Reports of PVE with slowly growing NTM, however, are lacking. We present here one case of PVE and one case of bloodstream infection caused by *Mycobacterium chimaera*. Randomly amplified polymorphic DNA (RAPD)-PCR indicated a relatedness of the two *M. chimaera* strains. Both patients had heart surgery 2 years apart from each other. A nosocomial link was not detected.

J ClinMicrobiol 2013; 51:1769–73

Prosthetic Valve Endocarditis and Bloodstream Infection Due to *Mycobacterium chimaera*

Yvonne Achermann,[a] Matthias Rössle,[b] Matthias Hoffmann,[c] Vanessa Deggim,[d] Stefan Kuster,[a] Dieter R. Zimmermann,[b] Guido Bloemberg,[d] Michael Hombach,[d] Barbara Hasse[a]

- Haziran 2011, 58 yaş- erkek hasta
- Mitral ve aort replasmanı
- 2008 yılında Aort ve mitral ring ile onarım
- 12 ay önce intermittent ateş, kilo kaybı ve nefes darlığı
- Negatif kan kültürü ve normal TEE

J ClinMicrobiol 2013; 51:1769–73

JCM
Journals.ASM.org

Prosthetic Valve Endocarditis and Bloodstream Infection Due to *Mycobacterium chimaera*

- Karaciğer
- Dalak biyopsisi

Nonspesifik granülomatöz inflamasyon
Sarkoidoz tanısı

- PA Ac grafisinde retiküler patern
- Sarkoidoz- Steroid tedavisi
- Bronkoalveoler lavaj: Mycobacteri negatif
- Ciddi solunum yetmezliği - Mayıs 2011 hospitalizasyon
- Kan kültürleri negatif
- TEE: Ciddi mitral ve aort yetmezliği

J ClinMicrobiol 2013; 51:1769–73

JCM
Journals.ASM.org

Prosthetic Valve Endocarditis and Bloodstream Infection Due to *Mycobacterium chimaera*

- Cerrahi esnasında protez ringde ciddi yıpranma,
- Mitral ve aort kapakta destruksiyon
- Histopatolojik incelemede kapaklarda kısmi nekroz,makrofaj içeren periyodik asid şift ve aside dirençli boyanma gösteren inflamasyon
- Non-tüberküloz mikobakteri PVE

J ClinMicrobiol 2013; 51:1769–73

JCM
Journals.ASM.org

Prosthetic Valve Endocarditis and Bloodstream Infection Due to *Mycobacterium chimaera*

- Doku incelemesi: M. Avium Complex (MAC)
- Mitral kapak protez ring kültür: M. chimaera
- Trakeal sekresyon ve üç kan kültürü

J ClinMicrobiol 2013; 51:1769–73

MAJOR ARTICLE

Prolonged Outbreak of *Mycobacterium chimaera* Infection After Open-Chest Heart Surgery

Hugo Sax,[1,a] Guido Bloemberg,[2,a] Barbara Hasse,[1,a] Rami Sommerstein,[1] Philipp Kohler,[1] Yvonne Achermann,[1] Matthias Rössle,[3] Volkmar Falk,[4] Stefan P. Kuster,[1] Erik C. Böttger,[2,b] and Rainer Weber[1,b]

[1]Division of Infectious Diseases and Hospital Epidemiology, University Hospital Zurich, [2]Institute of Medical Microbiology, National Centre for Mycobacteria, University of Zurich, [3]Institute of Surgical Pathology, and [4]Division of Cardiac Surgery, University Hospital Zurich, Switzerland

Abstract: BACKGROUND: Invasive Mycobacterium chimaera infections were diagnosed in 2012 in 2 heart surgery patients on extracorporeal circulation. We launched an outbreak investigation to identify the source and extent of the potential outbreak and to implement preventive measures. METHODS: We collected water samples from operating theaters, intensive care units, and wards, including air samples from operating theaters. Mycobacterium chimaera strains were characterized by randomly amplified polymorphic DNA polymerase chain reaction (RAPD-PCR). Case detection was performed based on archived histopathology samples and M. chimaera isolates since 2006, and the patient population at risk was prospectively surveyed. RESULTS: We identified 6 male patients aged between 49 and 64 years with prosthetic valve endocarditis or vascular graft infection due to M. chimaera, which became clinically manifest with a latency of between 1.5 and 3.6 years after surgery. Mycobacterium chimaera was isolated from cardiac tissue specimens, blood cultures, or other biopsy specimens. We were able also to culture M. chimaera from water circuits of heater-cooler units connected to the cardiopulmonary bypass, and air samples collected when the units were in use. RAPD-PCR demonstrated identical patterns among M. chimaera strains from heater-cooler unit water circuits and air samples, and strains in 2 patient clusters. CONCLUSIONS: The epidemiological and microbiological features of this prolonged outbreak provided evidence for the airborne transmission of M. chimaera from contaminated heater-cooler unit water tanks to patients during open-heart surgery.

Clin Infect Dis 2015 (July 1);61:67

SURVEILLANCE AND OUTBREAK REPORT

Contamination during production of heater-cooler units by *Mycobacterium chimaera* potential cause for invasive cardiovascular infections: results of an outbreak investigation in Germany, April 2015 to February 2016

S Haller [1], C Höller [2], A Jacobshagen [3], O Hamouda [1], M Abu Sin [1], DL Monnet [4], D Plachouras [4], T Eckmanns [1]

1. Department for Infectious Disease Epidemiology, Robert Koch Institute (RKI), Berlin, Germany
2. Bavarian Health and Food Safety Authority (LGL), Oberschleißheim, Germany
3. Federal Institute for Drugs and Medical Devices (BfArM), Bonn, Germany
4. European Centre for Disease Prevention and Control (ECDC), Stockholm, Sweden

Correspondence: Tim Eckmanns (eckmannst@rki.de)

TABLE 2

Mycobacterium chimaera-positive samples from environmental investigations at the manufacturing site of new HCUs and of used HCUs from at the manufacturer's service centre, July 2014 to June 2015

Date	Type of sample	Source of sample
16 Jul 2014	Water (100 mL)	Used HCU from Switzerland
29 Jul 2014	Water (100 mL)	New HCU from manufacturing site
5 Aug 2014	Water (100 mL)	New HCU from manufacturing site
11 Aug 2014	Water (100 mL)	New HCU from manufacturing site
19 Feb 2015	Water (100 mL)	Used HCU from the Netherlands
10 Jun 2015	Water (volume not specified)	Sample taken in pump assembly area at the manufacturing site

HCU: heater-cooler unit.

The environmental investigations were performed by the manufacturer.

Haller S et al. Eurosurveillance 2016;21:17

Erik Svensson, Elsebeth Tvenstrup Jensen,
Erik Michael Rasmussen, Dorte Bek Folkvardsen,
Anders Norman, Troels Lillebaek

Mycobacterium chimaera in Heater–Cooler Units in Denmark Related to Isolates from the United States and United Kingdom

- Danimarka, 5 merkez, cihazların %80'i kontamine
- A.B.D., İngiltere cihazları ile aynı suş
- Maquet marka cihazlar: *M. chimaera* , farklı genetikte suş

- Kaynak: Sorin 3T Isıtıcı Soğutucu Cihaz
- Muhtemelen 8-10 yıldır cihazlar kontamine

Küresel Salgın

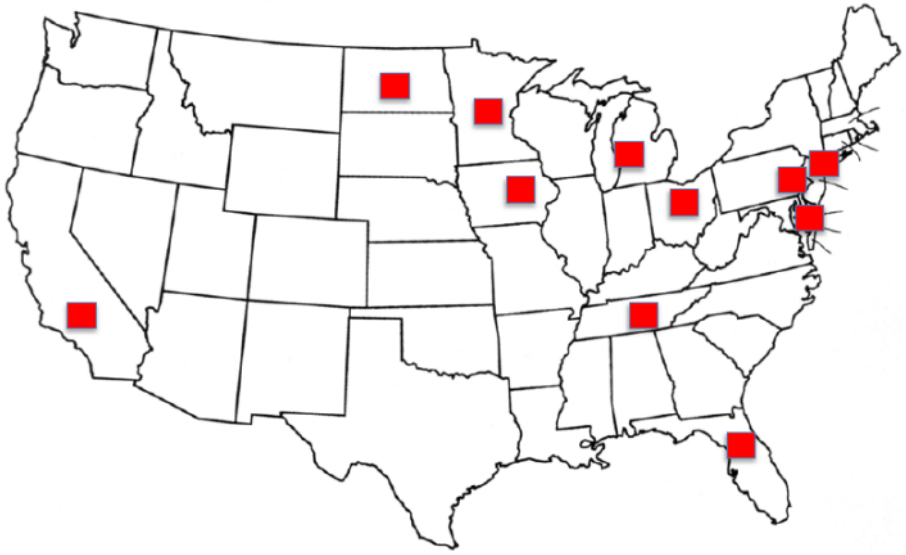

150'den fazla vaka

İsviçre

Almanya

Fransa

İspanya

Hollanda

İngiltere

İrlanda

Hong Kong

Avusturalya

Kanada

A.B.D.

Isıtıcı-Soğutucu Cihazlar (Heater-Cooler Devices)

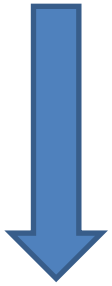

KARDİYOVASKÜLER CERRAHİNİN OLMAZSA OLMAZI

Isıtıcı-Soğutucu Cihazlar Nerede Kullanılır?

- Kalp kapak cerrahisi
- Koroner arter baypass cerrahisi
- Kalp, akciğer, karaciğer transplantasyonu
- Ekstrakorporyel membran oksijenasyonu (ECMO)
- Sol ventrikül destek cihazı implantasyonu (LVAD)
- Aort, pulmoner arter cerrahisi
- Akciğer rezeksiyonu
- **Hipertermik intraperitoneal kemoterapi (HIPEC)**

ISITICI SOĞUTUCU CİHAZ

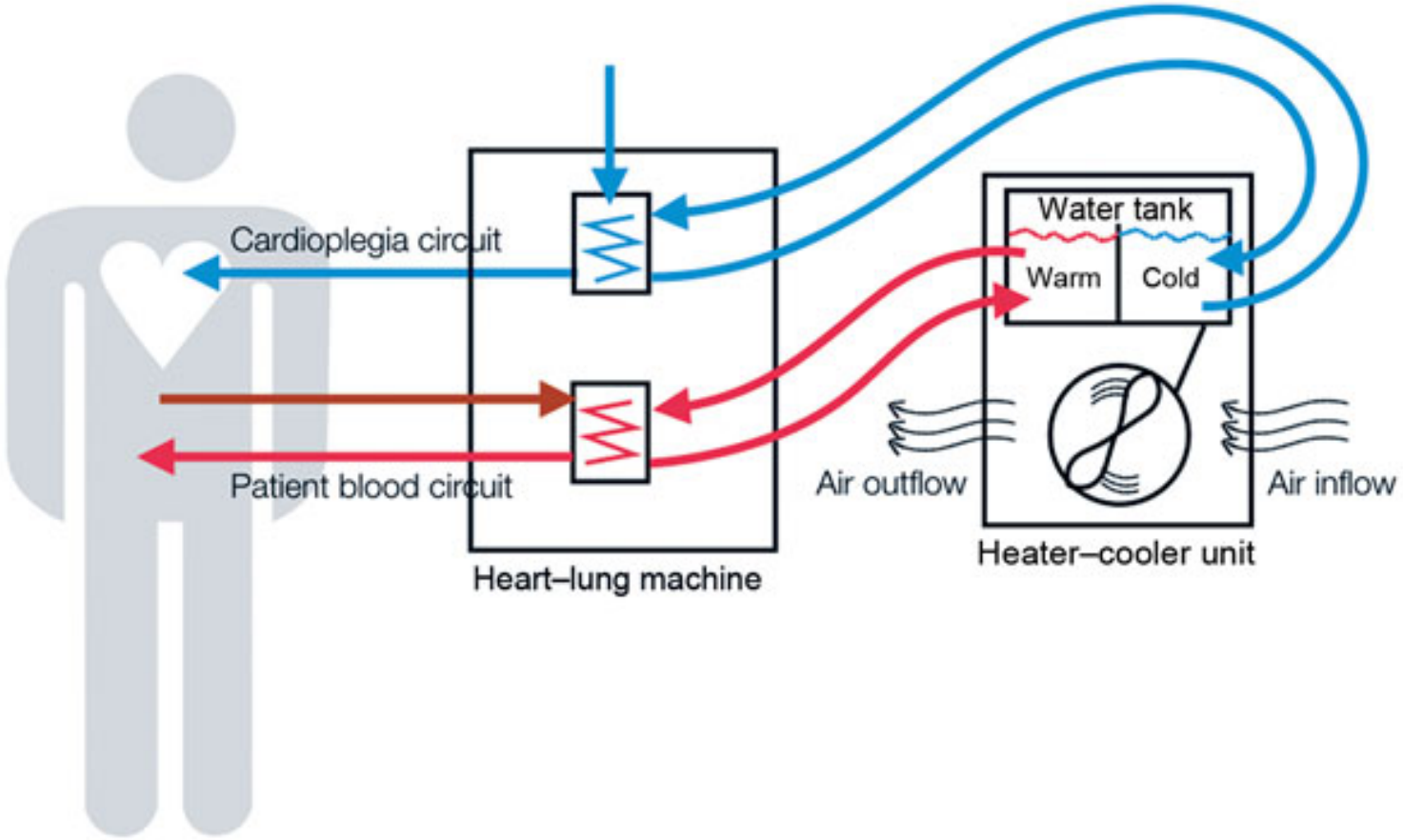

Uyarı

TANK VACUUM
STOCKERT
40.8
41.0
NITEST

HCD'den *Mycobacterium chimaera* Bulaşması

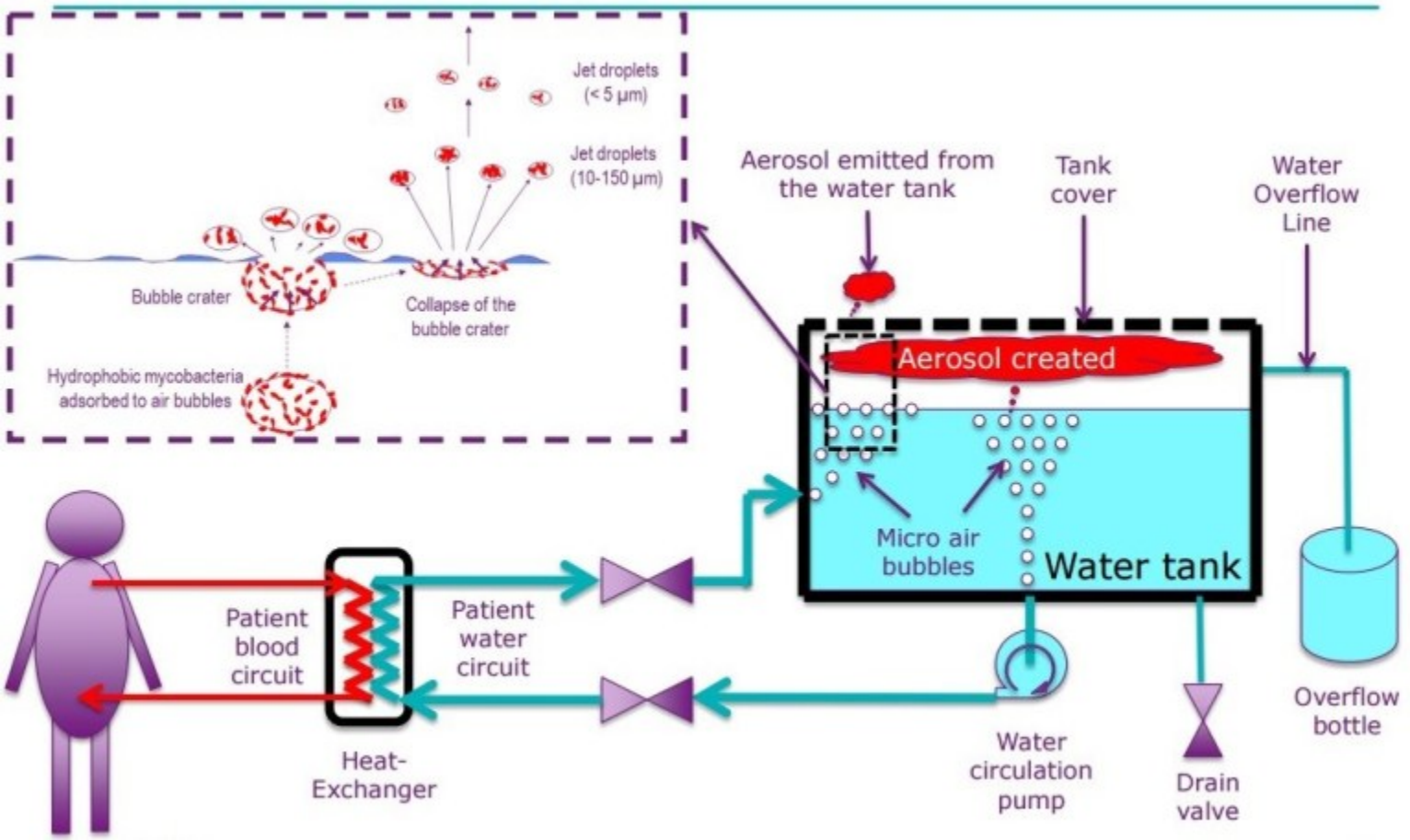

RESEARCH

Transmission of *Mycobacterium chimaera* from Heater–Cooler Units during Cardiac Surgery despite an Ultraclean Air Ventilation System

Rami Sommerstein, Christian Rüegg, Philipp Kohler, Guido Bloemberg, Stefan P. Kuster, Hugo Sax

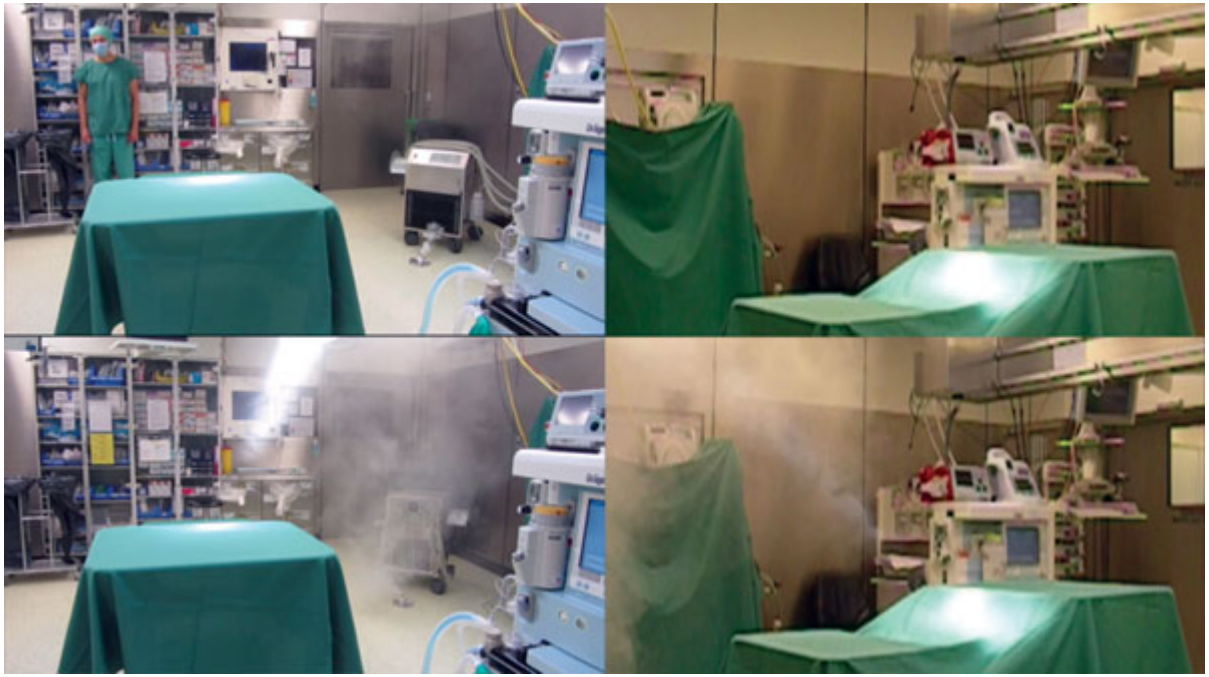

- Ameliyathanede ultrafiltrasyona rağmen kontamine cihazlardan cerrahi bölgeye *M.chimaera* bulaşması, 23 sn de
- 5 metreye kadar kontaminasyon

Figure 5. Presence of extensive biofilm on materials in the water tanks of the LivaNova PLC, Sorin 3T heater-cooler unit, studied at Public Health England, Porton Down.

Biofilm present on insulation material and steel piping in the hot water tank.

Figure 2. Two overflow pipes which can be used to vary the volume of water in LivaNova 3T HCU tanks. The lower pipe takes the overflow (and visible debris) from the tank to the overflow bottle that is attached to the rear of the HCU. The upper pipe is blocked at the top and contains stagnant water, biofilm and debris.



Figure 3. Location of the gaps in the water tank top plates that contributed to the release of aerosols from the heater-cooler unit studied by Public Health England, Porton Down.

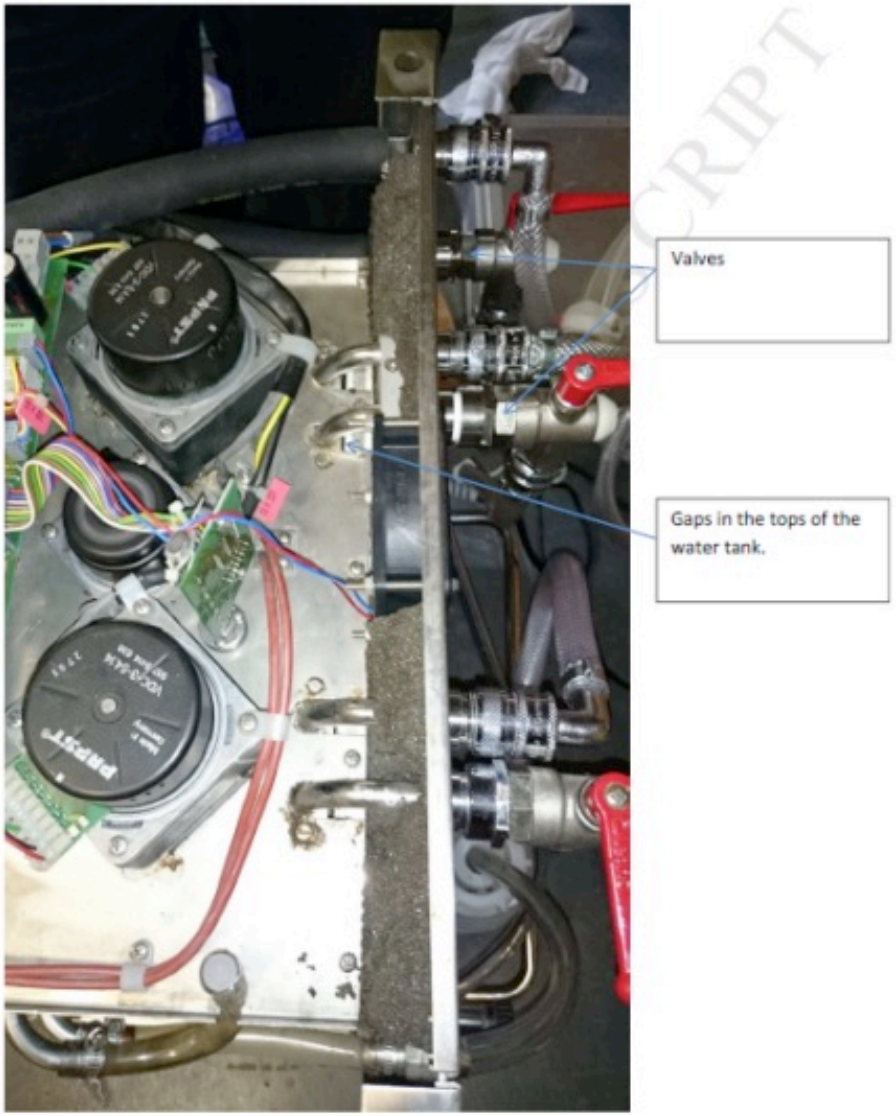



Figure 1. Holes (highlighted by the red circles) close to the flow and return pipes of both heater-cooler circuits and gap between tank sealing plates identified by an aerodynamic particle sizer as areas of aerosol release.

Figure 4a. Use of a smoke pen to visualise air flow path as it is extracted from the pumps/gaps associated with the water tanks and exiting the heater-cooler unit via the rear fan.



KLİNİK

M.chimaera Enfeksiyonları

- Cerrahi alan enfeksiyonları(CAİ)
  - Yüzeyel CAİ, sternal osteomyelit, mediastinit,abse
- Protez kapak endokarditi
- Vasküler greft enfeksiyonu
- Sol ventrikül destek cihazı enfeksiyonları

- Dissemine Enfeksiyon
  - Kemik iliği (pansitopeni) tutulumu
  - Splenomegali
  - Hepatit
  - Nefrit
  - Artrit, osteomyelit(Diskit)
  - Pnömoni
  - Myokardit
  - Ensefalit

Surgical procedure

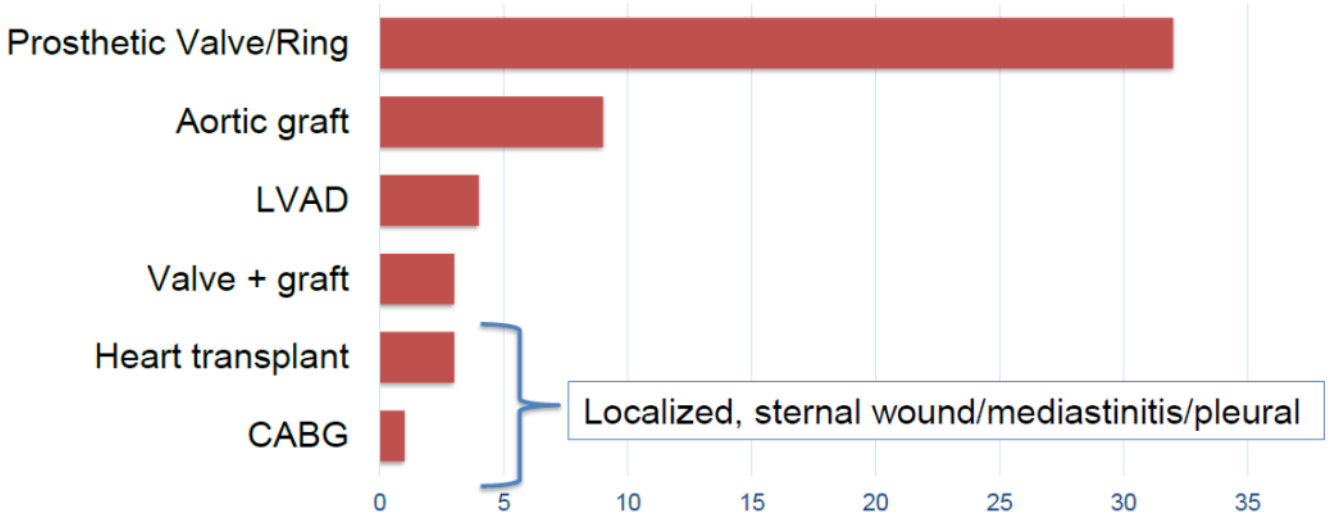

Appenheimer AB et al. IDWeek 2016, #2392, October 29, 2016.
Chand M, et al. Clin Infect Dis 2017;64:335-42.
Kohler P, et al. European Heart Journal 2015;36:2745-53.

Is Mycobacterium chimaera Infection After Cardiac Surgery a Risk Factor for Bacterial Prosthetic Valve Endocarditis?

- Mart 2019-75 yaş erkek hasta
- 6 aydır ateş, şuur bulanıklığı
- 2016 aort replasmanı
- TEE: Biyoprotezde vejetasyon, kaçak
- Kan kültürü (+ mikobakteriyel)
- Kan kültürü: enterokok
- Tedavinin 2. haftası mikobakteriyel kültür pozitif

Inojosa et al. Is Mycobacterium chimaera infection after cardiac surgery a risk factor for bacterial prosthetic valve endocarditis? Clin Infect Dis. 2019 Jun 20

Is Mycobacterium chimaera Infection After Cardiac Surgery a Risk Factor for Bacterial Prosthetic Valve Endocarditis?

Table 1. Clinical Features and Timing

Case	Sex/Age	Cardiac Surgery	Surgery	Bacterial Endocarditis Diagnosis	*Mycobacterium chimaera* Infection Diagnosis	Clinical Syndromes
1	M 37	cARR	12/2012		09/2016	PVE, AAP, DI
2	M 60	AVR + MVA	01/2013	*Staphylococcus aureus*; 05/2016	06/2016	PVE
3	M 42	AVR + ARR	05/2015		11/2016	PVE, AAP, DI
4	M 75	AVR	02/2011	*Staphylococcus epidermidis*; 06/2016	01/2017	PVE, DI, SD
5	M 80	MVR + AW	03/2016		09/2018	PVE, SD
6	M 56	AVR ARR	06/2016 05/2015		10/2018	PVE, DI, SD
7	M 75	AVR	11/2016	*Enterococcus faecalis*; 03/2019	04/2019	PVE

Abbreviations: AAP, ascending aortic pseudoneurysm; ARR, aortic root replacement; AVR, aortic valve replacement; AW, ascending aortic wrapping; cARR, composite aortic root replacement; DI, disseminated infection; MVA, mitral valve annuloplasty; PVE, prosthetic valve endocarditis; SD, spondylodiscitis.

Inojosa et al. Is Mycobacterium chimaera infection after cardiac surgery a risk factor for bacterial prosthetic valve endocarditis? Clin Infect Dis. 2019 Jun 20

Case report

Mycobacterium chimaera infection masquerading as a lung mass in a healthcare worker

Christian I. Rosero[1,*], Wael E. Shams[2,3]

C.I. Rosero, W.E. Shams / IDCases 15 (2019) e00526

A B S T R A C T

Mycobacterium chimaera, a nontuberculous mycobacterium, is a member of the *Mycobacterium avium* complex (MAC). This microorganism has recently gained significant notoriety for its association with outbreaks in patients exposed to contaminated heater–cooler devices used during open heart surgeries.

We report a case of *Mycobacterium chimaera* pulmonary infection in a healthcare worker who presented with cough, low grade fever and weight loss with evidence of a lung mass that was initially thought to be a tumor on CT scan imaging. The patient underwent partial left lung lobectomy and pathology revealed necrotizing granulomas with acid fast bacilli and a culture grew *M. chimaera*. The patient received combination antimycobacterial therapy according to susceptibility results for twelve months with complete resolution of his symptoms and radiographic findings.

Infection Control investigation could not find a source of infection in the hospital where he worked during the last ten years. However, the patient rotated in different hospitals before coming to work at this facility and assisted in surgeries in several operating rooms where the heater-cooler devices in question were used.

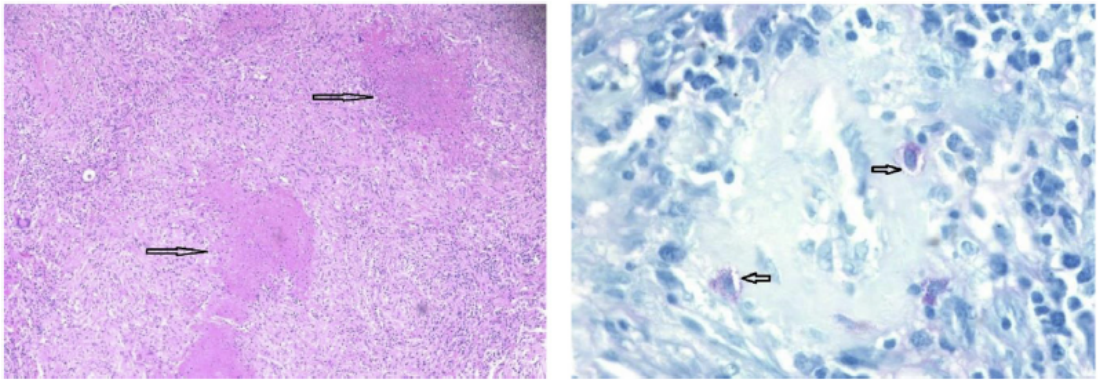

Fig. 2. *Left;* Lung Mass Tissue Biopsy with H&E stain showing necrotizing granuloma is present on a fibrotic background. *Right;* Lung Mass Tissue Biopsy with AFB stain, showing Acid fast bacilli present within scattered histiocytes.

Table 1. Clinical experience for 52 reported cases of HCD-associated *M. chimaera* [7,10,13].

Patient characteristics	Results
Total number of cases	52
Earliest sentinel surgery	2008
Male (N, %)	43 (83)
Age, years (mean, range)	60 (1-83)
Duration from surgery to clinical presentation in months (mean, range)	17 (1-72)
Sites of index positive culture (N*)	

Marra et al.Mycobacterium chimaera infections associated with contaminated heater-cooler devices for cardiac surgery: Outbreak Management. Clin Infect Dis. 2017 Aug 15;65(4):669-674.

Mycobacterium chimaera Klinik Bulgular

Semptomların tipi	Klinik semptom
Konstütüsyonel	Tekrarlayan veya uzamış ateş, yorgunluk, nefes darlığı, kilo kaybı, gece terlemesi
Kardiyak	Protez kapak endokarditi ve veya protez vasküler greft enfeskiyonu
İmmunolojik	Splenomegali, sitopeni
İnfant	Ateş, gelişme geriliği
Ekstrakardiyak	Kemik,cerrahi alan enfeksiyonu, mediyastinit, hepatit, kan dolaşımı enfeksiyonu, oküler bulgular (panüveit, multifokal koroidit, koryoretinit)

Multimodal imaging of choroidal lesions in disseminated mycobacterium chimaera infection after cardiothoracic surgery

Böni, Christian; Al-Sheikh, Mayss; Hasse, Barbara; Eberhard, Roman; Kohler, Philipp; Hasler, Pascal W; Erb, Stefan; Hoffmann, Matthias; Barthelmes, Daniel; Zweifel, Sandrine A

- 9 hasta- endokardit veya aort greft enfeksiyonu
- Dört hastada inaktif lezyon (hafif hastalık)
- Beş hastada progresif oküler hastalık
- Bir göz- büyük koroidal granülom –koroidal neovaskülarizasyon

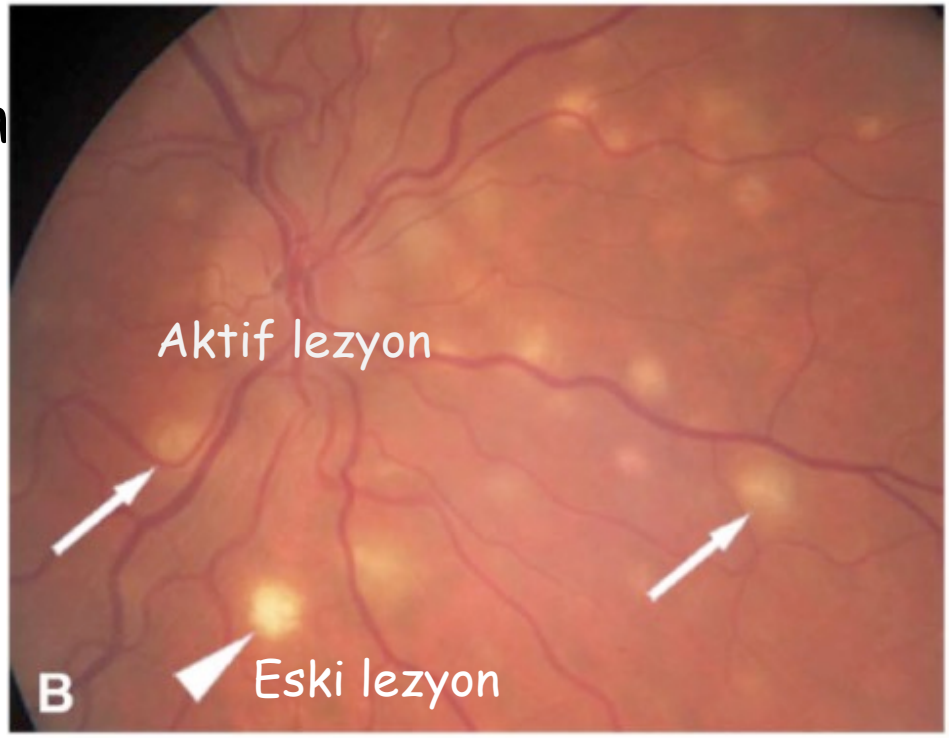

Retina. 2019 Mar;39(3):452-464

Tanı

- Kan kültürü (En az 3 şişe mikobakteri kültürü)

  Nedeni bilinmeyen ateş devamında aylık kültür tekrarı
- Balgam, idrar veya tutulan organ doku kültürü
- Sitopeni varsa kemik iliği biyopsisi- kültür
- PCR (100 cfu/ml bile saptayabilir)

Kasperbauer, DaleyMycobacterium chimaera Infections Related to the Heater-Cooler Unit Outbreak: A Guide to Diagnosis and Management
.Clin Infect Dis. 2019 Mar 19;68(7):1244-1250

Tanı

- Histopatolojik inceleme (Parafin emdirilmiş formalin ile fixe edilmiş doku örneği) : Non-kazeifiye, nadiren aside dirençli boyanma
- Koryoretinit açısından göz dibi muayenesi
- Endokardit açısından TEE
- PET-CT(Özellikle nedeni bilimeyen ateş ve vasküler greft enfeksiyonlarında)

Kasperbauer SH, Daley CLMycobacterium chimaera Infections Related to the Heater-Cooler Unit Outbreak: A Guide to Diagnosis and Management. Clin Infect Dis. 2019 Mar 19;68(7):1244-1250

Tedavi

- Makrolid
- Etambutol
- Rifabutin
- Moksifloksasin
- Amikasin IV

Kombinasyon tedavi

- Optimal süre belirsiz
- Cerrahi çıkarımdan sonra en az 1 yıl
- İnfekte yabancı doku varsa hayat boyu supresyon tedavisi

Kasperbauer SH, Daley CLMycobacterium chimaera Infections Related to the Heater-Cooler Unit Outbreak: A Guide to Diagnosis and Management. Clin Infect Dis. 2019 Mar 19;68(7):1244-1250

Cerrahi Tedavi

- AHA kılavuzu dirençli suşlara bağlı endokarditte cerrahi önermektedir
- Agresif medikal tedaviye relaps ve multifokal yayılım
- Eko normal,cerrahi esnasında patolojik bulgu
- Dissemine enfeksiyonda yabancı materyalin çıkarılması veya değişimi

Kasperbauer, DaleyMycobacterium chimaera Infections Related to the Heater-Cooler Unit Outbreak: A Guide to Diagnosis and Management.Clin Infect Dis. 2019 Mar 19;68(7):1244-1250

- Cerrahi için hastaların çoğu ağır hasta veya yüksek riskli
- Yeni cihazın enfekte olma riski bilinmemekte

Marra et al.Mycobacterium chimaera infections associated with contaminated heater-cooler devices for cardiac surgery: Outbreak Management. Clin Infect Dis. 2017 Aug 15;65(4):669-674.

Cerrahi Tedavi

- Optimal zaman belirsiz
- Oral ve IV tedavi en az 4-6 hafta sonra
- Parenteral Amikasin cerrahi sonrası en az 1 ay devamı
- Lokalize yara enfeksiyonunda da cerrahi debridman

Kasperbauer, DaleyMycobacterium chimaera Infections Related to the Heater-Cooler Unit Outbreak: A Guide to Diagnosis and Management.Clin Infect Dis. 2019 Mar 19;68(7):1244-1250

- Mortalite oranı %50 civarında
- Sağ kalan hastalar lokalize enfeksiyon, debridman + antibiyotik tedavi
- Dissemine seyirli hastalarda kür belirsiz
- Daha fazla çalışmaya ihtiyaç var

Marra et al.Mycobacterium chimaera infections associated with contaminated heater-cooler devices for cardiac surgery: Outbreak Management. Clin Infect Dis. 2017 Aug 15;65(4):669-674.

Salgın Yönetimi Aşamaları

- 1-Riskli Hastaları Belirleme
- 2-Olguların saptanması ve İletişim Kurulması
- 3-Olguların Değerlendirilmesi
- 4-Bulaş Riskinin Azaltılması

Marra et al.Mycobacterium chimaera infections associated with contaminated heater-cooler devices for cardiac surgery: Outbreak Management. Clin Infect Dis. 2017 Aug 15;65(4):669-674.

1- Riskli Hastaları Belirleme

- Liva Nova 3T Isıtıcı-Soğutucu ile opere olan tüm hastalar risk altında
- 2006 yılından beri kullanılmakta
- ABD'de tüm cihazların %60'ı
- Operasyon 200.000 /yıl
- FDA temizlik-dezenfeksiyon prosedüründe değişiklik – Eylül 2014
- Ancak yine de testler pozitif

Marra et al.Mycobacterium chimaera infections associated with contaminated heater-cooler devices for cardiac surgery: Outbreak Management. Clin Infect Dis. 2017 Aug 15;65(4):669-674.

- Vaka saptanan merkezde 1/100-1/1000 tahmini vaka
- Cerrahi türü,
- Dezenfeksiyon protokolü,
- Cihazın ameliyat odasındaki konumuna göre değişir

Marra et al.Mycobacterium chimaera infections associated with contaminated heater-cooler devices for cardiac surgery: Outbreak Management. Clin Infect Dis. 2017 Aug 15;65(4):669-674.

- 2 saatten uzun kardiyopulmoner baypass risk yüksek

Lyman et al. Invasive nontuberculous mycobacteria infections among cardiothoracic surgery patients - Hospital A, Pennsylvania, 2010-2015. 65th Annual Epidemic Intelligence Service (EIS) Conference. 2016

2-Olguların saptanması ve İletişim Kurulması

- Maruz kalan hasta listesi
- Cihazın ilk kullanımı 2006
- Salgın ile ilişkili ilk cerrahi 2008
- Enfeksiyon gelişimi 4 yıl içinde
- CDC 12.02.2017: Ocak 2012 'ye kadar tarama

(Ancak en uzun cerrahi-enfeksiyon arası 6 yıl)

Marra et al.Mycobacterium chimaera infections associated with contaminated heater-cooler devices for cardiac surgery: Outbreak Management. Clin Infect Dis. 2017 Aug 15;65(4):669-674.

2-Olguların saptanması ve İletişim Kurulması

- Hastalarla iletişim (mektup/telefon)

University of Iowa News Release

February 2, 2016

UI Hospital and Clinics notifies patients of infection risk

Safe and high quality care is the top priority for University of Iowa Hospitals and Clinics in Iowa City. Hospital leaders recently began notifying about 1,500 patients of possible exposure to a bacterium during certain major surgeries that took place between January 1, 2012, and January 22, 2016.

The very low risk of infection has been limited to patients who underwent certain major heart, lung or liver surgeries within the past four years. The issue only affects those patients who have undergone surgery that involves the use of heart-lung bypass machines with heater-cooler systems.

Patients who had other procedures - such as stents, pacemakers, defibrillators, ablations, biopsies and other surgeries - are not at risk.

The bacterium - Nontuberculous Mycobacterium, (NTM) - is commonly found in nature, including soil, water, and even tap water. Although it typically is not harmful, it can cause infections in rare cases.

2-Olguların saptanması ve İletişim Kurulması

- Basın bültenleri
- Web sayfası- FDA ve CDC materyallerine, sık sorularla bağlantılı
- Klinisyen bildirimi
- CDC toolkit

2-Olguların saptanması ve İletişim Kurulması

- Laboratuvar kayıtları
- Sarkoidoz tanısı alan hastalar
- Medikal kayıt alarm sistemi

2-Olguların saptanması ve İletişim Kurulması

- Cerrahi sonrası uzun süre takip olmaması,
- Nonspesifik semptomlar,
- İnkübasyon süresi uzun,
- Mikobakteri kültürleri immunkompetan hastalarda nadir istenmesi olgu bulmayı zorlaştırır.

LATE BREAKER ABSTRACTS

2392. *Mycobacterium chimaera* Outbreak Response: Experience From Four United States Healthcare Systems

A. Ben Appenheimer, MD[1]; Daniel J. Diekema, MD, FIDSA, FSHEA[1]; Dorine Berriel-

- Pensilvanya, Floridai Iowa,Kolarado- 7 merkez
- 28.07.2016: 24 vaka
- Isıtıcı-soğutucu cihaz kullanımı olan merkezlerde vaka bulma çalışması
- Laboratuvar kayıtları, medikal kayıtlar, bilgilendirme
- 9917 maruz kalan hasta
- 1672 değerlendirme
- 1300 mikobakteri kültürü
- Saptanan şüpheli hasta sayısı 8
- Dört hasta kayıtlardan, gerisi hekim bilgilendirmesinden

3-Şüpheli Vaka Değerlendirme

Kültür negatif

- İnfektif endokardit
- Vasküler greft infesiyonları
- Mediastinit
- Dissemine enfeksiyon
- Yorgunluk, kilo kaybı,ateş,

gece terlemesi, eklem veya kas ağrısı

İki veya üç Mikobakteriyel kan kültürü

3-Şüpheli Vaka Değerlendirme

- Mikobakteriyel kültürler negatif

- Kemik iliği ve diğer etkilenen organlar kültür ve histopatolojik değerlendime
- Kan kültür tekrarı 1-2 ay içinde

4-Bulaş Riskinin Azaltılması

- Isıtıcı soğutucu cihazın operasyon odasından çıkarılması
- Çoğu merkez için oldukça zor
- En etkin yöntem

Isıtıcı Soğutucu Cihazı Operasyon Odası Dışına Çıkarılması



Henderson et al. M.chimaera- the challenges for infection prevention and controlInfection, Disease & Health (2018) 23, 243e245.

Walker et al. A review of the microbiological problems and biofilms associated with *Mycobacterium chimaera* in heater cooler units used for cardiopulmonary bypass. J Hosp Infect. 2017 Jul;96(3):209-220.

Isıtıcı Soğutucu Cihazı Operasyon Odası Dışına Çıkarılması

Figure 1

Marra et al.Mycobacterium chimaera infections associated with contaminated heater-cooler devices for cardiac surgery: Outbreak Management. Clin Infect Dis. 2017 Aug 15;65(4):669-674.

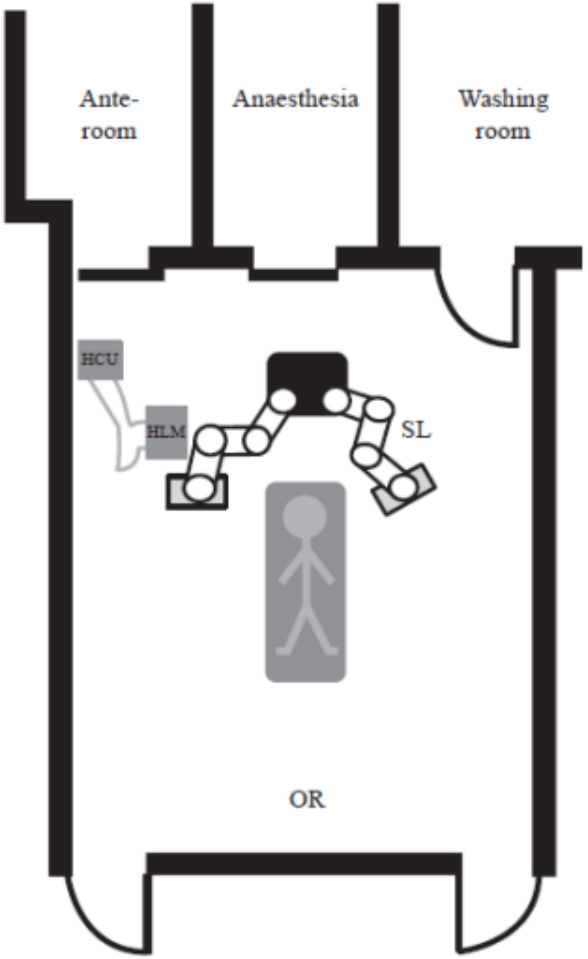

Figure 1. Placement of the heater–cooler unit (HCU) inside the operating room (OR). HLM, heart–lung machine; SL, surgical lights.

- Hava ve su örnekleri
- Cihaz açıkken üreme
- **Kapı tam kapalı olmadığında havada *M. chimaera* saptanmakta**
- Non-fermenter bakteriler

Götting et al. Heaterecooler units: contamination of crucial devices in cardiothoracic surgery. J Hosp Infect. 2016 Jul;93(3):223-8.

Cihaz İçin Özel Yapılmış Çelik Kutu



Figure 1. Custom-made stainless steel housing for heater–cooler units (model 3T; Sorin [now LivaNova, London, UK]) used at the University Hospital Zurich, Zurich, Switzerland. A) Front view shows the fine dust filter F7 over the air inlet (arrow). B) Side view shows the half-open back door with the rectangular opening (arrow), through which a duct connects the housing to the operating room ventilation exit. The negative pressure of the operating room ventilation system generates the necessary airflow.

Shreiber et aReemergence of *Mycobacterium chimaera* in Heater-Cooler Units despite Intensified Cleaning and Disinfection Protocol. Emerg Infect Dis. 2016 Oct;22(10):1830-3.
I.



Cihazın hastaya dönük olmaması
Risk devam etmektedir. Önerilmez

pascals
0
20
40
60
80
100
TANK VACUUM
CALIBRATED FOR
VERTICAL POSITION
MAX. PRESSURE 100 kPa
DWYER INSTRUMENTS, INC.
MICH. CITY, IND. 46360 U.S.A.
CAUTION

Hasta
Devresi 2
Hasta
Devresi 1
1/2 x 3/32
1/2 x 3/32

Yeni Duvar Su Sistemi



Matte et al. A Novel Wall Water System for Cardiopulmonary Bypass May Reduce the Risk of Aerosolized Infection. The Journal of Thoracic and Cardiovascular Surgery, 156(1), 318–324

Isıtıcı Soğutucu Cihazın Dezenfeksiyonu

- Dezenfektanlara direnç ve biyofilm oluşumu dezenfeksiyonu zorlaştırır
- Hatta imkansızlaştırır
- Biyofilmi azaltabilir

Dezenfeksiyon İşlemi

- Üretici firmaların önerdiği bakım, dezenfeksiyon yapılmalı
- Su devrelerinin dezenfeksiyonu : İlk kullanımda ve 14 günde bir

Filtre edilmiş (0.2 µm) su + Colorox Regular Bleach (%8.25'lik Sodyum hipoklorid) veya Minncare Cold Sterilant (perasetik asit)

- Su değişimi : 7 günde bir- Filtre edilmiş su + 150 ml %3'lük H2O2

Şimşek et al.Açık Kalp Cerrahisi ve M.chimaera. Klimik 2017;30(2):49-58

LivaNova Implements 3T Heater-Cooler Device Modification

London, August 7, 2017 – LivaNova PLC (NASDAQ:LIVN) (together with its subsidiaries as "LivaNova" or the "Company"), a market-leading medical technology company, today announced the implementation of a device modification to its existing 3T Heater-Cooler devices in Western Europe. During the past fiscal quarter, LivaNova successfully completed verification and validation processes, which allowed the Company to obtain CE Mark for its 3T Heater-Cooler device modification. It began implementing upgrades in Europe and implementation will extend to other regions as local regulatory approvals are received. The modification, which is being implemented at no cost to customers, includes the installation of an internal sealing and vacuum system on existing devices. This addresses regulatory actions and is designed to mitigate the potential for *Mycobacterium chimaera (M. chimaera)* contamination in open-heart surgery patients.

ABD Gıda ve İlaç Dairesi (FDA)

- Eylül 2014'ten önce üretilmiş cihaz varsa
- Üretici firma, enfeksiyon riskini azaltılmaya yönelik stratejiler oluşturana kadar, cihazların açık kalp cerrahisinde kullanılmamalı
- Kullanılması gerekli ise sadece acil ve/veya hayatı tehdit edin durumlarda ve başka bir cihazın olmaması halinde düşünülmeli
- Cihazın egzozu ameliyat masasından uzak bir noktaya, mesela ameliyathane egzozuna yönlendirilmeli

Avusturalya *M.chimaera*

- 16.04.2019 itibari ile 9 hasta-2 ölüm
- Eylül 2014 öncesi üretilen kontamine cihaz,
- 27.10.2017: Vakum ve sızdırmazlığı iyileştirmek için ürün düzeltme çağrısı
- 03.02.2017 Ulusal Enfeksiyon Kontrol Kılavuzu

Avusturalya

Which open-heart surgery patients need to be aware of this risk?

Patients who had open-heart surgery at the following locations and in the time periods listed:

	Hospital	Period of Exposure Concern
NSW Public	Children's Hospital Westmead	January 2012 - August 2016
	Prince of Wales Hospital	January 2012 - August 2016
	St George Hospital	January 2012 - April 2018 *
	Sydney Children's Hospital (Randwick)	January 2012 - August 2016
NSW Private	Newcastle Private Hospital	July 2014 - September 2016
	Norwest Private Hospital	January 2012 - August 2016
	Prince of Wales Private Hospital	January 2012 - August 2016
	St George Private Hospital	January 2012 - January 2017
	The Sydney Adventist Hospital (Wahroonga)	22 January 2015 - 18 June 2015
	Westmead Private Hospital	June 2014 - August 2016
ACT	National Capital Private Hospital	November 2011 - August 2016
	Canberra Hospital	July 2014 - November 2016

* The period of concern was extended for St George Hospital patients following the identification of a second contaminated heater-cooler device in April 2018.

2006-2016 yılları
5650 hasta- bilgilendirme mektubu

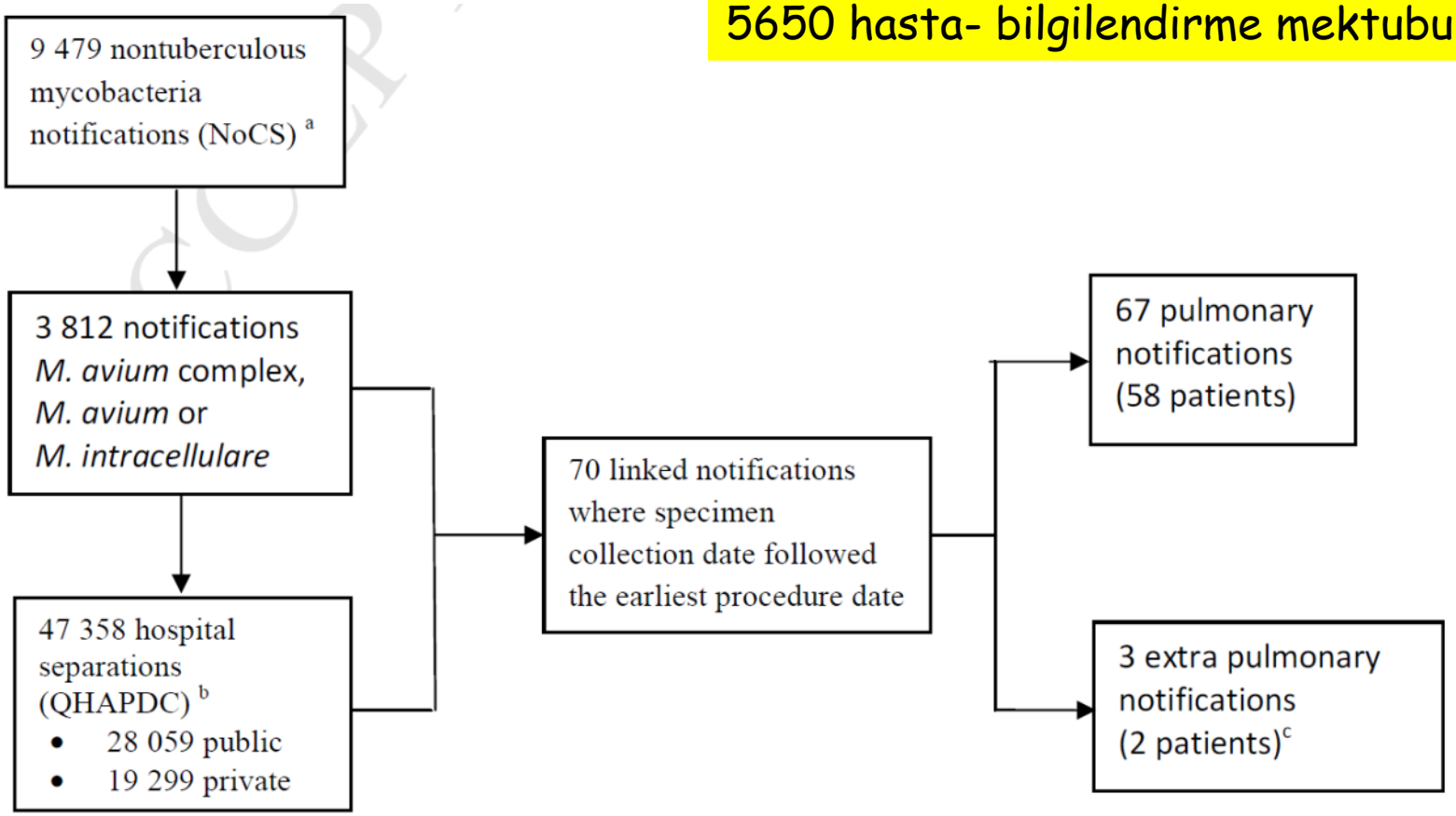

in

Bir hasta daha önce bildirimi yapılmış hasta
Diğeri M.chimaera. Salgın suşu değil

Robertson at al. Responding to *Mycobacterium chimaera* heater cooler unit contamination, International and national inter-sectoral collaboration coordinated in the state of Queensland, Australia. J Hosp Infect. 2018 Nov;100(3):e77-e84

İngiltere

- 17.09.2019 itibari ile 45 vaka- 25 ölüm

Public Health England

NHS England

Mycobacterium chimaera Infections Associated with Cardiopulmonary Bypass

Information for general practice

Infections Associated with Heater Cooler Units Used in Cardiopulmonary Bypass and ECMO

Information for healthcare providers in the UK

Açık Kalp Cerrahisi Uygulanmış Hastalarda Kontamine Isıtıcı-Soğutucu Cihazlarla İlişkili *Mycobacterium chimaera* İnfeksiyonları: Küresel Bir Salgın

Mycobacterium chimaera *Infections Associated With Contaminated Heater-Cooler Devices Among Open Cardiac Surgery Patients: A Global Outbreak*

Serap Şimşek-Yavuz
İstanbul Üniversitesi, İstanbul Tıp Fakültesi, İnfeksiyon Hastalıkları ve Klinik Mikrobiyoloji Anabilim Dalı, İstanbul, Türkiye

Mycobacterium chimaera ya da Likya'nın Sönmeyen Ateşi

Mycobacterium chimaera *or the Quenchless Fire of Lycia*

Haluk Eraksoy
İstanbul Üniversitesi, İstanbul Tıp Fakültesi, İnfeksiyon Hastalıkları ve Klinik Mikrobiyoloji Anabilim Dalı, İstanbul

ANNALS OF CLINICAL MICROBIOLOGY AND ANTIMICROBIALS

RESEARCH Open Access

Distribution of Nontuberculous Mycobacteria strains

Murat Gunaydin[1*], Keramettin Yanik[1], Cafer Eroglu[1], Ahmet Sanic[2], Ismail Ceyhan[3], Zayre Erturan[4] and Riza Durmaz[5]

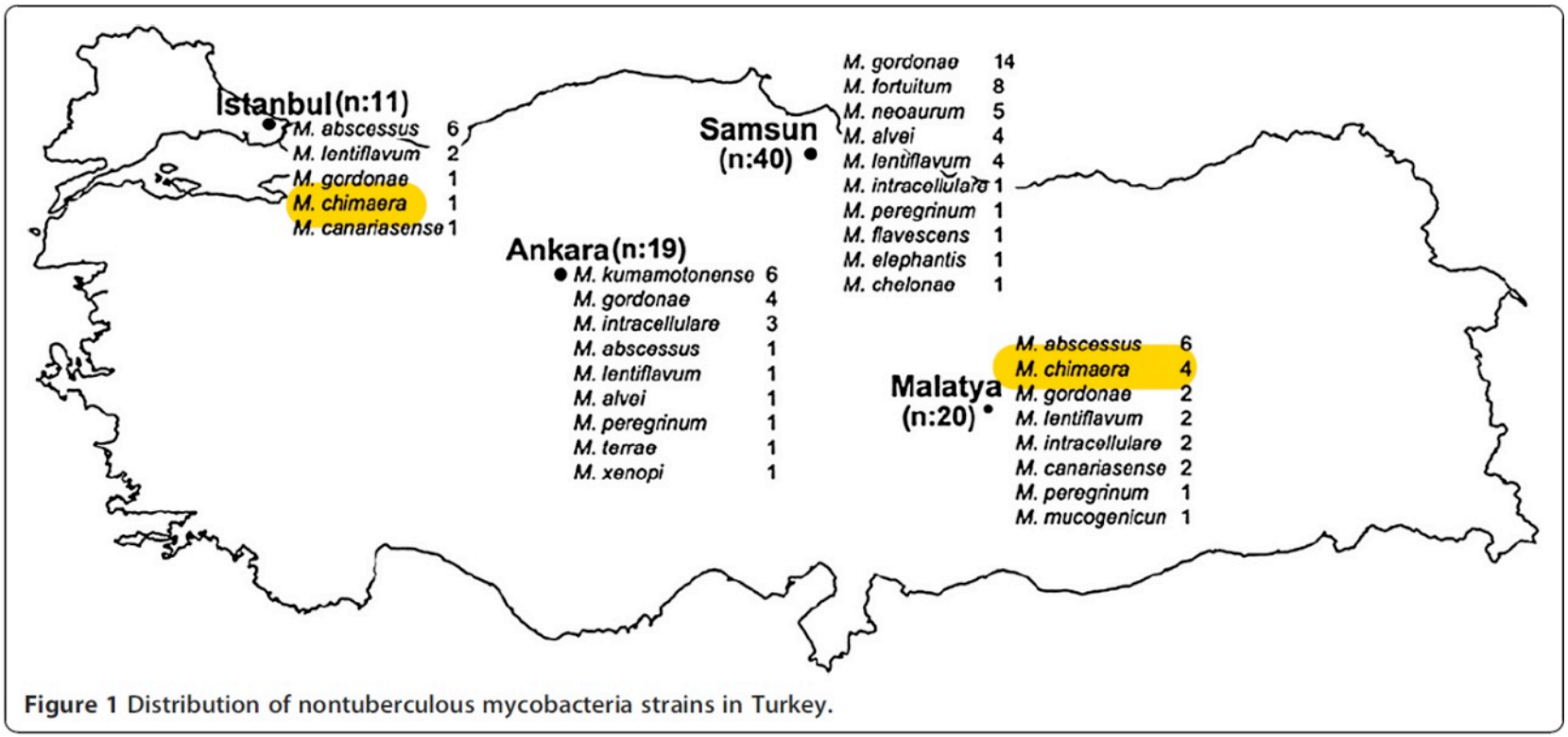

Figure 1 Distribution of nontuberculous mycobacteria strains in Turkey.

MYCOBACTERIUM CHIMAERA INFECTIONS AFTER CARDIOVASCULAR SURGERY: LESSONS FROM A GLOBAL OUTBREAK

DANIEL J. DIEKEMA, MD

- Su ile çalışan, fanlı cihazların enfeksiyon kontrol açısından değerlendirilmesi
- Moleküler yöntemlere ulaşılabilirlik

Trans Am Clin Climatol Assoc. 2019; 130: 136–144.

Aklımızda Kalması Gerekenler

- Kalp cerrahisinde kullanılan üretim esnasında kontamine olmuş Stockert 3T Isıtıcı Soğutucu Cihazlardan salınan biyoaerosollerle küresel bir *M.chimaera* salgını mevut
- Tüm cihazlar kontamine kabul edilmeli- operasyon odasından uzaklaştırılmalı
- Bulaşı önlemek için tedbirler
- Tanısı zor, üreme zamanı uzun, tedavi başarısı şüpheli,mortalite yüksek
- Ulusal *M.chimaera* önleme stratejisi belirlenmeli

HER GÖRDÜĞÜN SUYU TEMİZ SANMA!!!!

Ünsüz düşünür

MAJOR ARTICLE

Prolonged Outbreak of *Mycobacterium chimaera* Infection After Open-Chest Heart Surgery

Hugo Sax,[1,a] Guido Bloemberg,[2,a] Barbara Hasse,[1,a] Rami Sommerstein,[1] Philipp Kohler,[1] Yvonne Achermann,[1] Matthias Rössle,[3] Volkmar Falk,[4] Stefan P. Kuster,[1] Erik C. Böttger,[2,b] and Rainer Weber[1,b]

[1]Division of Infectious Diseases and Hospital Epidemiology, University Hospital Zurich, [2]Institute of Medical Microbiology, National Centre for Mycobacteria, University of Zurich, [3]Institute of Surgical Pathology, and [4]Division of Cardiac Surgery, University Hospital Zurich, Switzerland

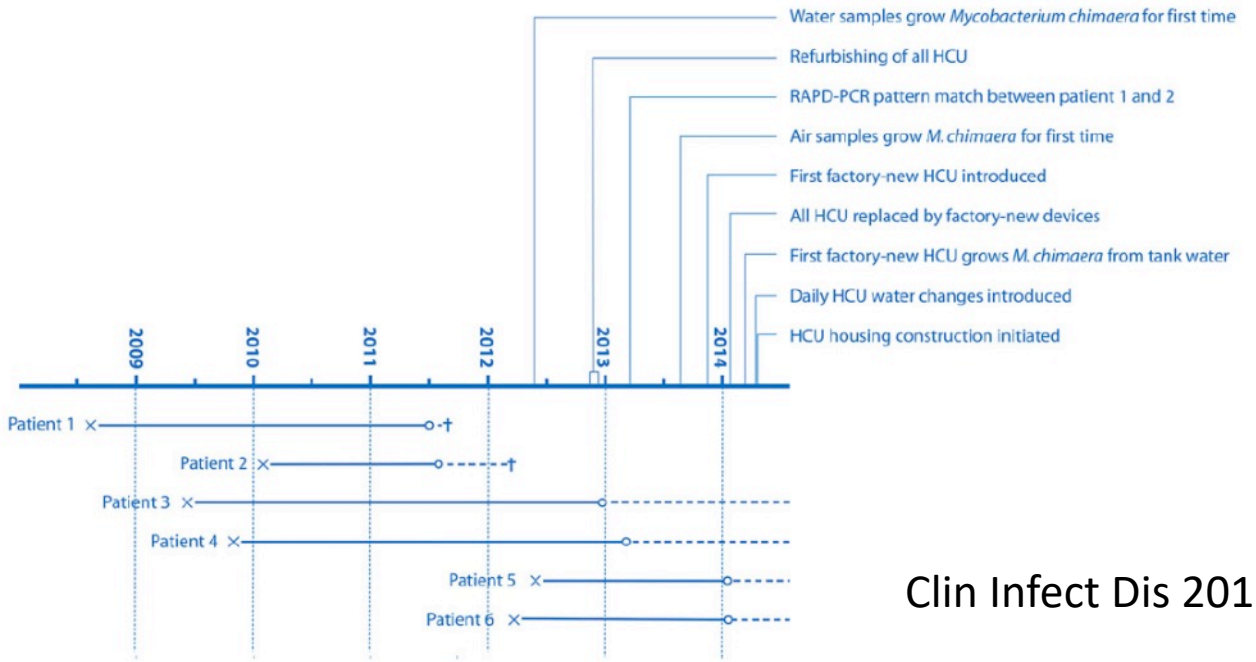

Clin Infect Dis 2015 (July 1);61:67

Figure 1. Evolution of the 6 cases of *Mycobacterium chimaera* infection and investigational activity. Abbreviations: x, open-chest heart surgery; ○, *M. chimaera* diagnosis; ---, antibiotic and, in some cases surgical, treatment; +, fatality; HCU, heater-cooler unit; RAPD-PCR, randomly amplified polymorphic DNA polymerase chain reaction.