

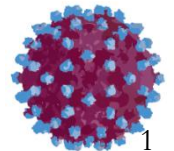
# DELTA HEPATİTİ

## “Olgu Sunumu”

Dr. Oya Eren Kutsoylu  
DEÜTF Enfeksiyon Hastalıkları ve  
Klinik Mikrobiyoloji AD


---

25.01.2015, KLİMİK Hepatit Akademisi, Kolin Otel, Çanakkale




# Olgu -2

- NA, kadın,1981
- Herhangi bir yakınması yok
- Anne HCC nedeniyle ölünce yakınlarına tarama öneriliyor ve HBsAg (+) çıkıyor
- Tetkik ve tedavi amacıyla başvuru




# Özgeçmiş

- Sigara alkol kullanmıyor
- Kullandığı ilaç yok
- Kan transfüzyonu yok
- Operasyon yok




# Soygeçmiş

- Anne HCC nedeniyle ex
- Baba ex (nedeni ?)
- Abilerinden biri de HBsAg (+)




# Fizik Muayene

- Genel Durum: İyi
- Sistem muayeneleri: Olađan



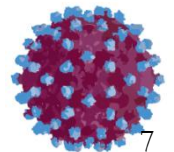
# Laboratuvar - 1

- Lökosit: 5300 mm<sup>3</sup>
- Hb: 12,1 gr
- Htc: %35.7
- Trombosit: 220 000 mm<sup>3</sup>
- PZ: 14,1 sn
- Sedimentasyon: 41/saat




# Laboratuvar - 2

- AST: 162/73/47 U/L
- ALT: 99/57/21 U/L
- ALP: 52 U/L
- GGT: 16 U/L
- T. Bilirubin: 0,77 mg/dl
- D. Bilirubin: 0,21 mg/dl
- Alb: 4,4 g/dl
- Glb: 5,5 g/dl
- AFP: 1,57



# Laboratuvar - 3


- Anti-HAV IgM: (-)
- Anti-HAV Total: (+)
  
- Anti-HCV: (-)
  
- HBsAg: (+)
- Anti-HBc IgM: (-)
- Anti-HBc Total: (+)
- HBeAg: (-)
- Anti-Hbe: (+)
  
- Anti-HDV: (+)






# Laboratuvar - 4

- HBV DNA: (+) < 1000 k/ml
- HDV RNA: (+)



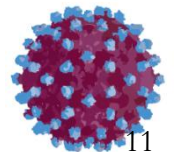
# Laboratuvar - 5

- ANA: (-)
- AMA: 1/40
- ASMA: 1/320
- LKM: (-)




# Batın USG


- Karaciğer boyutu ve parankimi normal
- Asit yok
- Dalak normal



Ne yapalım?




# Karaciğer biyopsisi?




# Karaciğer biyopsisi

- Karaciğer biyopsisi kararı alınıyor



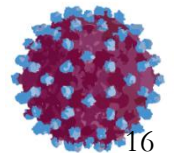
# Karaciğer Biyopsisi

- Karaciğer biyopsisi;
  - ◆ Peri-portal veya peri-septal interfaz hepatiti: 3
  - ◆ Konfluen nekroz: 2
  - ◆ Fokal nekroz: 2
  - ◆ Portal enflamasyon: 2
  - ◆ HAI: 9/18
  - ◆ Fibrozis: 2/6



---

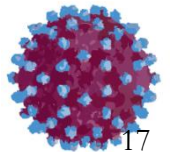
Ne yapalım?





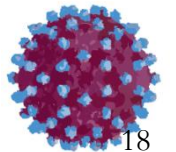
# Seenekler

- Tedavisiz izlerim
- Tedavi bařlarım




# Karar

- Pegile İnterferon- $\alpha$  2b 100  $\mu$ /hf SC (70 kg) başlanıyor




# İzlem

- Üçüncü ay; HBsAg: (+)
- Anti-Delta: (+)
- HBV DNA: (+) < 1000 k/ml
- HDV RNA: (-)




# İzlem (2 yıl sonra)

- HBsAg: (-)
- Anti-HBs: (-)
- Anti-Delta: (+)
  
- HBV DNA: (-)
- HDV RNA: (-)
  
- Tedavi kesiliyor.



# İzlem (1,5 yıl sonra)

- HBsAg: (-)
- Anti-Delta: (+)
  
- HBV DNA: (-)
- HDV RNA: (-)



# İzlem (7 yıl sonra)

- HBsAg: (-)
- Anti-HBs: (+/-)
- Anti-Delta: (+)
  
- HBV DNA: (-)
- HDV RNA: (-)

