İnfeksiyon Hastalıklarının Tanısında Mikrobiyoloji Laboratuvarı Kullanım Rehberi

Dr Gökhan AYGÜN
CTF Tıbbi Mikrobiyoloji AD

Aklınızda kalsın....

- Bu bir TARTIŞMA oturumudur !
- Qui rogat, non errat
  Soru sormak hata değildir.

Clinical Laboratory Testing - Today

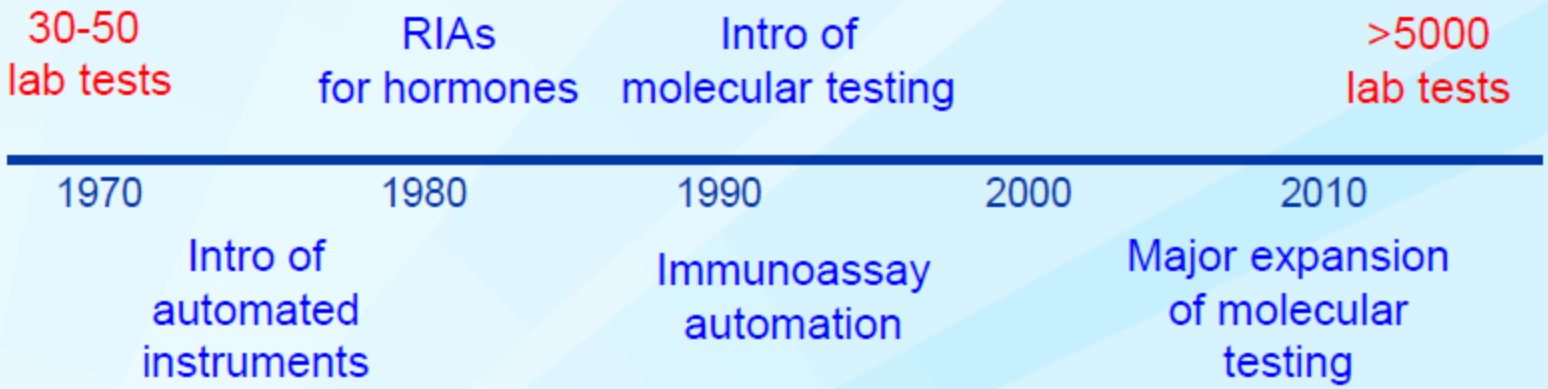

Michael Laposata, AACC 2010

Programs and training courses

Systems

Models

Test Selection
Result Interpretation

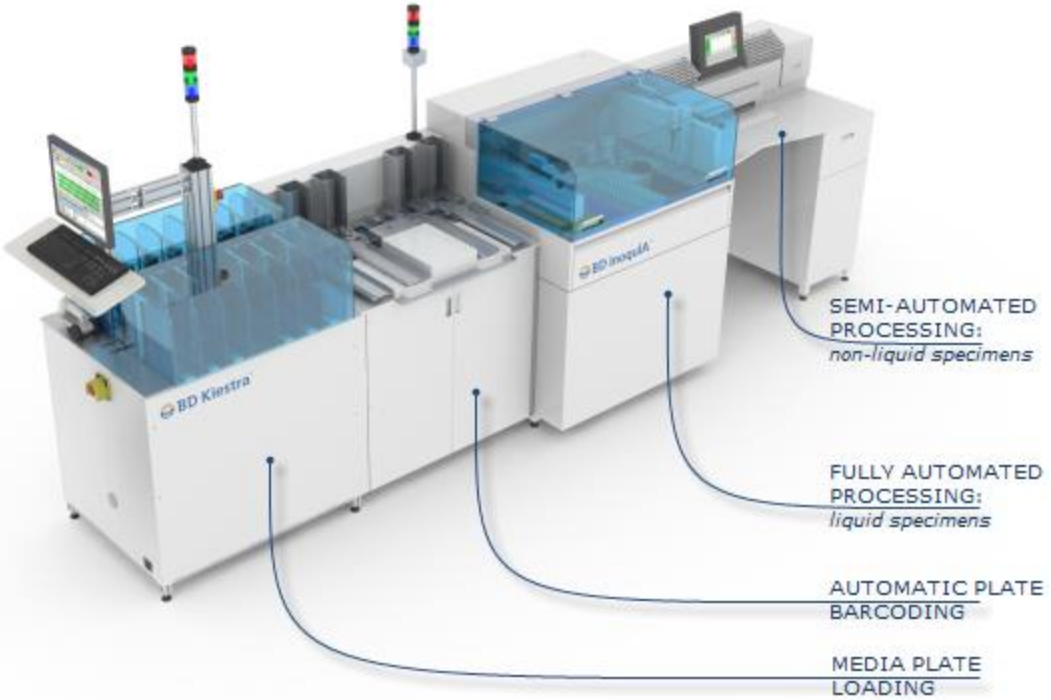
BD Kiestra
BD InoqulA
SEMI-AUTOMATED PROCESSING:
non-liquid specimens
FULLY AUTOMATED PROCESSING:
liquid specimens
AUTOMATIC PLATE BARCODING
MEDIA PLATE LOADING

BIOMERIEUX

BD
Phoenix 100

Gelecekte Klinik Mikrobiyoloji

JOURNAL OF CLINICAL MICROBIOLOGY, Nov. 2002, p. 3889–3893 Vol. 40, No. 11
0095-1137/02/$04.00+0 DOI: 10.1128/JCM.40.11.3889–3893.2002
Copyright © 2002, American Society for Microbiology. All Rights Reserved.

GUEST COMMENTARY

Clinical Microbiology in the Year 2025

W. Michael Dunne, Jr.,[1]* J. Keith Pinckard,[1] and Lora V. Hooper[2]

Departments of Pathology and Immunology[1] and Molecular Biology and Pharmacology,[2] Washington University School of Medicine, St. Louis, Missouri 63110

Laboratory is a Key Source of Diagnostic Errors

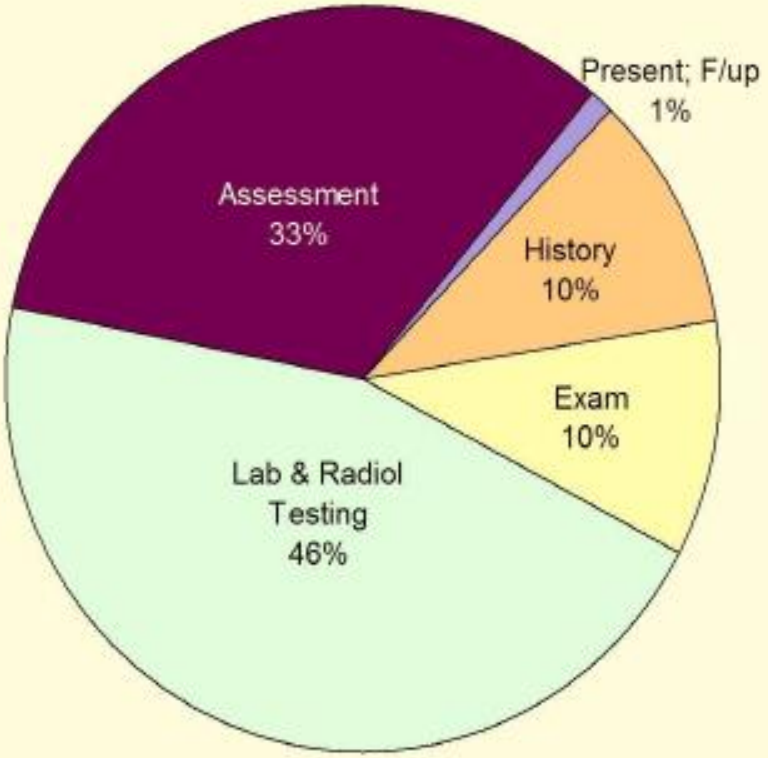

N= 583 Cases

G. D. Schiff et al., "Diagnostic error in medicine: analysis of 583 physician-reported errors.," *Archives of internal medicine*, vol. 169, no. 20, pp. 1881-7, Nov. 2009.

Klinik Mikrobiyoloji Laboratuvarı

Uygun Örnek ne olabilir, hangi testleri istemelisiniz

- Laboratuvar çalışmaları

Üreme etken/kolonizasyon…YORUM

Sonucun kullanımının takibi

Kontrol önlemleri

Rehber

IDSA GUIDELINES

A Guide to Utilization of the Microbiology Laboratory for Diagnosis of Infectious Diseases: 2013 Recommendations by the Infectious Diseases Society of America (IDSA) and the American Society for Microbiology (ASM)[a]

Ellen Jo Baron,[1,2] J. Michael Miller,[3] Melvin P. Weinstein,[4] Sandra S. Richter,[5] Peter H. Gilligan,[6] Richard B. Thomson Jr.,[7] Paul Bourbeau,[8] Karen C. Carroll,[9] Sue C. Kehl,[10] W. Michael Dunne,[11] Barbara Robinson-Dunn,[12] Joseph D. Schwartzman,[13] Kimberle C. Chapin,[14] James W. Snyder,[15] Betty A. Forbes,[16] Robin Patel,[17] Jon E. Rosenblatt,[17] and Bobbi S. Pritt[17]

Canlılarla uğraşıyoruz!

Mikroplar; büyür, çoğalır ve ölür !

Örneklerin alınması, gönderilmesi ve işleme alınması süreçleri kritik

«Uygun örnek yok ise uygun sonuç yok!»

İletişim
«yetersiz iletişim ideal sonucu engeller»

- Klinisyen !

İnfeksiyon ?

Etken?

Hangi İlaç ?

- Laboratuvar !

Örnek ne ve nasıl ,nereden , ne zaman alındı?

Kim ile iletişim sağlayacağım !

Antibiyotik?

İmmunsupresyon?

.....

Hastanın Adı, Soyadı : Selim Bey	Tarih : 23.3.2006 Prot. No :
Hastanın Kurumu :	Dr. Dip. No. Adı, Soyadı : (Varsa Kaşesi)
Tabibin Kurumu : Cerrahpaşa Tıp Fakültesi ..... Anabilim Dalı	

İLAÇLAR	TUTARI
Minoniyoloji Tab — Adrar mültüm düzeyi	

İLAÇLAR	TUTARI
Sınıf 6/e	
İlk	

İletişim ?

Uygun /saygılı örnek

Yetkin/sertifikalı (!) laboratuvar uzman-çalışan-örnek alan!

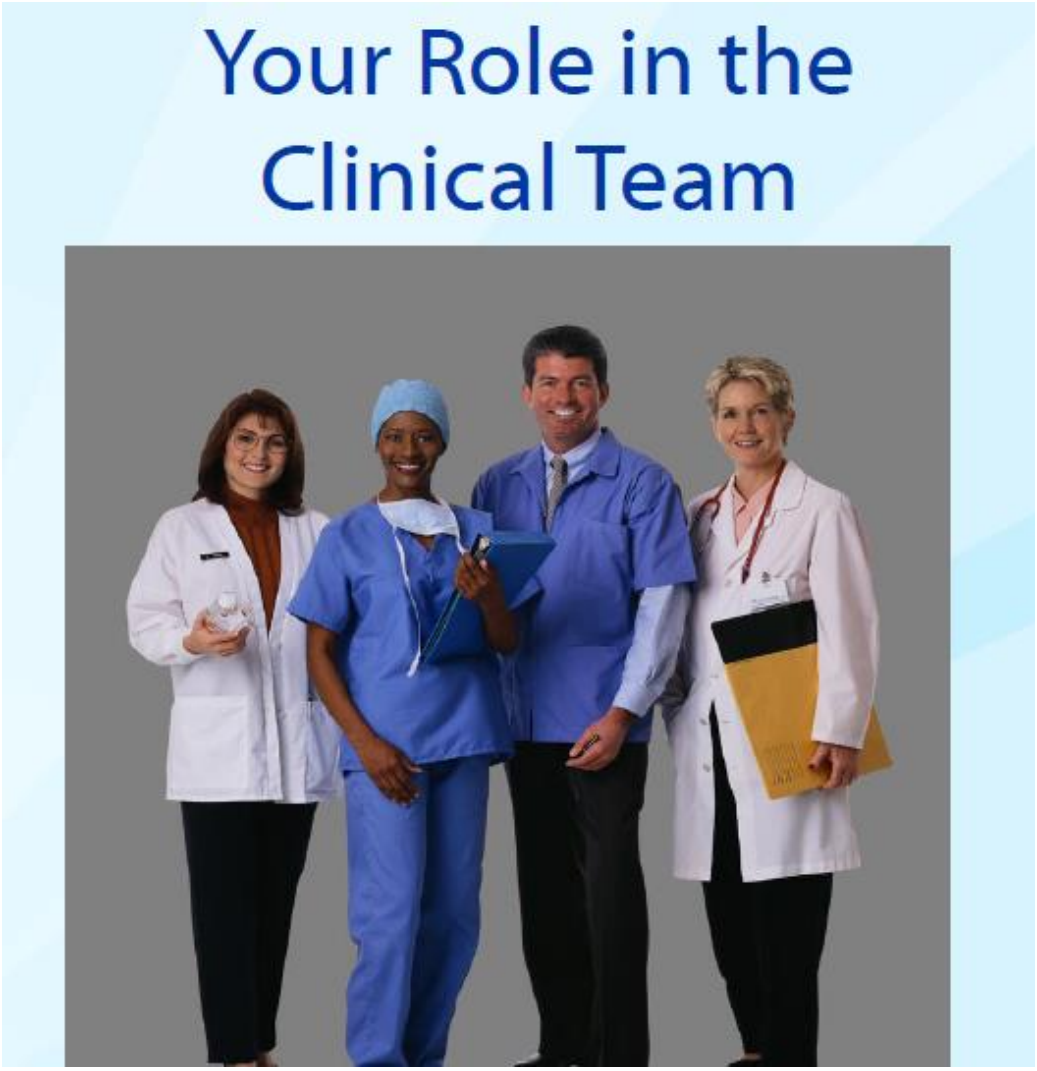

SORU?

- Tüm herşeye hakim (!) KMEHU bu işleri görsün!

- KMEHU ile MİKROBİYOLOJİ Laboratuvarı birlikte çalışsın

Genel Kurallar

- Uygun olmayan örnek çalışılmaz!
- Gerekli örnekler gönderilmeli !
- Örnek alıırken kontaminasyondan kaçın!
- Eküvyon uygun örnek değil !
- Laboratuvarın standart uygulama rehberleri olmalı/uygulanmalı!
- Örnekler antibiyotik öncesi alınmalı!
- Duyarlılık testleri sadece klinik anlamlı örneklere yapılmalı
- Laboratuvar raporları doğru, anlamlı ve kliniğe yardımcı olarak düzenlenmeli
- Laboratuvar teknik altyapısını belirler ve iletir
- Yorum için örnek konusunda ayrıntılı veri gerekli!

Hemokültür

- Bakteriyemi olgularında

  48 saat

  5 gün inkübasyon periyodu

  Dimorfik mantarlarda ve mikobakterilerde daha uzun süreli inkübasyon

  Küf mantarları için başarı düşük

  Candida (% 50-75)

Hemokültür

Table I-1. Blood Culture Laboratory Diagnosis Organized by Etiologic Agent

Etiologic Agents	Diagnostic Procedures	Optimum Specimen	Transport Issues
Staphylococcus spp	Adults:	20–30 mL of blood per culture set in adults injected into at least 2 blood culture bottles[a]	Inoculated culture vials should be transported to the Laboratory as soon as possible (ASAP) at RT, organisms will usually survive in inoculated culture vials even if not incubated immediately
Streptococcus spp, *Enterococcus* spp	2–4 blood culture sets per septic episode		
Listeria monocytogenes			
Enterobacteriaceae			
Pseudomonas spp			
Acinetobacter spp	Infants and children:	Blood volume depends on the child's weight (see Table in footnote 3)[b]	
HACEK[c] bacteria	2 or more blood culture sets		
Brucella spp			
Anaerobic bacteria			

cultured (see Table I-1a for recommended volumes). A second important determinant is the number of blood culture sets performed during a given septic episode. Generally, in adults with a suspicion of BSI, 2–4 blood culture sets should be obtained in the evaluation of each septic episode [5, 7].

Hemokültür

Table I-1a. Recommended Volumes of Blood for Culture in Pediatric Patients (Blood Culture Set May Use Only 1 Bottle)

Weight of Patient (kg)	Total Patient Blood Volume (mL)	Recommended Volume of Blood for Culture (mL)		Total Volume for Culture (mL)	% of Total Blood Volume
		Culture Set No. 1	Culture Set No. 2		
≤1	50–99	2	. . .	2	4
1.1–2	100–200	2	2	4	4
2.1–12.7	>200	4	2	6	3
12.8–36.3	>800	10	10	20	2.5
>36.3	>2200	20–30	20–30	40–60	1.8–2.7

When 10 mL of blood or less is collected, it should be inoculated into a single aerobic blood culture bottle.

[a] Typically, blood specimens are split between aerobic and anaerobic blood culture bottles. There may be circumstances in which it is prudent to omit the anaerobic vial and split blood specimens between 2 aerobic vials. One example is when fungemia due to yeast is strongly suspected. Most manufacturers' bottles accept a maximum of 10 mL per bottle.

Hemokültür- Özet

- Volüm kritik öneme sahiptir!
- Klorheksidin ve iyot tentürü (%2) en ideal antiseptiktir. (2 ay altında çocuklarda KH riskli)
- HK antibiyotik öncesi alınmalıdır
- Sadece kateterden alınan HK kontaminasyon yönünden risklidir. Uygun olmaz
- Kateter ucu tek başına (HK yokluğunda) anlamlı olmaz
- Anaerobik şişeler pnömokok gibi bazı bakteriler için daha iyi üreme olanağı sağlar

Kontaminasyon

- En çok % 3
- PKN staf, viridans str, difteroid
- Bacillus spp

- Klinisyene antibiyotiksiz bildir!
- (İLETİŞİM!!!)

Bartonella spp	2 or more lysis- centrifugation (Isolator) blood culture vials[d]	10 mL of blood should be inoculated directly into each lysis-centrifugation culture vial	Lysis-centrifugation culture vials should be transported at RT to the laboratory ASAP and processed within 8 h of blood inoculation
	NAAT	5 mL of plasma	EDTA tube, RT, 2 h
Legionella spp	2 or more lysis- centrifugation (Isolator) blood culture vials[e]	10 mL of blood should be inoculated directly into each lysis-centrifugation culture vial	Lysis-centrifugation culture vials should be transported at RT to the laboratory ASAP and processed within 8 h of blood inoculation
	Legionella urine antigen test (for serotype 1)	10 mL of mid-stream, clean-catch urine[f]	Closed container, RT, 2 h
Coxiella burnetii	Coxiella IFA serology	5 mL of serum	Clot tube, RT, 2 h
	NAAT	5 mL of plasma	EDTA tube, RT, 2 h
Tropheryma whipplei	NAAT	5 mL of plasma	EDTA tube, RT, 2 h
Yeast	Adults: 2–4 blood culture sets (see above)	20–30 mL of blood per culture in adults injected into at least 2 blood culture bottles[g]	Inoculated culture vials should be transported ASAP at RT to the laboratory for early incubation
	Infants and children: 2 or more blood culture sets (see above)	As much blood as can be conveniently obtained from children; volume depends on weight of child (see following table)[b]	Organisms will usually survive in inoculated culture vials even if not incubated immediately. *Malassezia* spp require lipid supplementation; lysis-centrifugation is recommended for their recovery.
Filamentous and dimorphic fungi[h]	2 or more lysis- centrifugation (Isolator) blood culture vials	10 mL of blood should be inoculated directly into each lysis-centrifugation culture vial	Lysis-centrifugation culture vials should be transported to the laboratory ASAP and processed within 8 h of blood inoculation
Mycobacteria	3 cultures using AFB-specific blood culture bottles	5 mL of blood inoculated directly into AFB-specific blood culture bottle	Inoculated culture vials should be transported to the laboratory ASAP for early incubation

Abbreviations: AFB,acid fast bacillus; IFA, indirect fluorescent antibody; NAAT,nucleic acid amplification test; RT, room temperature.

[a] Typically, blood specimens are split between aerobic and anaerobic blood culture bottles. There may be circumstances in which it is prudent to omit the anaerobic

Kateter ilişkili bakteriyemi

- Diğer odakların dışlanması

- Üreme zamanı

  (KK 2 saat erken PK)
- Kantitatif kültür
- Maki (kateter segmenti kültürü)

Miyokadit/perikardit

- Perikard sıvısı ya da biopsi
- Viral etkenler için.NAAT, seroloji, histopatoloji
- Parazit tutulumu (Trypanasoma, T.gondii, Trişinella) ....endomiyokardial biopsi ya da seroloji

- Laboratuvar ile iletişim!

MSS infeksiyonları

BOS

- 3-4 tüp örnek
- İlk tüp mikrobiyoloji için uygun olmaz
- En az 0.5-1 mL
- GRAM !!! (ACİL)

(AB yok ise % 60-80)

LA çok başarılı değil

- HK (+)
- BOS örneğini dondurma!
- Az miktarlara bölünmüş (en az 1 mL) çok sayıda örnek uygundur.

MSS infeksiyonları

Table II-1. Laboratory Diagnosis of Meningitis

Etiologic Agents	Diagnostic Procedures	Optimum Specimens	Transport Issues; Optimal Transport Time
Bacterial			
Streptococcus pneumoniae	Gram stain[a]	Cerebrospinal fluid, blood	Sterile container (CSF), aerobic blood culture bottle (blood), RT, immediately
Neisseria meningitidis	Aerobic bacterial culture		
Listeria monocytogenes			
Streptococcus agalactiae			
Haemophilus influenzae			
Escherichia coli			
Other *Enterobacteriaceae*			
Elizabethkingia meningoseptica			
Mycobacterium tuberculosis	AFB smear	Cerebrospinal fluid (≥5 mL)	Sterile container, RT;2 h
	AFB culture		
	M. tuberculosis NAAT[b]	Cerebrospinal fluid	Closed container,RT, 2 h

MSS infeksiyonları

- Tüberküloz menenjit (en az 5 mL BOS)

NAAT sensitivitesi düşük

(+ sonuçlar !!!)(negatif sonuç ???)

Kültür gerekli (%25-70)

Spirochetal			
Treponema pallidum (syphilis)	VDRL, FTA-ABS	Cerebrospinal fluid	Sterile container, RT, 2 h
	Traditional: RPR screening test with positive RPR confirmed by *T. pallidum* particle agglutination (TP-PA) test or other treponemal confirmatory test	1 mL serum	Clot tube, RT, 2 h
	Reverse sequence: EIA or chemiluminescent immunoassay treponemal screening test with positive confirmed by RPR (negative RPR reflexed to TP-PA)		
Borrelia burgdorferi (Lyme disease)	*B. burgdorferi* antibodies, IgM and IgG with Western blot assay confirmation (not validated for CSF)	1 mL serum	Clot tube, RT, 2 h
		1 mL CSF (include a CSF index: simultaneous CSF:serum ratio of *B. burgdorferi* antibodies with normalized protein amounts).	
	B. burgdorferi antibodies, IgM and IgG with Western blot assay confirmation (not validated for CSF)	Cerebrospinal fluid	Closed container, RT, 2 h
	B. burgdorferi NAAT (low sensitivity)	Cerebrospinal fluid	Closed container, RT, 2 h
Leptospira species	*Leptospira* culture (special media required; rarely available in routine laboratories)	1st week of illness: Cerebrospinal fluid, 10 mL blood	Sterile container, heparin or citrate tube (blood), RT, immediately
		After 1st week of illness: 10 mL urine (neutralized)	Sterile container, RT, immediately
	Leptospira antibody, microscopic agglutination test	1 mL serum	Clot tube, RT, 2 h

Mantar menenjiti

Fungal			
Cryptococcus neoformans, *Cryptococcus gattii*	*Cryptococcus* antigen test	Cerebrospinal fluid	Closed container, RT, 2 h
	Gram stain	Cerebrospinal fluid	Sterile container, RT, 2 h
	Aerobic bacterial culture (faster growth on blood agar medium)		
	Fungal culture		
Coccidioides species[c]	*Coccidioides* antibody, complement fixation and immunodiffusion[c]	Cerebrospinal fluid and/or 1 mL serum	Closed container or clot tube (blood), RT, 2 h
	Calcofluor stain	Cerebrospinal fluid	Sterile container, RT, 2 h
	Fungal culture		

- Gram ???? Çini mürekkebi !

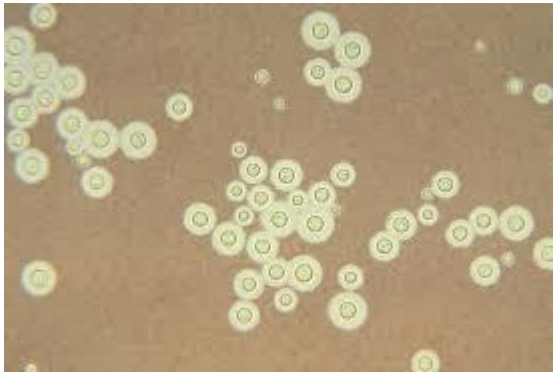

Viral menenjit

Viral			
Enteroviruses (nonpolio)	Enterovirus NAAT	Cerebrospinal fluid	Closed container, RT, 2 h
Parechoviruses	Parechovirus NAAT	Cerebrospinal fluid	Closed container, RT, 2 h
Herpes simplex virus (HSV)	HSV 1 and 2 NAAT	Cerebrospinal fluid	Closed container, RT, 2 h
Varicella zoster virus (VZV)	VZV NAAT	Cerebrospinal fluid	Closed container, RT, 2 h
Lymphocytic choriomeningitis virus (LCM)	LCM antibodies, IgM and IgG, IFA	Cerebrospinal fluid and/or 1 mL serum	Closed container or clot tube (blood), RT, 2 h
Mumps virus	Mumps virus antibodies, IgM and IgG	Cerebrospinal fluid and/or 1 mL serum	Closed container or clot tube (blood), RT, 2 h
	Mumps culture and Mumps NAAT	Cerebrospinal fluid, urine, buccal swab	Sterile container, on ice, immediately Viral transport device,on ice, immediately
Human immunodeficiency virus (HIV)	[d]		

Viral ansefalit

- BOS NAAT testi önerilenler:

  HSV, VZV, Enteroviruslar, HHV-6, JC

  CMV, EBV (latent viruslar !!!)

  WNV, Adenovirus, İnfluenza, Kabakulak, ..BOS serolojik testler tanıda faydalı olabiliyor.

  LCMV, Arboviruslar serolojik yaklaşım daha önemli !

  İnfluenza, kızamık, kabakulak, adenovirus diğer bölge kültürleri (nazofarenks) faydalı

  Kuduz (antijen, DFA)

Bakteriyel ansefalit

NAAT ya da seroloji yaklaşımı öncelikli!

- Ehrlichia spp, Rickettsia spp, Anaplasma spp
- Coxiella burnetii
- Bartonella spp
- Mycoplasma pneumoniae
- Tropheryma whipplei

TBC, Listeria..... Kültür yaklaşımı öncelikli

Parazitik ansefalit

Parasitic			
Acanthamoeba spp	Microscopic wet mount	Cerebrospinal fluid	Closed container, RT, 2 h
Naegleria fowleri	Giemsa stain		
	Histology (trichrome stain)	Cerebrospinal fluid, brain tissue	Closed container, RT, 2 h
	Culture	Cerebrospinal fluid, brain tissue	Sterile container, RT, 2 h
	Acanthamoeba antibody IFA[i]	1 mL serum	Clot tube, RT, 2 h
	Acanthamoeba IIF staining[j]	Brain tissue	Closed container, RT, 2 h
	Histology (trichrome stain)	Brain tissue	Closed container, RT, 2 h
Balamuthia mandrillaris	*Balamuthia* antibody, IFA[i]	1 mL serum	Clot tube, RT, 2 h
	Balamuthia IIF staining[j]	Brain tissue	Closed container, RT, 2 h
Baylisascaris procyonis[j]	*B. procyonis* antibodies	Cerebrospinal fluid and/or 1 mL serum	Closed container or clot tube (blood), RT, 2 h
Trypanosoma brucei spp	Giemsa stain	Cerebrospinal fluid, brain tissue	Closed container, RT, 2 h
		Blood	EDTA tube, RT, 2 h
Toxoplasma gondii	*Toxoplasma* NAAT	Cerebrospinal fluid, 1 mL serum, plasma	Closed container, clot tube (blood), EDTA tube (blood), RT, 2 h
	Toxoplasma antibodies, IgM and IgG[k]	Cerebrospinal fluid and/or 1 mL serum	Closed container or clot tube (blood), RT, 2 h
	Giemsa stain, histology	Cerebrospinal fluid, brain tissue	Closed container, RT, 2 h

Prion !

- Laboratuvar uyarılmalı
- ÇOK ÖZEL ÖNLEMLER !!!

Prion			
Creutzfeldt-Jakob disease[l]	14-3-3 protein	Cerebrospinal fluid	Closed container, RT, 2 h
	Neuron-specific enolase (NSE)	Cerebrospinal fluid	Closed container, RT, 2 h
	Routine histology, immune stain for prion protein	Formalin fixed brain tissue	Contact surgical pathologist prior to collection of tissue[m]
	Western blot for prion protein	Frozen brain tissue	Contact surgical pathologist prior to collection of tissue[m]
	PrP gene sequencing	Blood, other tissues	EDTA tube, closed container, RT, 2 h

Fokal beyin lezyonları

- Bakteri, fungus, parazit olabilir!
- Nocardia olasılığı hatırlanmalı

*Mod.EZN, 7 gün inkübasyon, özel besiyerleri(BCYE agar)

- Apse, doku örneği gerekli
- T.gondii ve T.solium (Nörosistiserkozis) tanısında serumdaki antikor tetkikleri önemli !

Fokal beyin lezyonları: mantar!!

Fungal			
Candida spp	Calcofluor stain		
Cryptococcus spp	Fungal culture	Aspirate of abscess contents, tissue	Sterile container, RT, 2 h
Aspergillus spp	Histology (GMS stain)	Tissue	Closed container, RT, 2 h
Zygomycetes *(Rhizopus, Mucor* sp*)*	Mucicarmine stain for *Cryptococcus*		
Scedosporium apiospermum			
Trichosporon spp			
Trichoderma spp			
Dematiaceous moulds *(Cladiophialophora bantiana, Bipolaris* spp, *Exophiala* spp			
Endemic dimorphic fungi			

Primary Central Nervous System Phaeohyphomycosis: A Review of 101 Cases

Sanjay G. Revankar,[1] Deanna A. Sutton,[2] and Michael G. Rinaldi[2,3]

[1]Dallas Veterans Affairs Medical Center and Department of Medicine, University of Texas Southwestern Medical Center, Dallas, [2]Department of Pathology, University of Texas Health Science Center at San Antonio, and the [3]Audie L. Murphy Veterans Affairs Medical Center, San Antonio, Texas

Phaeohyphomycosis refers to infections caused by darkly pigmented fungi. These fungi rarely cause life-threatening disease. We reviewed 101 cases of culture-proven primary central nervous system phaeohyphomycosis reported in the English-language literature from 1966 to 2002. The most frequently isolated species was *Cladophialophora bantiana*. The next most frequent isolate was *Ramichloridium mackenziei*, seen exclusively in patients from the Middle East. More than one-half of the cases occurred in patients with no known underlying immunodeficiency. Mortality rates were high regardless of immune status. Therapy is not standardized, although the combination of amphotericin B, flucytosine, and itraconazole may improve survival rates. Newer azoles, such as voriconazole, also have a broad spectrum of activity against these fungi, although clinical experience is limited. Complete excision of brain lesions may provide better results than simple aspiration. An aggressive medical and surgical approach is warranted in treating these infections to optimize outcomes.

Şant infeksiyonları
(Diğer MSS komşu infeksiyonları)

- Kültür (BOS, abse)
- Buyyon içine ekim !
- Gram boyama, EZN , Kalkoflor

Table II-4. Laboratory Diagnosis of Central Nervous System Shunt Infections

Etiologic Agents	Diagnostic Procedures	Optimum Specimens	Transport Issues; Optimal Transport Time
Bacterial (1 organism or mixed)			
Aerobes: *Staphylococcus, Streptococcus, Enterobacteriaceae, Pseudomonas, Acinetobacter, Corynebacterium* spp	Gram stain	Cerebrospinal fluid	Sterile, anaerobic container, RT, immediately
Anaerobes: *Propionibacterium acnes*	Aerobic and anaerobic bacterial culture (hold 14 d for *P. acnes*)		
Mycobacterium spp (rare)	AFB smear AFB culture	Cerebrospinal fluid (≥5 mL)	Sterile container, RT, 2 h
Fungal			
Candida spp, other fungi	Calcofluor stain Fungal culture	Cerebrospinal fluid	Sterile container, RT, 2 h

Göz infeksiyonları

- Göz Hekimi örneği almalı
- Hasta başı ekim tercih edilir

- C.trachomatis

DFA ve kültür (+)

NAAT henüz onaylı değil fakat uygulanabilir!

- Boyalar ve lokal anestezikler NAAT için inhibitör!

- Örneğin yeri belirtilmeli (kornea, konjunktiva,...)
- Hasta ve sağlam gözden alınan örneklerin Gram incelemeleri birlikte yapılmalı
- Normal cilt florası etken olarak düşünülmemeli!

Göz infeksiyonları !

- Keratit...Postop inf.... PKN staf, P.acnes !
- Lens sıvısı kontaminasyonu ile salgınlar !!!

  * Fusarium, Acanthomoebea

  * Sporadik olgular : P.aeruginosa

  * Lens sıvısı kültürü (yanlış (+)) riski
- Endojen endoftalmit : bakteriyei, fungemi (candida)
- Retinit: T.gondii, CMV, Tbc, Sifiliz

Yüz bölgesi yumuşak doku infeksiyonları

- Etkenler flora elemanları!
- İmmunsupresyon

  * Mantarlar !!!
- Anaeroplar (+)
- Biopsi !!!
- Eküvyon uygun değil!
- Epiglottit şüphesinde riskli !!!

Vincent /Lemierre

Gram tanısal

Kültür önerilmez

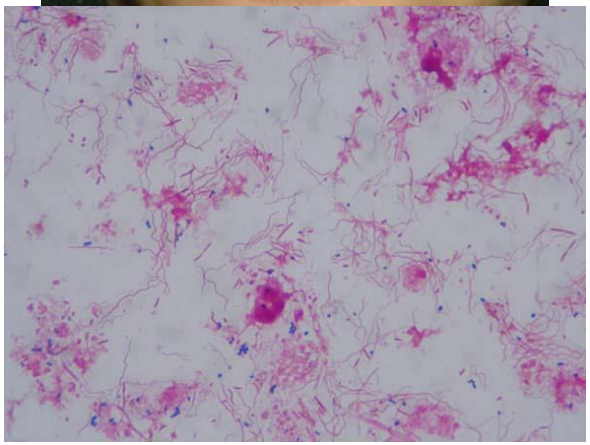

F.necrophorum

Hemokültür ! (+)

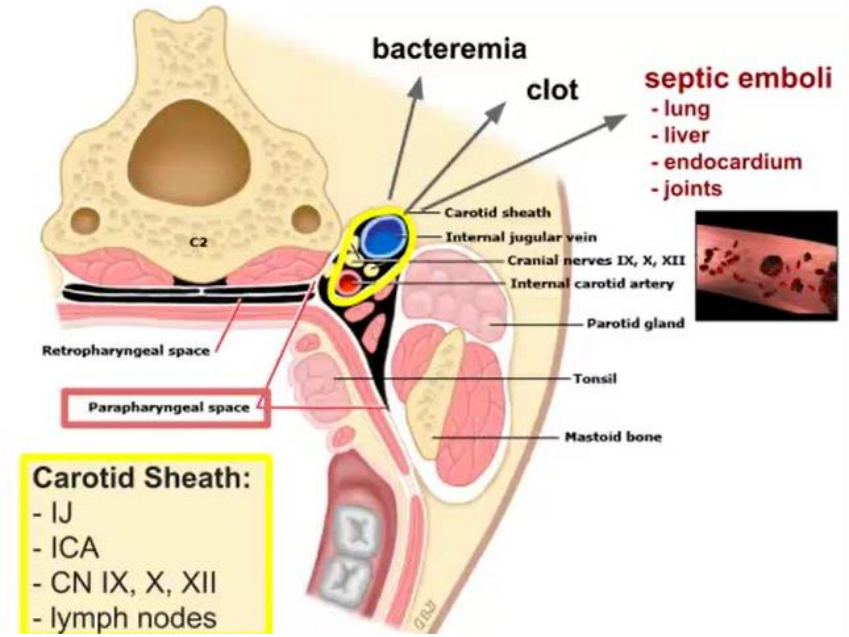

Üst solunum yolu infeksiyonları

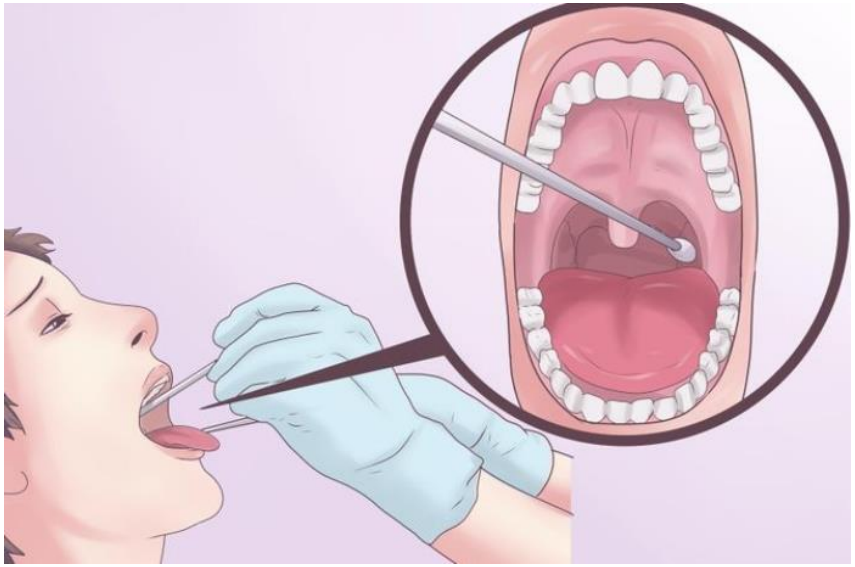

- OM ve sinüzitte sürüntünün yeri yok (aspirat!)
- Boğaz kültürü boğaz ve tonsillerden alınmalı!
- H.influenzae, s.aureus, Meningokok, Pnömokok farenjit etkeni değil!

  (çalışılmamalı)

Table V-3. Laboratory Diagnosis of Pharyngitis

Etiological Agents	Diagnostic Procedures	Optimum Specimens	Transport Issues; Optimal Transport Time
Bacterial			
Streptococcus pyogenes	Rapid direct antigen test (followed by a secondary test if negative)[a]	Dual pharyngeal swab	Swab transport device, RT, 2 h
	Direct nucleic acid amplification test (NAAT)[b]	Pharyngeal swab	Swab transport device, RT, 2 h
	Nucleic acid probe tests[b]	Pharyngeal swab	
Groups C and G β-hemolytic streptococci[c]	Throat culture and antigen tests on isolates for Groups C and G streptococci	Pharyngeal swab	Swab transport device, RT, 2 h
Arcanobacterium haemolyticum[d]	Throat culture for *A. haemolyticum*	Pharyngeal swab	Swab transport device, RT, 2 h
Neisseria gonorrhoeae[d]	Throat culture for *N. gonnorrhoeae*	Pharyngeal swab	Swab transport device, RT, 2 h
Corynebacterium diphtheriae[d]	Methylene blue stain *C. diphtheriae* culture	Pseudomembrane	Sterile container, RT, immediately
Fusobacterium necrophorum	Anaerobic incubation. A selective medium is available	Pharyngeal swab	Anaerobic swab transport, RT, 2 h
Viral			
Epstein-Barr virus (EBV)	Monospot test[e]	5 mL serum	Clot tube, RT, 2 h
	EBV serology		
Herpes Simplex virus (HSV) [usually Type 1]	Direct detection test[f]	Swab of pharyngeal lesion	Swab transport device, RT, 2 h
	Culture[f]		
	HSV IgG and IgM serology[g]	5 mL serum	Clot tube, RT, 2 h
Cytomegalovirus (CMV)	CMV IgM serology	5 mL serum	Clot tube, RT, 2 h
Human immunodeficiency virus (HIV)	(see XIV Viral Syndrome)		

Alt solunum yolu infeksiyonları

- Kistik fibroz özel yaklaşım
- İmmunsuprese konakta geniş bir etyolojik araştırma
- Sabah ilk balgam ideal örnek
- Kalsiyum alginat eküvyonlar NAAT için uygun değil
- HK riskli TEP olgularında faydalı olabilir

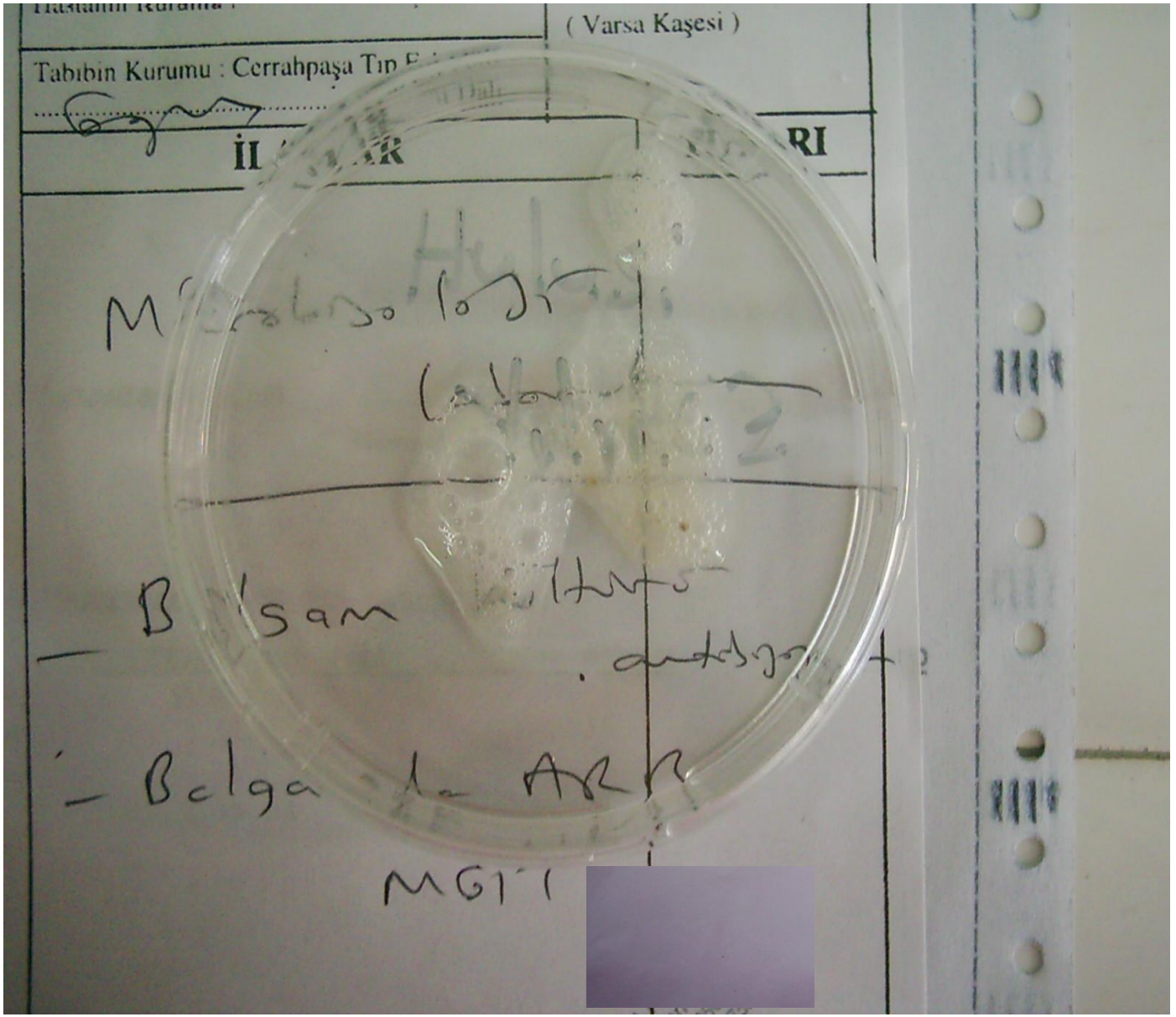
(Varsa Kaşesi)
Tabıbin Kurumu : Cerrahpaşa Tıp
İL
RI
Balsam
Belga
MGIT

Table VI-2. Laboratory Diagnosis of Community-acquired Pneumonia

Etiologic Agents	Diagnostic Procedures	Optimum Specimens	Transport Issues; Optimal Transport Time
Bacteria			
Streptococcus pneumoniae	Gram stain Culture	Sputum, bronchoscopic specimens	Sterile container, RT, 2 h; >2–24 h, 4°C
	Urine antigen[a]	Urine	Sterile container, RT, 24 h; >24 h–14 d, 2–8°C
Staphylococcus aureus *Haemophilus influenzae* Enterobacteriaceae *Pseudomonas aeruginosa*	Gram stain Culture	Sputum, bronchoscopic specimens	Sterile container, RT, 2 h; >2–24 h, 4°C
Legionella species	Urine antigen *L. pneumophila* serogroup 1	Urine	Sterile container, RT, 24 h; >24 h–14 d, 2–8°C
	Selective culture on BCYE	Induced sputum, bronchoscopic specimens	Sterile container, RT, 2 h; >2–24 h, 4°C
	NAAT[b]	Induced sputum, bronchoscopic specimens	Sterile container, RT, 2 h; >2–24 h, 4°C
Mycoplasma pneumoniae	NAAT[b]	Throat swab, NP swab, sputum, bronchoalveolar lavage (BAL)	Transport in M4 media or other *Mycoplasma*-specific medium at RT or 4°C up to 48 h; ≥48 h, −70°C
	Serology IgM, IgG antibody detection	Serum	Clot tube, RT, 24 h; >24 h, 4°C
Chlamydophila pneumoniae	NAAT[b]	NP swab, throat washings, sputum, bronchial specimens	Transport in M4 or other specialized medium at RT or 4°C up to 48 h; ≥48 h, −70°C
	Serology (MIF) IgM antibody titer; IgG on paired serum 2–3 wk apart	Serum	Clot tube, RT, 24 h; >24 h, 4°C
Mixed anaerobic bacteria (Aspiration pneumonia)	Gram stain Aerobic and anaerobic culture	Bronchoscopy with protected specimen brush	Sterile tube with 1 mL of saline or thioglycolate; RT, 2 h; >2–24 h

Table VI-3. Laboratory Diagnosis of Healthcare-Associated Pneumonia, Hospital-Acquired Pneumonia and Ventilator-Associated Pneumonia

Etiologic Agents	Diagnostic Procedures	Optimum Specimens	Transport Issues; Optimal Transport Time
Bacteria			
Pseudomonas aeruginosa	Blood culture	Blood cultures	Sterile cup or tube RT, 2 h; 4°C, >2–24 h
Escherichia coli	Gram stain	Sputum	
Klebsiella pneumoniae	Quantitative or semi-quantitative aerobic and anaerobic culture[a]	Endotracheal aspirates	
Enterobacter spp		BAL	
Serratia marcescens		Protected specimen brush samples[a]	
Acinetobacter spp		Lung tissue	
Stenotrophomonas maltophilia			
Staphylococcus aureus and MRSA			
Haemophilus influenzae			
Streptococcus pneumoniae	As above plus urine antigen[b]	Urine	Sterile container RT, 24 h; >24 h–14 d, 2–8°C
Mixed anaerobes (aspiration)	Gram stain Culture[a]	Protected specimen brush samples[a] Lung tissue	Sterile tube with 1 mL of thioglycolate (for brush samples); Sterile container for tissue; RT, 2 h; 4°C, >2–24 h
Legionella spp	Culture on BCYE media	Induced sputum	Sterile cup or tube RT, 2 h; 4°C, >2–24 h
	NAAT[c]	Endotracheal aspirates	
		BAL	
		Protected specimen brush samples	
		Lung tissue	
	Urine antigen (*L. pneumophila* serogroup 1 only)	Urine	Sterile container RT, <24 h; 4°C >24 h–14 d

VAP/VİP

- VAP....Klinik + kültür sonucu anlamlı
- BAL: 10^{6}
- ETA: 10^{4}
- Korunmuş fırça: 10^{3}

(Son 72 saatte AB başlanmadı ya da değişmedi ise)

Bronşial yıkama uygun örnek değil

Candida, Pk (-) stafilokoklar ? (anlamlı değil)

İmmunsuprese konakta pnömoni

- Çok geniş bir etiyolojik inceleme
- BAL/biopsi önemli
- CMV, HSV için biopsi bulgusu uygun
- Mantarlar için histopatoloji duyarlı değil!

  Özel boyamalar, NAAT

  BAL ve serum...galaktomannan

  Serum..... Beta-glukan

Mikobakteri

***Mycobacterium* species**			
M. tuberculosis	Acid fast stain AFB Culture NAAT (only 1 FDA-cleared test available; for smear-positive samples) Histology	Expectorated sputum Bronchoscopically obtained specimens Lung tissue	Sterile cup or tube RT, 2 h; 4°C, >2–24 h
M. avium intracellulare complex *M. kansasii* *M. xenopi* *M. haemophilum* Rapid growers eg, *M. abscessus*	Acid fast stain AFB culture Histology	Expectorated sputum Bronchoscopically obtained specimens Lung tissue	Sterile cup or tube RT, 2 h; 4°C, >2–24 h Formalin container, RT, 2–14 d

Mikobakteri

- Hastanın BAL öneği EZN (+)
- Üç gün sonra MGIT (+) LJ (+)
- HK üreyenden EZN(+)

- Pasajda Çukulata, Kanlı, MC besiyerinde üreme var

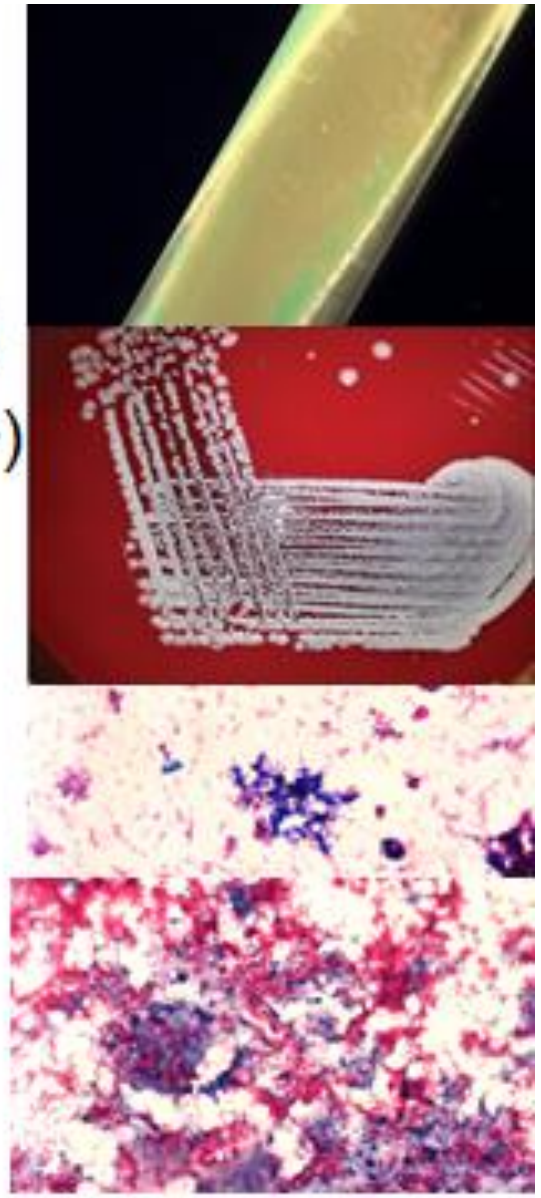

Solunum sistemi NAAT kullanalım?

- FDA onayı yok ! Firmalara özgü kitler (+)

Mycoplasma pneumuniae

C.pneumophilia spp, Legionella spp

Toxoplasma gondii, Crytosporidium spp

Pneumocystis jiroveci

CMV,HSV (!!!)

Özafajit/gastrit tanısı

Table VII-1. Laboratory Diagnosis of Esophagitis

Etiologic Agents	Diagnostic Procedures	Optimum Specimens	Transport Issues; Optimal Transport Time
Candida spp	Calcofluor-KOH stain	Esophageal brushing or biopsy	Sterile container, RT, 2 h
	Fungus culture		
	Histopathological examination	Esophageal biospy	Formalin container, RT, 2–14 d
Herpex simplex virus	HSV Culture	Esophageal brushing or biopsy	Viral transport device, on ice, immediately
	Direct fluorescent stain		
	Nucleic acid amplification test (NAAT)	Esophageal brushing or biopsy	Closed container, RT, 2 h
	Histopathological examination	Esophageal biopsy	Formalin container, RT, 2–14 d
Cytomegalovirus	CMV Culture	Esophageal brushing or biopsy	Viral transport device, on ice, immediately
	Direct fluorescent stain		
	NAAT	Esophageal brushing or biopsy	Closed container, RT, 2 h
	Immunohistochemical stain	Esophageal biopsy	Formalin container, RT, 2–14 d

Abbreviations: NAAT, nucleic acid amplification test; KOH, potassium hydroxide; RT, room temperature.

Table VII-2. Laboratory Diagnosis of Gastritis

Etiologic Agents	Diagnostic Procedures	Optimum Specimens	Transport Issues; Optimal Transport Time
Helicobacter pylori	*H. pylori* stool antigen test	Stool specimen	Closed container, RT, 2 h
	Urea breath test	Radiolabeled breath	Special collection device
	Gram stain	Two biopsies from antrum and two biopsies from posterior corpus	Sterile container, RT, immediately
	H. pylori culture[a]		
	Histopathological examination[a]	Same as above	Formalin container, RT, 2–14 d
	Agar-based or rapid tissue urease tests[b]	Same as above	Closed container, RT, 2 h

Gastroenterit yaklaşımı

Uygun örnek ishal dışkısı !!!

Katı dışkılar uygun örnek değil



Bacteria			
Clostridium difficile	Nucleic acid amplification test (NAAT)	Stool	Closed container, RT, 2 h
	Glutamate dehydrogenase (GDH) antigen with or without toxin detection followed by cytotoxin or NAAT confirmation	Stool	Closed container, RT, 2 h
Salmonella spp	Routine stool enteric pathogen culture[a]	Stool	Closed container, RT, 2 h[b]
Shigella spp			Cary-Blair transport medium, RT, 24 h
Campylobacter spp			
Enterohemorrhagic *E. coli* (including *E coli* O157:H7 and other Shiga-toxin-producing *E. coli*)	Culture for *E. coli* O157:H7[c]	Stool	Closed container, RT, 2 h[b]
	Shiga-toxin immunoassay	Stool	Closed container, RT, 2 h[b]
	NAAT for Shiga toxin genes	Stool	Closed container, RT, 2 h[b]
Yersinia spp	Specialized stool cultures[d]	Stool	Closed container, RT, 2 h[b]
Vibrio spp			
Aeromonas spp			
Plesiomonas spp			
Edwardsiella tarda			
Staphylococcus aureus			
E. coli			
Enterotoxigenic			
Enteroinvasive			
Enteropathogenic			
Enteroaggregative			
Bacillus cereus	Specialized procedure for toxin detection[e]	Stool	Closed container, RT, 2 h
Clostridium perfringens			
Staphylococcus aureus			
Clostridium botulinum	Mouse lethality assay[f] (Usually performed at the State Public Health Laboratory)	Stool, gastric contents, vomitus[g]	Closed container Store and transport specimens at 4°C. **Do not freeze**
Parasites			

E.coli ishalleri

- EHEC!

  0157-H7?

Toksin testleri!

Diğer E.coli ishalleri için kültür?

  Genetik testler

K.oxytoca

- Antibiyotik ilişkili hemorajik kolit
- Genelde penisilin, ampisilin sonrası
- Sitotoksin (+)

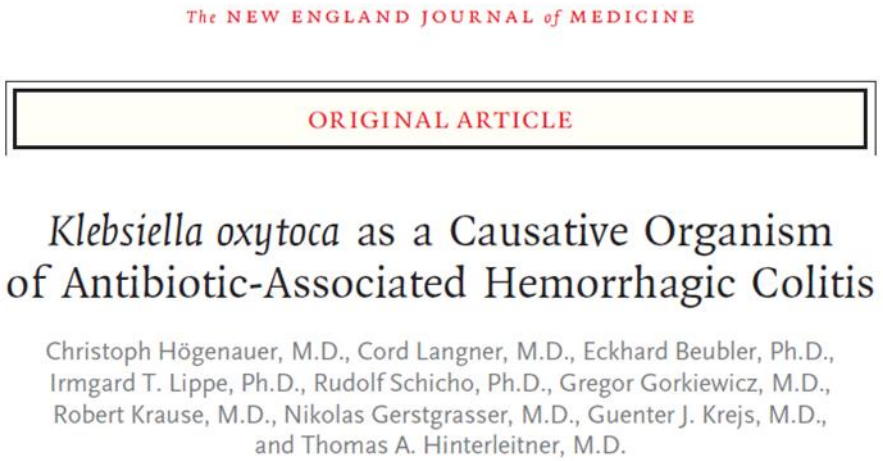

The NEW ENGLAND JOURNAL of MEDICINE

ORIGINAL ARTICLE

Klebsiella oxytoca as a Causative Organism of Antibiotic-Associated Hemorrhagic Colitis

Christoph Högenauer, M.D., Cord Langner, M.D., Eckhard Beubler, Ph.D., Irmgard T. Lippe, Ph.D., Rudolf Schicho, Ph.D., Gregor Gorkiewicz, M.D., Robert Krause, M.D., Nikolas Gerstgrasser, M.D., Guenter J. Krejs, M.D., and Thomas A. Hinterleitner, M.D.

K.oxytoca

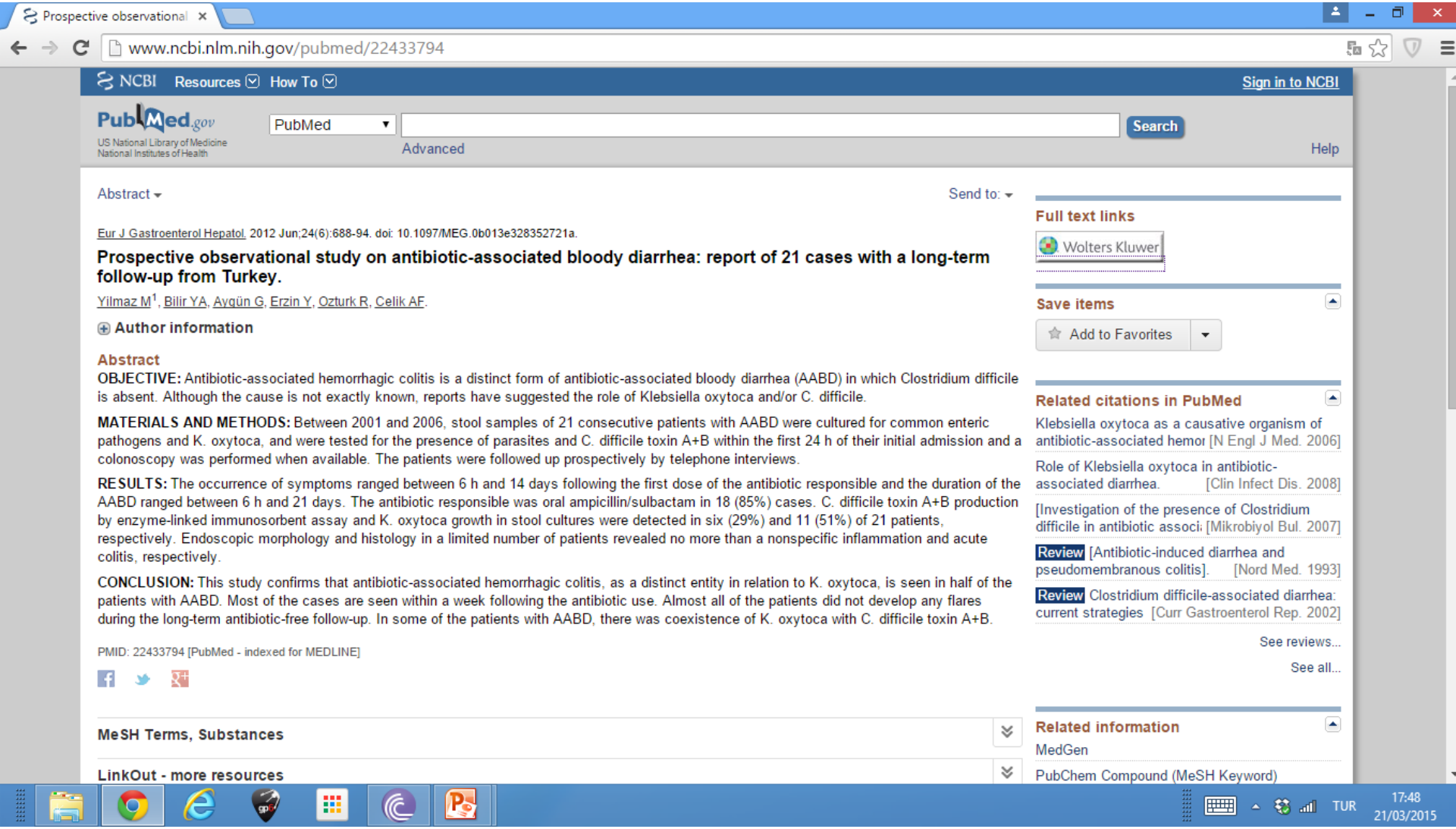
Prospective observational
www.ncbi.nlm.nih.gov/pubmed/22433794
NCBI Resources How To Sign in to NCBI
PubMed.gov
US National Library of Medicine
National Institutes of Health
PubMed
Search
Advanced
Help
Abstract
Send to:
Eur J Gastroenterol Hepatol. 2012 Jun;24(6):688-94. doi: 10.1097/MEG.0b013e328352721a.
Prospective observational study on antibiotic-associated bloody diarrhea: report of 21 cases with a long-term follow-up from Turkey.
Yilmaz M[1], Bilir YA, Aygün G, Erzin Y, Ozturk R, Celik AF.
Author information
Abstract
OBJECTIVE: Antibiotic-associated hemorrhagic colitis is a distinct form of antibiotic-associated bloody diarrhea (AABD) in which Clostridium difficile is absent. Although the cause is not exactly known, reports have suggested the role of Klebsiella oxytoca and/or C. difficile.
MATERIALS AND METHODS: Between 2001 and 2006, stool samples of 21 consecutive patients with AABD were cultured for common enteric pathogens and K. oxytoca, and were tested for the presence of parasites and C. difficile toxin A+B within the first 24 h of their initial admission and a colonoscopy was performed when available. The patients were followed up prospectively by telephone interviews.
RESULTS: The occurrence of symptoms ranged between 6 h and 14 days following the first dose of the antibiotic responsible and the duration of the AABD ranged between 6 h and 21 days. The antibiotic responsible was oral ampicillin/sulbactam in 18 (85%) cases. C. difficile toxin A+B production by enzyme-linked immunosorbent assay and K. oxytoca growth in stool cultures were detected in six (29%) and 11 (51%) of 21 patients, respectively. Endoscopic morphology and histology in a limited number of patients revealed no more than a nonspecific inflammation and acute colitis, respectively.
CONCLUSION: This study confirms that antibiotic-associated hemorrhagic colitis, as a distinct entity in relation to K. oxytoca, is seen in half of the patients with AABD. Most of the cases are seen within a week following the antibiotic use. Almost all of the patients did not develop any flares during the long-term antibiotic-free follow-up. In some of the patients with AABD, there was coexistence of K. oxytoca with C. difficile toxin A+B.
PMID: 22433794 [PubMed - indexed for MEDLINE]
Full text links
Wolters Kluwer
Save items
Add to Favorites
Related citations in PubMed
Klebsiella oxytoca as a causative organism of antibiotic-associated hemor [N Engl J Med. 2006]
Role of Klebsiella oxytoca in antibiotic-associated diarrhea. [Clin Infect Dis. 2008]
[Investigation of the presence of Clostridium difficile in antibiotic associ [Mikrobiyol Bul. 2007]
Review [Antibiotic-induced diarrhea and pseudomembranous colitis]. [Nord Med. 1993]
Review Clostridium difficile-associated diarrhea: current strategies [Curr Gastroenterol Rep. 2002]
See reviews...
See all...
Related information
MedGen
PubChem Compound (MeSH Keyword)
MeSH Terms, Substances
LinkOut - more resources
TUR
17:48
21/03/2015

E. histolytica *Blastocystis hominis*[h] *Dientamoeba fragilis* *Balantidium coli* *Giardia lamblia* Nematodes including: *Ascaris lumbricoides, Strongyloides stercoralis*[i]*, Trichuris trichiura,* Hookworms Cestodes (Tapeworms) Trematodes	Ova and parasite examination including permanent stained smear	Stool	Stool not in fixative <1 h RT, 5 or 10% buffered formalin and modified PVA, SAF, or commercially available one-vial system, 2–24 h
E. histolytica	*E. histolytica* species specific immunoassay	Stool	
Giardia lamblia[j]	Enzyme immunoassay	Stool	
Cryptosporidium spp[j]	Direct fluorescent immunoassay	Stool	
Coccidia including *Cryptosporidium*[j]*, Cyclospora, Isospora*	Modified acid fast stain[k] performed on concentrated specimen	Stool	
Microsporidia	Modified trichrome stain[k] performed on concentrated specimen	Stool	
	Histologic examination with EM confirmation	Small bowel biopsy	Formalin container, RT, 2–14 d
Enterobius vermicularis	Pinworm paddle or Scotch tape prep	Perianal area	RT, 2 h

Virus			
Calicivirus (Norovirus[l], Sapovirus) Enteric Adenovirus Enterovirus/ Parechovirus[m] Rotavirus	NAAT	Stool	Closed container, RT, 2 h
Rotavirus Enteric Adenovirus	Enzyme immunoassay[n]	Stool	Closed container, RT, 2 h
Enteric Adenovirus[o] Enterovirus/ Parechovirus[m]	Viral Culture	Stool	Viral transport medium, on ice, 2 h
Cytomegalovirus	Histopathological examination	Biopsy	Formalin container, RT, 2–14 d
	CMV Culture	Biopsy	Sterile container, RT, immediately
Calicivirus (Norovirus[l], Sapovirus)	Outbreak investigation performed by public health officials	Stool	Closed container, RT, 2 h

Table VII-4. Laboratory Diagnosis of Proctitis

Etiologic Agents	Diagnostic Procedures	Optimum Specimens	Transport Issues; Optimal Transport Time
Neisseria gonorrhoeae	Routine aerobic culture employing media for the recovery of *N. gonorrhoeae*	Rectal swab	Swab in Amies or Stuart's transport medium, RT, 8 h
Neisseria gonorrhoeae *Chlamydia trachomatis*	NAAT[a]	Rectal swab	Transport is manufacturer dependent
Chlamydia trachomatis	Direct immuno-fluorescent stain	Rectal swab	Transport is manufacturer dependent
Herpes simplex virus	Viral culture	Rectal swab	Viral transport medium, RT, 2 h, wet ice if >2 h
Treponema pallidium	RPR or VDRL with confirmatory *T. pallidum* specific test or syphilis IgG	Serum	Clot tube, RT, 2 h

- NAAT bu örnek için onaylı değil.

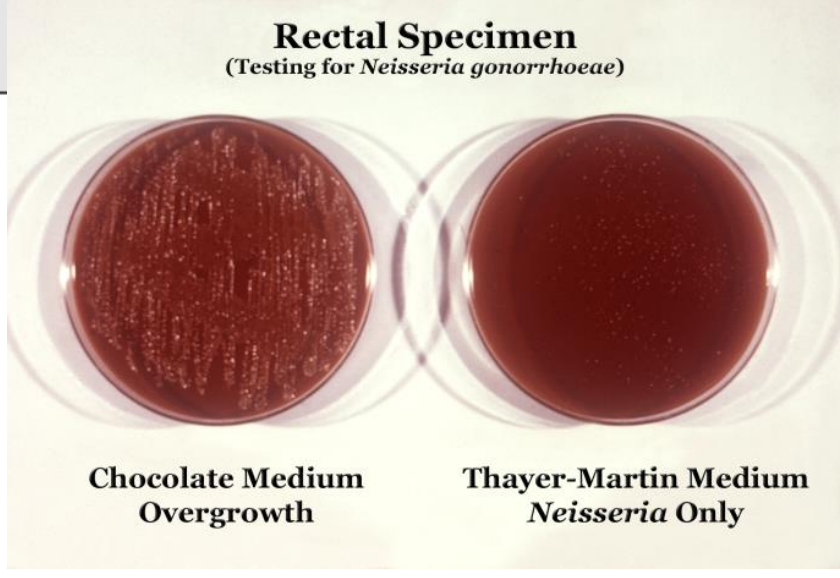

Karıniçi infeksiyonlar

- Eküvyon uygun değil!
- Tüm çalışmalar için yeterli örnek alınmalı
- Apselerde sadece apse örneği değil apse duvarı örneği de tercih edilir
- Tüberküloz tanısında NAAT onaylı değil.

  Fakat son derece duyarlı !
- TBC varlığında sistemik hastalık akla gelmeli

Table VIII-2. Specimen Management for Intra-abdominal Infections

Condition	Diagnostic Procedure	Optimum Specimen	Transport Issues; Optimal Transport Time
Spontaneous Bacterial Peritonitis/Ascites	Aerobic and anaerobic[a] culture	10–50 mL concentrated peritoneal fluid and	RT; if >1 h, 4°C
Secondary Peritonitis; Tertiary Peritonitis	Gram stain prior to culture	Sample in blood culture bottle[a]	
Peritoneal Dialysis-associated Peritonitis			
	Blood culture	2–3 sets blood culture bottles	RT, do not refrigerate
	AFB stain and culture *Mycobacterium* NAAT[b]	Peritoneal fluid, aspirate or tissue	RT <1 h or 4°C
	Fungal culture and KOH or calcofluor white microscopy	Peritoneal fluid, aspirate or tissue	RT <1 h or 4°C
	Microscopy for ova and parasites[c]	Stool, peritoneal fluid, bile, duodenal aspirate	Transport stool in parasite transport vial; others <1 h at RT

- Önce GRAM (polimikrobiyal görüntü varsa HK ekimi yerine ayrı besiyerlerine direkt ekim.
- Anaerop kültür sadece sekonder peritonitlerde önerilir!

Space-Occupying Lesions of the Liver	Aerobic and anaerobic culture Gram stain specimen prior to culture	Lesion aspirate	Anaerobic transport; RT, if >1 h, 4°C
	Blood culture	2–3 sets in blood culture bottles	RT, do not refrigerate
	Cultures for *N. gonorrhoeae* and *C. trachomatis*	Lesion aspirates	For *N. gonorrhoeae:* Amies charcoal transport, RT.
		C. trachomatis specimen may include swab of liver capsule or surrounding peritoneum	For *C. trachomatis:* Chlamydia transport medium at 4°C
	NAAT *for N. gonorrhoeae* and *C. trachomatis*	Urethra, pelvic specimen (approved swabs), or urine (sterile cup)	RT for <1 h or 4°C
	Fungal culture and KOH or calcofluor white microscopy	10–50 mL fluid	RT, if >1 h, 4°C
	Serology	Serum	Clot tube, RT, 2 h
	Antigen detection for *Entamoeba histolytica*	Liver aspirate	RT for <30 min, then 4°C. Freeze (−20°C) if shipping to reference laboratory
Infections of the Biliary Tree	Aerobic and anaerobic culture Gram stain before culture	Aspirate from lesion	Anaerobic transport device; RT, if >1 h, 4°C
	Blood culture	2–3 sets	RT; do not refrigerate
	AFB stain and culture	Fluid or tissue	≤1 h at RT or 4°C
	Ova and parasite exam	Stool, peritoneal fluid, bile or duodenal aspirate	Closed container, RT, <2 h O&P transport vial, RT, 2–24 h
	Viral culture or NAAT	Aspirate or biopsy for CMV	Viral transport <1 h at RT. If >1 h, freeze (−70°C)
	Serology for *Entamoeba histolytica*	Serum	RT for <30 min, then 4°C. Freeze (-20°C) if shipping to reference laboratory

- Kist hidatik seroloji, tetkik ?

  (dalak apsesinde önermiş)
- Önce GRAM !!!

Kemik-Eklem infeksiyonları

- Eküvyon örnekleri uygun değil
  (biopsi/aspirat uygun)
- Sistemik bulgularda HK gerekli
- Eklem sıvısı hastabaşı HK şişesine ekilebilir. Ayrıca diğer incelemeler için örnek gayırmalı)
- Protez eklemde çok sayıda örnek hatta biofilm için sonikasyon sonrası kültür önerilir.
- Bazı etkenler üretilez!

Osteomiyelit

- Tüm olgularda seçkin örnek : Kemik biopsisi
- Gram ve aerobik kültür
- Floranın katıldığı, komşulukla gelişen, diabetik ayak gibi durumlarda, travmatik olgularda

  (+ anerobik kültür)

Nocardia spp, other aerobic actinomycetes and soil filamentous fungi in patients with mycetoma[i]	Gram stain Aerobic bacterial culture	Bone biopsy or sinus tract specimen (curetting or tissue biopsy)	Sterile container, RT, immediately
	Silver stain Calcofluor-KOH stain Buffered charcoal yeast extract (BCYE) agar for *Nocardia* Fungus culture	Bone biopsy or sinus tract specimen	Sterile container, RT, 2 h

İnfeksiyon tanısında derin doku/eküvyon

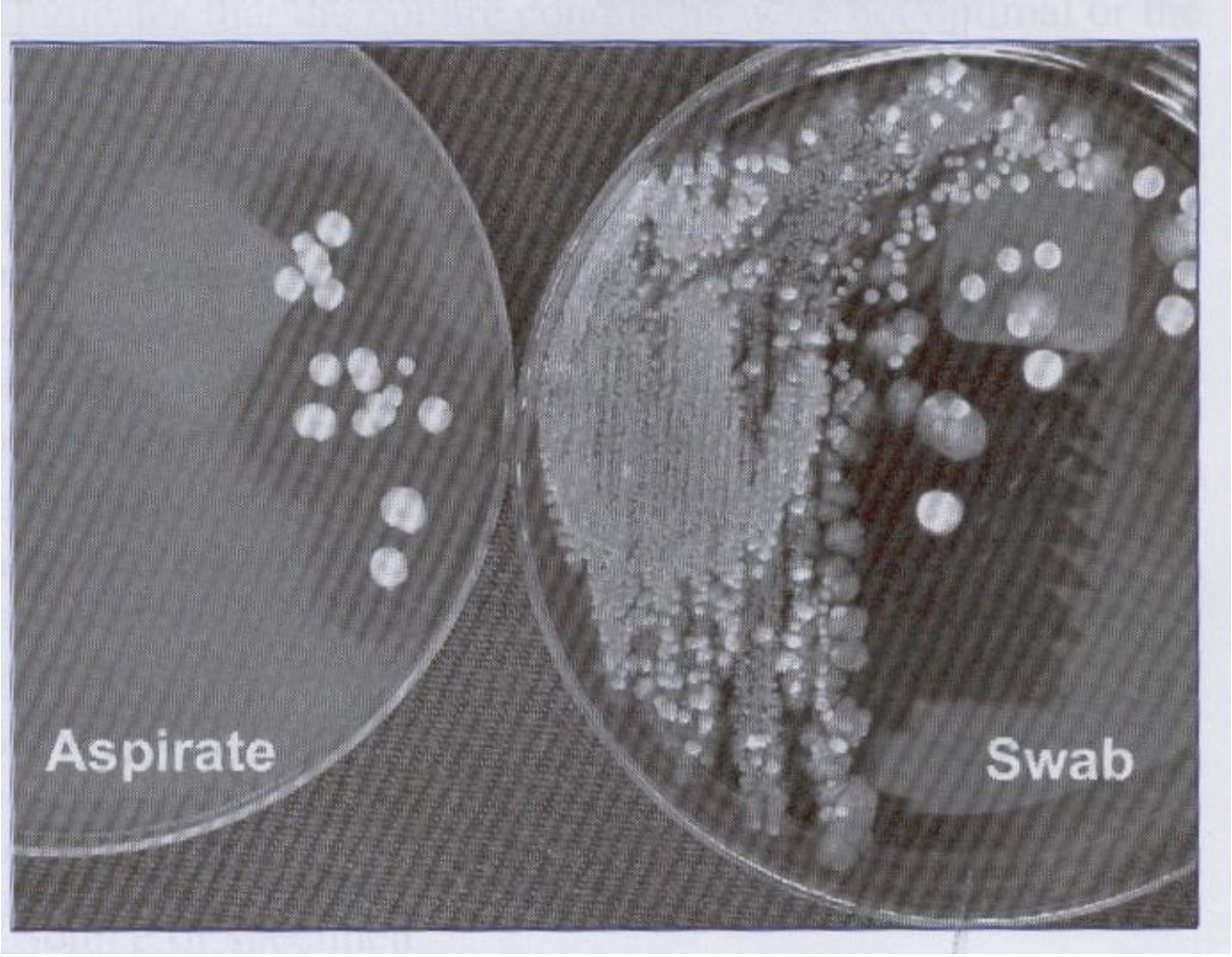

Septik artrit

Table IX-2. Laboratory Diagnosis of Joint Infections

Etiologic Agents	Diagnostic Procedures	Optimum Specimens	Transport Issues; Optimal Transport Time
Acute Arthritis			
Staphylococcus aureus	Gram stain	Synovial fluid and/or synovium biopsy	Sterile container, RT, immediately
Staphylococcus lugdunensis	Aerobic bacterial culture		
Streptococcus pyogenes	Inoculate up to 10 mL fluid directly into aerobic blood culture bottle at bedside[a]		Aerobic blood culture bottle
Streptococcus pneumoniae			
Non-Group A β-hemolytic streptococci			
Enterobacteriaceae			
Pseudomonas spp			
Kingella kingae[b]			
Neisseria gonorrhoeae[c]			
Brucella spp		Brucella serology	
Parvovirus-B19 [149]	PV-B19 serology	5 mL serum	Clot tube, RT, 2 h
	PV-B19 nucleic acid amplification test (NAAT)	Synovial fluid	Closed container, RT, 2 h
Rubella [150]	Rubella serology[d]	5 mL serum	Clot tube, RT, 2 h

Kronik artrit

Chronic Arthritis			
Borrelia burgdorferi (Lyme Disease) [151]	Lyme serology	5 mL serum	Clot tube, RT, 2 h
	B. burgdorferi culture[e]	Synovial fluid	Sterile container, RT, immediately
	B. burgdorferi NAAT	Synovial fluid	Closed container, RT, 2 h
Mycobacterium tuberculosis	Acid fast smear	Synovial fluid and/or synovium biopsy[f]	Sterile container, RT, 2 h
Non-tuberculous mycobacteria	AFB culture		
Candida spp	Calcofluor-KOH stain	Synovial fluid and/or synovium biopsy	Sterile container, RT, 2 h
Cryptococcus neoformans			
Blastomyces dermatitidis	Fungal culture		
Coccidioides immitis			
Aspergillus spp			

Protez eklem infeksiyonu

Prosthetic Joint Infections			
Staphylococcus aureus	Aerobic bacterial culture	Multiple tissue biopsy samples.	Sterile container, RT, 2 h
Coagulase negative staphylococci			
Enterococcus spp	Gram stain not useful	Synovial fluid	
Streptococcus spp (group A, B and other β hemolytic types)		Or submit the removed prosthesis in sterile container for sonication protocol.	
Enterobacteriaceae			
Pseudomonas aeruginosa			
Corynebacterium spp			
Propionibacterium acnes Other anaerobes	Aerobic and anaerobic bacterial culture (incubate anaerobic cultures up to 14 d)		Sterile anaerobic transport container, RT, immediately.
Polymicrobial infections	Also consider submitting prosthesis (if removed) for sonication		

Üriner sistem infeksiyonları

- Orta akım idrar, kateterle alınan idrar, suprapubik ya da sistoskopi idrarı (bildirilmeli)
- Üç ve daha fazla farklı mo: kontaminasyon
- Refleks idrar kültürü için eğitim...
- Kateterli hastalarda örnek toplama cihazı aracılığı ile örnek
- Koloni sayımı? Yorum ? (iletişim)
- Gram: ürosepsis olgularında faydalı

Table X-1. Laboratory Diagnosis of Cystitis and Pyelonephritis

Etiologic Agents	Diagnostic Procedures	Optimum Specimens	Transport Issues; Optimal Transport Time
Gram-Negative Bacteria			
Enterobacteriaca e: Includes *Escherichia coli, Klebsiella* spp, *Proteus* spp, *others* *Pseudomonas* spp, other nonfermenting gram-negative rods	Routine aerobic culture Gram stain (optional, low sensitivity)	Mid-stream, clean catch or straight cath urine	Closed sterile leakproof container; refrigerate (4°C) or use urine transport tube unless delivery to laboratory ≤1 h is certain.
Gram-Positive Bacteria			
Enterococcus spp *Staphylococcus aureus* *Staphylococcus saprophyticus* *Corynebacterium ureolyticum* *Streptococcus agalactiae* (Group B streptococci)	Routine aerobic culture Gram stain (optional, low sensitivity)	Midstream, clean catch, or straight cath urine	Closed sterile leakproof container; refrigerate (4°C) or use urine transport tube unless delivery to laboratory ≤1 h is certain.
Mycobacteria			
Mycobacterium tuberculosis	Mycobacterial culture	First void urine	Prefer >20 mL urine, refrigerate (4°C) during transport
Virus			
Adenovirus	Virus Culture NAAT[a]	Midstream or clean catch urine	Closed sterile container to laboratory within 1 h
BK Polyoma virus	Quantitative NAAT[a] from urine, plasma, or serum	Blood Serum	EDTA or Citrate blood collection tube, RT Clot tube, RT

Etiologic Agents	Diagnostic Procedures	Optimum Specimens	Transport Issues; Optimal Transport Time
Acute Bacterial Prostatitis			
E. coli, other enteric bacteria, *Pseudomonas* spp *Staphylococcus aureus* *Enterococcus* Group B streptococci	Aerobic Culture	Midstream urine with or without expressed prostate secretions	Closed sterile container to laboratory within 1 h or refrigerate (4°C) if delayed transport
Chronic Bacterial Prostatitis			
Pathogens similar to acute bacterial disease	Gram stain or cell counts Aerobic culture	Midstream urine and expressed prostate secretions, seminal fluid	Closed sterile container to laboratory within 1 h or refrigerate (4°C) if delayed transport
Fungus			
Blastomyces dermatitidis *Coccidioides immitis* *Histoplasma capsulatum*	Fungal culture	Expressed prostate secretions, prostate biopsy	Closed sterile container to laboratory within 1 h or refrigerate (4°C) if delayed transport
Mycobacteria			
Mycobacterium tuberculosis	Mycobacterial culture	First void urine, expressed prostate secretions, prostate biopsy	Prefer >20 mL urine, refrigerate (4°C) during transport

Genital infeksiyonlar

- Eşler birlikte değerlendirilmeli
- 35-37 haftalarda GBS taraması (rektal, vaginal örnek)
- HSV-2 ayırabilen bir serolojik test kullanılmalı
- Gebelerde HIV taraması faydalı
- BV için Gram boyama uygun
- Epididimit ve orşit (biopsi /aspirat) (sperm,idrar kültür için uygun değil)
- NAAT testleri (GC,CT için sürüntü/ilk akım idrar)

Table XI-1. Laboratory Diagnosis of Genital Lesions

Common Etiologic Agents	Diagnostic Procedures	Optimum Specimen	Transport Issues; Optimal Transport Time
Herpes simplex virus 1 and 2	Direct fluorescent antibody (DFA)	Scraping of lesion base rolled directly onto slide[a]	RT
Note: in children with genital lesions, consider atypical VZV[a]	Culture	Scraping of lesion base and placed in VTM/UTM[b]	RT, If >2 h, refrigerated or on ice
	NAAT[c]	Scraping or aspirate	Assay-specific; consult laboratory
	Serology[d]	Serum	Clot tube, RT
Human papilloma virus (HPV)	DNA hybridization probe or NAAT for high-risk HPV types[e]	Endocervical brush into liquid cytology medium or transport tube	RT, 48 h
16/18 genotyping			
Genital warts[f]	Histopathology; HR HPV testing not done on warts	Biopsy or scraping	Formalin container, RT, 2–24 h
Syphilis	Darkfield microscopy[g]	Cleanse lesion with gauze and sterile saline	RT, immediately to laboratory
	Test is not widely available and specimen must be transported to laboratory immediately to visualize motile spirochetes	Swab of lesion base directly to slide	
	DFA-*Treponema pallidum* (DFA-TP)[h,i]	Cleanse lesion with gauze and saline	Slide should be dry before placing in holder and/or transporting to lab
		Swab of lesion base directly to slide	
	Serology	Serum	Clot tube, RT, 2 h
	Non–Treponemal (VDRL or RPR)[j]		
	Treponemal Serology	Serum	Clot tube, RT, 2 h
	EIA or TP-PA, FTA-ABS[k,l]		

Common Etiologic Agents	Diagnostic Procedures	Optimum Specimen	Transport Issues; Optimal Transport Time
Chancroid (*Haemophilus ducreyi*)	Gram stain and Culture[m] NAAT[c]	Swab of lesion base without surface genital skin	RT immediately to laboratory
Lymphogranuloma venereum (LGV)	Cell culture[n]	Swab of ulcer base, bubo drainage, rectum	RT, immediately to laboratory
(*Chlamydia* serovars L1, L2, L2a, L2b, L3)	Serology Microimmunofluorescence (MIF)[o]	Serum	RT, 2 h
	Serology Complement fixation (CF)[p]	Serum	RT, 2 h
	NAAT[q]	Swab of ulcer base, bubo drainage, rectum	RT, 2 d; or refrigerate
Granuloma inguinale (donovanosis) *Klebsiella granulomatis*	Giemsa or Wright stain in pathology. Visualization of blue rods with prominent polar granules	Scraping of lesion base into formalin	RT, 2 h
Scabies/lice	Macro and microscopic visualization	Collect parasite from skin scrapings onto slide; place in a sterile Petri dish[r]	RT, within 1 h

Table XI-2. Laboratory Diagnosis of Bacterial Vaginosis, Yeast Vaginitis, and Trichomoniasis

Common Etiologic Agents	Diagnostic Procedures	Optimum Specimens	Transport Issues; Optimal Transport Time
Yeast (pH <4.5[a])	Saline wet mount and 10% KOH[b, c]	Swab of vaginal discharge	Submitted in 0.5 mL saline or transport swab[d], RT, 2 h
	Culture[e]	Swab of vaginal discharge	Submitted in transport swab, RT, 12 h
	DNA hybridization probe[f]	Swab of vaginal discharge[f]	RT, 7 d
Bacterial vaginosis (BV) (pH >4.5[a])	Wet mount and 10% KOH[g]	Swab of vaginal discharge	Submitted in 0.5 mL saline or transport swab, RT, 2 h
	Quantitative Gram stain[h]	Swab of vaginal discharge	Place directly into transport swab tube, RT, 12 h
	DNA Hybridization probe[f]	Swab of vaginal discharge[f]	RT, 7 d
Trichomoniasis (pH >4.5[a])	Saline wet mount[i]	Swab of vaginal discharge	Submitted in saline, RT, 30 min (optimal) – 2 h
	Rapid antigen test[j]	Swab of vaginal epithelium/ discharge	Submitted in transport swab or saline, RT, 24 h
	DNA hybridization probe[f]	Swab of vaginal discharge[f]	RT, 7 d
	Culture[k]	Swab of vaginal discharge	Place directly into InPouch TV Culture system, RT, 48 h
	NAAT[l]	Vaginal , endocervical swab, urine or liquid-based cytology specimen, urethral, rectal, pharyngeal swabs	RT, 7 d (or manufacturer's recommendation)

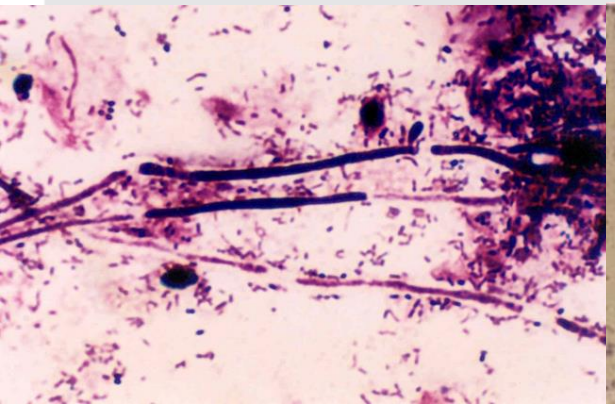

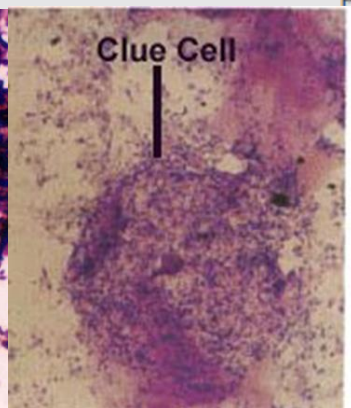

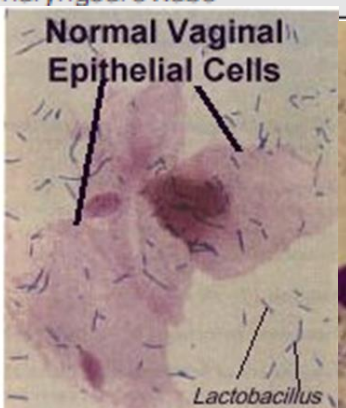

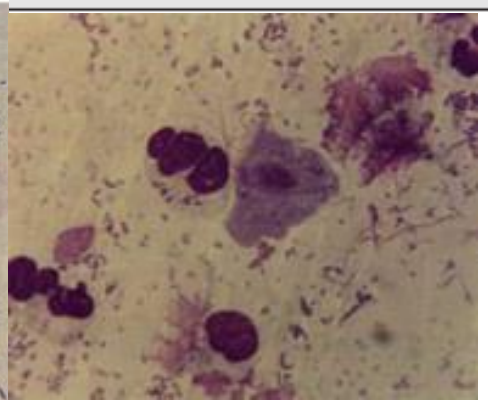

Table XI-3. Laboratory Diagnosis of Pathogens Associated with Cervicitis/Urethritis

Common Etiologic Agents	Diagnostic Procedures	Optimum Specimens	Transport Issues; Optimal Transport Time
Chlamydia trachomatis (CT)	NAAT[a]	Urine	Laboratory-provided transport device, RT, 2 d
		Endocervical, vaginal and/or urethral swab (rectum, pharynx, conjunctive, liquid-based cytology)[b,c]	
	Hybridization probe[d,e]	Endocervical or urethral swab[d]	Laboratory-provided transport device, RT, 2 d
	Culture[e,f]	Endocervical, urethral, conjunctival, nasopharyngeal (NP), pharynx, or rectal swab	Laboratory-provided transport device, Refrigerate (4°C); <2 h
	Direct fluorescent antibody (DFA) test[g]	Conjunctival swab	Transport medium, RT, 2 h
Neisseria gonorrhoeae	Gram stain[h]	Urethral discharge	Smear on slide directly or submit swab in transport medium, RT, immediately
	NAAT[a]	Urine	Laboratory-provided transport device, RT, 2 d
		Endocervical, vaginal and/or urethral swab (Rectal, pharynx, conjunctive, liquid based cytology specimen)[b,c]	
	Hybridization probe[d]	Endocervical or urethral swab	Laboratory-provided transport device, RT, 2 d
	Culture[i]	Endocervical, urethral, conjunctival, nasopharyngeal, pharynx, rectal swab	Transport medium, RT, ≤1 h Do not refrigerate specimen
Trichomonas vaginalis	Saline wet mount[j]	Endocervical or urethral swab	Submit in 0.5 mL saline, 30 min–2 h
	Rapid antigen test[k]	Endocervical swab	Laboratory-provided transport device, RT, 24 h
	DNA hybridization probe[l]	Endocervical or vaginal swab	Laboratory-provided transport device, RT, 7 d
	Culture[m]	Endocervical or urethral swab	Direct inoculation into InPouch TV culture system, 2–5 d[n]
	NAAT[c]	Vaginal, endocervical swab, urine and liquid-based cytology specimen, urethral, rectal, pharyngeal swabs	Laboratory-provided transport device, RT, 2 d

Deri Yumuşak doku infeksiyonları

- Sadece yara kültürü olarak bildirmek doğru değil! (köpek ısırığı, ayakta kronik ülser yarası,...)
- Seçkin örnek lezyonun kenarındaki bölgeden alınan biopsi ! (akıntı, yüzeyel sürüntü uygun değil)
- Sadece anlamlı üremelere antibiyogram !

Table XII-1. Laboratory Diagnosis of Burn Wound Infections

Etiologic Agents	Diagnostic Procedures	Optimum Specimens	Transport Issues; Optimal Transport Time
Bacterial			
Staphylococcus aureus	Aerobic, quantitative culture/AST	Blood culture	RT, <12 h, aerobic
Coagulase-negative staphylococci		Surface swab	RT, <2 h, transport medium
Enterococcus spp		Tissue (punch biopsy)	No formalin, keep moist
Pseudomonas aeruginosa			
Escherichia coli	Histopathology	Tissue (punch biopsy)	Submit in formalin RT, 2 h
Klebsiella pneumoniae			
Serratia marcescens	Anaerobic culture	Tissue biopsy or aspirate (swab may not represent the disease process)	Anaerobic transport tubes, pre-reduced media; RT, <2 h
Proteus spp			
Aeromonas hydrophila[a]			
Bacteroides spp and other anaerobes	NAAT for MRSA and *S. aureus* only	Swab from manufacturer[b]	Laboratory-provided transport device, RT, <2 h
Fungi			
Candida spp	Fungal culture	Tissue biopsy	RT, <30 min, no formalin, keep moist
Aspergillus spp			
Fusarium spp			
Alternaria spp	Fungal blood culture	Blood; 2–4 cultures per 24 h period	Lysis-centrifugation tube or broth-based blood culture bottles, RT, <2 h
Zygomycetes			
Viruses			
Herpes simplex virus	Tissue culture	Tissue (biopsy/aspirate)	Viral transport medium or laboratory-provided transport device
Cytomegalovirus	NAAT, where applicable and laboratory-validated		
Varicella-zoster virus			

Downloaded from http://sup.oxfor

- Aynı yerden haftada iki kez kantitatif sürüntü kültürü
- Biopsi kantitatif kültür !
- HK önemli!

Isırık yaraları

- Doku,aspirat, biopsi
- Aerop ve anerop kültür
- Gram boyama

- Hayvan ısırıkları…Mikobakteri araştırması!

Post travmatik yaralar

- Aspirat, biopsi uygun
- Ciddi olgularda HK
- S.aureus /MRSA için NAAT testi (+)
- Yarada S.pyogenes !!!
- Kronik/ iyileşmeyen cerrahi yaralarda

M.hominis, Legionella, Mycobacterium ?

Table XII-6. Laboratory Diagnosis of Fungal Infections of Skin and Subcutaneous Tissue

Etiologic Agents	Diagnostic Procedures	Optimum Specimens	Transport Issues; Optimal Transport Times
Dermatophytes/Tineas			
Epidermophyton spp *Trichophyton* spp	Fungal culture Calcofluor-KOH preparation	Skin scrapings/hair follicles/ nail scrapings	Sterile transport container Aerobic conditions, RT, <4 h
Microsporum spp	Histopathology	Tissue/biopsy	Formalin container, RT, 2 h–24 h
Dematiaceous (darkly pigmented) Filamentous Fungi			
Scedosporium/ *Pseudallescheria* spp *Exophiala* spp	Fungal culture Calcofluor-KOH preparation	Tissue/biopsy/aspirate	Sterile transport container Aerobic conditions, RT, <2 h
Cladosporium spp *Phialophora* spp *Alternaria* spp *Bipolaris* spp	Histopathology	Tissue/biopsy/aspirate	Formalin container, RT, 2 h–24 h

Mikrobiyoloji Laboratuvarları dikkat!

Med Mycol Case Rep. 2014 Jan; 3: 20–25.
Published online 2014 Jan 20. doi: 10.1016/j.mmcr.2014.01.002
PMCID: PMC3930961

First imported coccidioidomycosis in Turkey: A potential health risk for laboratory workers outside endemic areas☆

A. Serda Kantarcioglu,[a,*] M. Sandoval-Denis,[b] Gökhan Aygun,[a] Nuri Kiraz,[a] Canan Akman,[c] Hulya Apaydin,[d] Emin Karaman,[a] Josep Guarro,[b] G. Sybren de Hoog,[f] and M.S. Gurel[g]

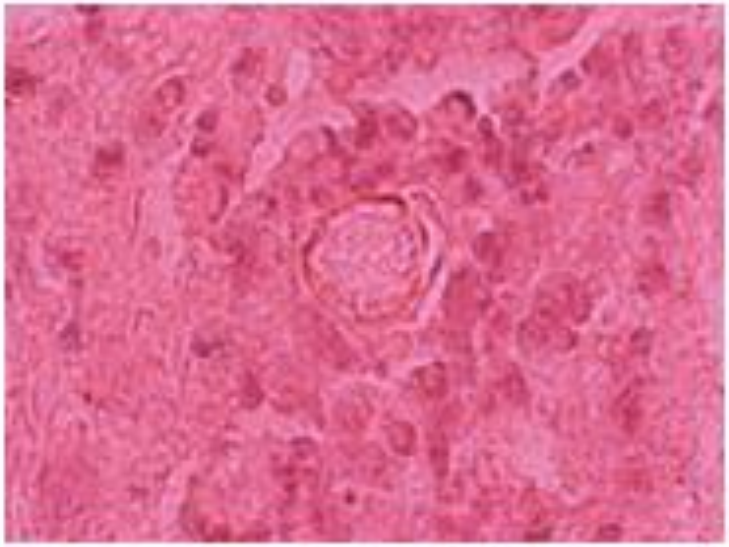

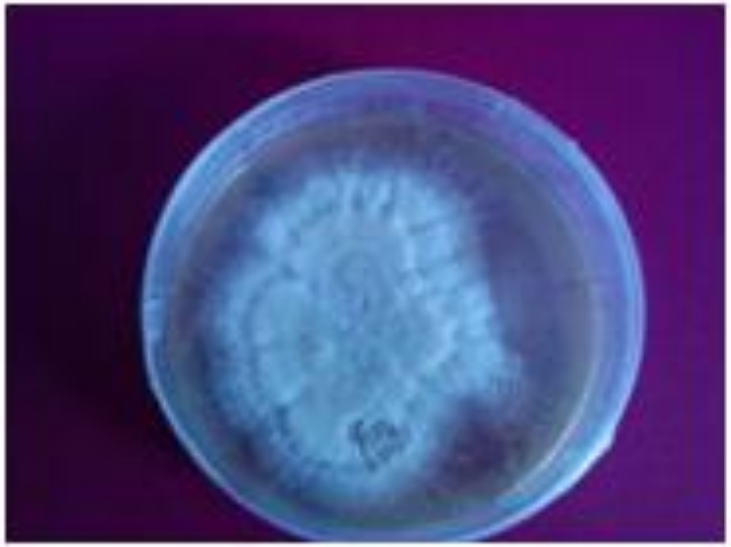

Table XIII-1. Laboratory Diagnosis of Tickborne Infections

Etiologic Agents*	Diagnostic Procedures	Optimum Specimens	Transport Issues; Optimal Transport Times
Bacteria			
Relapsing fever borreliae (4–6) *Borrelia hermsii* (western USA) *Borrelia parkeri* (western USA)	Primary test[b]: Darkfield microscopy or Wright's, Giemsa or Diff-Quik stains of peripheral thin or/and thick blood smears. Can be seen in direct wet preparation of blood in some cases.	Blood, bone marrow	EDTA or citrate blood tube, RT, ≤30 min
Borrelia turicae (southwestern USA)	Others Tests		
Borrelia mazzottii (southern USA)	NAAT	Serum, blood, body fluids	Clot tube for serum; sterile tube or citrate tube for body fluids, RT, within 2–4 h
	Culture[c]		
	Serologic testing[d]	Blood, body fluids	
		Serum	
Borrelia burgdorferi sensu latocomplex (Lyme borreliosis)[e]	Early Lyme disease – presence of erythema migrans:	Serum	Clot tube, RT, ≤2 h
Borrelia burgdorferi (USA)	Serologic testing insensitive in the first 2 wk of infection[f]		
Borrelia garinii (Europe, Asia) *Borrelia afzelii* (Europe, Asia)	Early/disseminated (weeks through months after tick bite) or late/persistent (months through years after tick bite in untreated patients, almost exclusively seen with *B. afzelii*[g]):		
	Primary test: Two-tier testing (acute- and convalescent-phase sera optimal) = EIA IgG and IgM antibody screening. If EIA result is positive or equivocal, confirm with IgG and IgM Western blot (WB).[h]		
	NOTE: A Western blot should NOT be performed unless an initial EIA is reported as positive or equivocal.	Serum and CSF	Clot tube for serum, sterile tube for CSF, RT, ≤1 h
	Neuroborreliosis[g]		
	Paired serum/CSF antibody levels, ie, CSF/serum antibody index.		
	NAAT[i]	Blood, biopsy specimens of infected skin, synovial fluid or tissue, CSF, etc.	Transport on ice; ≤1 h If DNA not extracted shortly after collection, store frozen at −70°C.

Etiologic Agents[a]	Diagnostic Procedures	Optimum Specimens	Transport Issues; Optimal Transport Times
Anaplasma phagocytophilum (human granulocytotropic anaplasmosis)[j]	Primary Test: Wright or Giemsa stain of peripheral blood or buffy coat leukocytes during week first week of infection.	Blood	EDTA or citrate tube, RT, ≤1 h
	Acute and convalescent IFA titers for *Anaplasma* antibodies; specificity ranges from 83% to 100% with cross-reactivity among *E. chaffeensis* and *A. phagocytophilium* antibodies, as well as a number of clinical conditions such as Rocky Mountain Spotted Fever, typhus, Q fever, Lyme disease, etc[k]	Serum	Clot tube, RT, ≤2 h
	NAAT	Blood	EDTA anticoagulant tube Transport on ice; ≤1 h
	Immunohistochemical staining of *Anaplasma* antigens in formalin-fixed, paraffin-embedded specimens	Bone marrow biopsies or autopsy tissues (spleen, lymph nodes, liver and lung)	Formalin container, RT, ≤2 h
Ehrlichia chaffeensis (human monocytotropic ehrlichiosis)	Primary Test: Wright or Giemsa stain of peripheral blood or buffy coat leukocytes smear during first week of infection.	Blood	EDTA anticoagulant tube, RT, ≤1 h
Ehrlichia ewingii[j,k]	Serology: acute and convalescent IFA titers for *Ehrlichia* antibodies[l]	Serum	Clot tube, RT, ≤2 h
	NAAT (only definitive diagnostic test for *E. ewingii*)	Whole blood	Heparin or EDTA anticoagulant tube Transport on ice; ≤1 h If DNA not extracted shortly after collection, store frozen.
	Immunohistochemical staining of *Ehrlichia* antigens in formalin-fixed, paraffin-embedded specimens	Bone marrow biopsies or autopsy tissues (spleen, lymph nodes, liver and lung)	Formalin container, RT, ≤2 h

Rickettsia rickettsii (Rocky Mountain spotted fever)[m,n]	Serology: acute and convalescent IFA for *R. rickettsii* IgM and IgG antibodies[l]	Serum	Clot tube, RT, ≤2 h
	NAAT	Skin biopsy (preferably a maculopapule containing petechiae or the margin of an eschar) or autopsy tissues (liver, spleen, lung, heart, and brain)	Sterile container Transport on ice; ≤1 h If DNA not extracted shortly after collection, store frozen.
	Immunohistochemical staining of spotted fever group rickettsiae antigens (up to first 24 h after antibiotic therapy initiated) in formalin-fixed, paraffin-embedded specimens	Skin biopsy (preferably a maculopapule containing petechiae or the margin of an eschar) or autopsy tissues (liver, spleen, lung, heart and brain)	Formalin container, RT, ≤2 h
Protozoa			
Babesia microti	Primary Test: Giemsa, Wright's, Wright-Giemsa stains of peripheral thin and thick blood smears (Giemsa preferred)	Whole blood	For whole blood, prepare smears immediately
		Second choice EDTA vacutainer tube	RT, ≤30 min
	NAAT	Blood	EDTA anticoagulant tube, RT, ≤1 h
	Serology: acute and convalescent IFA titers for *Babesia* antibodies (IgM and IgG)	Serum	Clot tube, RT, ≤2 h

Viral sendromlar

- Örneklerin bir kısmı sonraki incelemeler için saklanmalı
- Bazı viruslarda çapraz reaksiyonlar olabilir!

Seroloji

NAAT

Hücre Kültürü

Viral sendromlar

- HIV
- EBV
- CMV(antijenemi)
- HSV, VZV (DFA)
- B-19 (dev pronormoblastlar)
- MMR
- BK (sitoloji), JC
- Solunum sistemi virusları (multipleks PCR)

Kan ve Doku parazitleri

Filariasis due to species of *Wuchereria, Brugia,* and *Mansonella*	Microscopy of Giemsa stained thick and thin blood films. Examination of concentrated blood specimens (Knott's, Nuclepore filtered blood or buffy coat) increases sensitivity. Antibody and/or antigen detection EIA (*Wuchereria bancrofti* and *Brugia malayi*) in blood by the CDC or reference lab	**Blood films for *W. bancrofti* and *B. malayi* should be collected at night when microfilariae are circulating. Repeat exams may be necessary due to low parasitemia.** Serology does not differentiate between filaria.
Filariasis, onchocerciasis due to *Onchocerca volvulus*	Microscopy of "skin snip" after incubation in saline at 37°C [243]	**"Skin snips" should be from areas near nodules and should be "razor thin" with no visible blood.** Histopathologic examination of skin biopsy or resected nodule (onchocercoma) can identify microfilariae and/or adults. Serology available from reference laboratories; does not differentiate between filariae.

Kan ve Doku parazitleri

Leishmaniasis, cutaneous due to various *Leishmania* species	Microscopic exam of Giemsa stained smears of biopsy touch impressions or aspirate from leading edge of ulcer; culture may be available using special media (NNN and others)	Histopathology of leading edge ulcer biopsies is less sensitive than impression smears.
	PCR and isoenzyme analysis are available at the CDC for speciation, which may be important for treatment considerations [244]	**Serology is not useful for cutaneous disease.**
Leishmaniasis, visceral, due to various *Leishmania* species	Microscopic exam of Giemsa stained bone marrow aspirate/biopsy, splenic aspirate; culture may be available using special media (NNN and others). Contact laboratory for availability of special media.	Positive rK39 serology reported to be both sensitive and specific for the diagnosis of visceral leishmaniasis in various endemic areas of the world.
	Serology from the CDC or reference laboratory [244]	
Malaria due to *Plasmodium falciparum, P. ovale, P. vivax, P. malariae, P. knowlesi*	Microscopy of Giemsa stained thick and thin blood films (**3 sets obtained during febrile episodes**); antigen (HR-2, aldolase, pLDH) detection tests (BinaxNow is FDA approved in US)	**Antigen strip tests lack sensitivity in low parasitemia and non-*falciparum* malaria and do not differentiate all species.**
	NAAT from some reference laboratories will detect and differentiate all species.	
Toxocariasis (visceral larva migrans)	Serology from CDC or referral laboratories	Larvae may be seen in histopathologic sections of biopsies of liver or other infected tissues.
	Histopathology	

Sonuç

- Mikrobiyoloji laboratuvarı giderek teknolojik ve karmaşık hale geliyor.
- İletişim azalıyor
- Teknolojik gelişmeler yeni sorunlar ve yeni yorumlar gerektiriyor.

- ARTAN İLETİŞİM ÇOK ÖNEMLİ !!!!
- Rehber güzel bir başlangıç fakat...

  BEĞENMEDİM !

- Tüm herşeye hakim (!) KMEHU bu işleri görsün!

- KMEHU ile MİKROBİYOLOJİ Laboratuvarı birlikte çalışsın

Teşekkür ederim

Bona diagnosis, bona curatio

İyi teşhis, iyi ilaç.