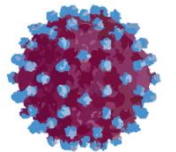


KRONİK HEPATİT C “OLGU SUNUMLARI”

Dr. Ziya Kuruüzüm
DEÜTF Enfeksiyon Hastalıkları ve
Klinik Mikrobiyoloji AD

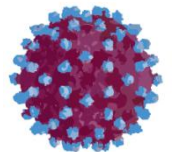
Hepatit Akademisi, Hilton, Mersin, 26.01.2014



Olgu - 1

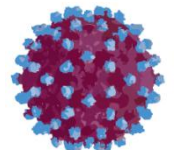
- SK, 1949, kadın, ev hanımı
- Sırt ağrısı nedeniyle yapılan tetkikler sırasında AST/ALT yüksekliği ve anti-HCV pozitif bulunuyor (2007)
- İzlem ve tedavi amacıyla başvuru (2007)
- Herhangi başka bir yakınması yok

- Özgeçmiş; Özellik yok
- Soygeçmiş; Özellik yok
- Fizik muayenesi; Normal

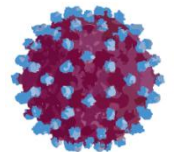


Laboratuvar

- Hemogram: normal
- AST: 59 U/L
- ALT: 79 U/L
- Anti-HCV (+)
- Ko-enfeksiyonu yok
- HCV RNA 374,000 IU/ml
- Genotip 1b

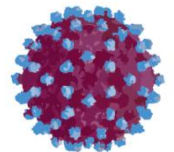


Ne yapalım?



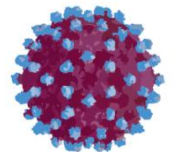
Seenekler

- 1. Tedavisiz izlerim
- 2. Karacięer biyopsisi yaparım
- 3. IL-28b bakarım
- 4. Tedavi bařlarım



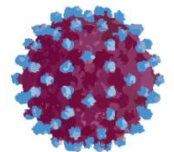
Karaciğer Biyopsisi

- Karaciğer biyopsisi (ISHAK);
 - ◆ HAI: 10/18
 - ◆ Fibrozis: 3/6



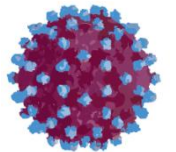
Tedavi Seçenekleri - 2013

- PEG-IF/RBV
- PEG-IF/RBV/TVR

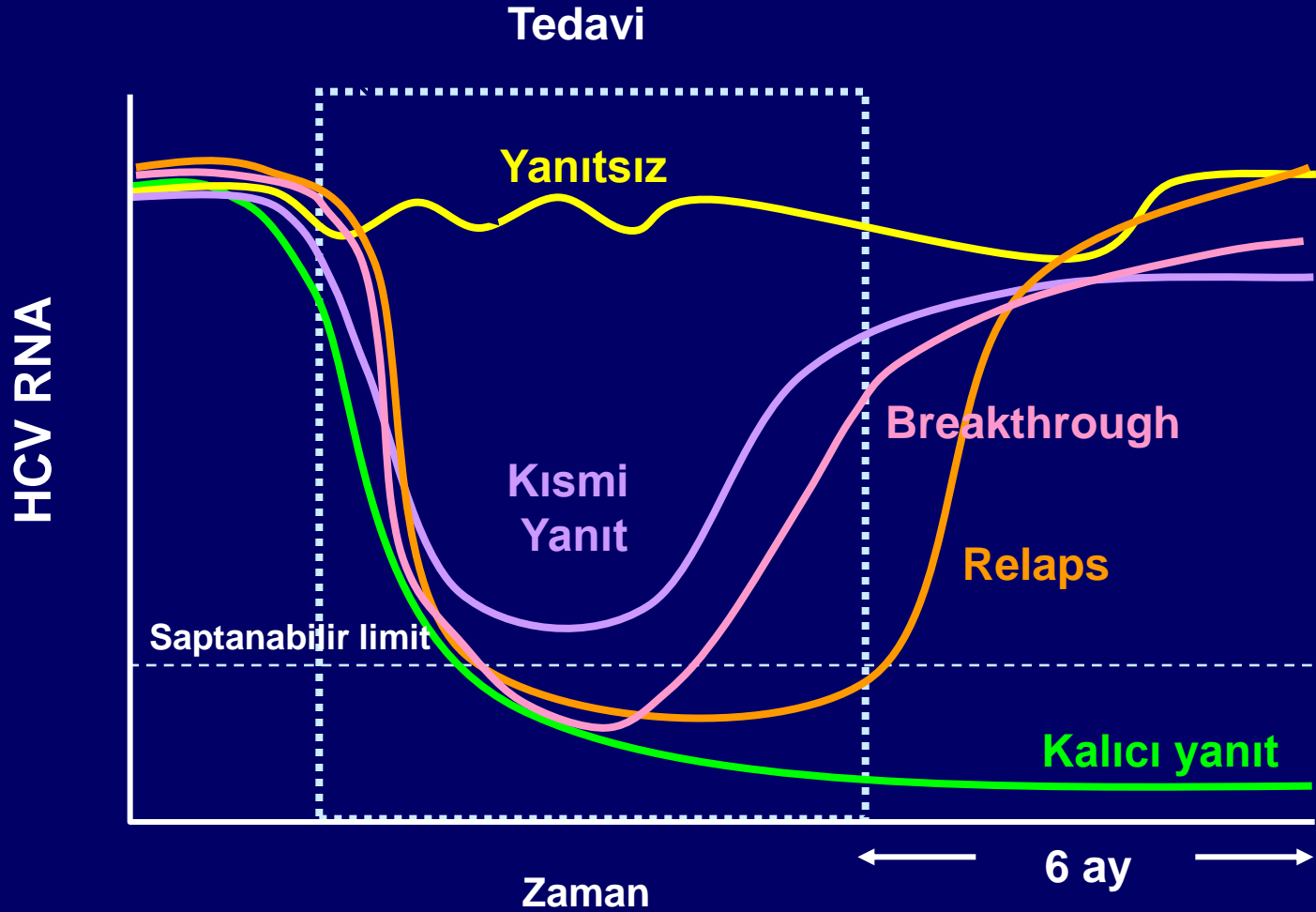


Tedavi

- PEG-IF-alfa 2b 120 μ gr/hf + RBV 1000 mg/gün (75 kg) başlanıyor (17.12.2007)

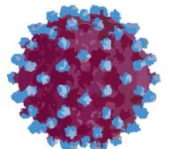


Virolojik Yanıt Paternleri



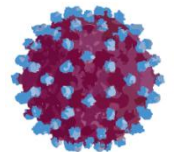
Tedaviye Yanıtın Göstergeleri

Parametre	4. hafta	12. hafta
RVR	HCV RNA <50 IU/ml	HCV RNA <50 IU/ml
EVR	RVR yok	HCV RNA <50 IU/ml ya da ≥ 2 log düşüş, ancak halen saptanabiliyor
cEVR	RVR yok	RVR yok, HCV RNA <50 IU/ml
pEVR	RVR yok	RVR yok, HCV RNA ≥ 2 log düşüş, ancak halen saptanabiliyor



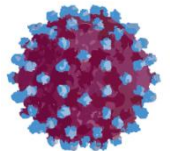
izlem

- Birinci ay;
- HCV RNA: 196 IU/ml
- AST 33 U/L, ALT 39 U/L
- Hemogram: N
- Sistem muayeneleri olađan

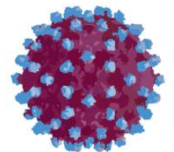


İzlem

- Üçüncü ay;
- HCV RNA: (-)
- AST 42 U/L, ALT 41 U/L
- Hemogram: Hb 12 gr/dl, Htc %35
- Sistem muayeneleri olađan

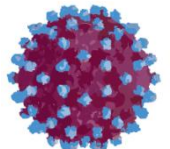


Kalıcı viral yanıt (KVY) olasılığı?

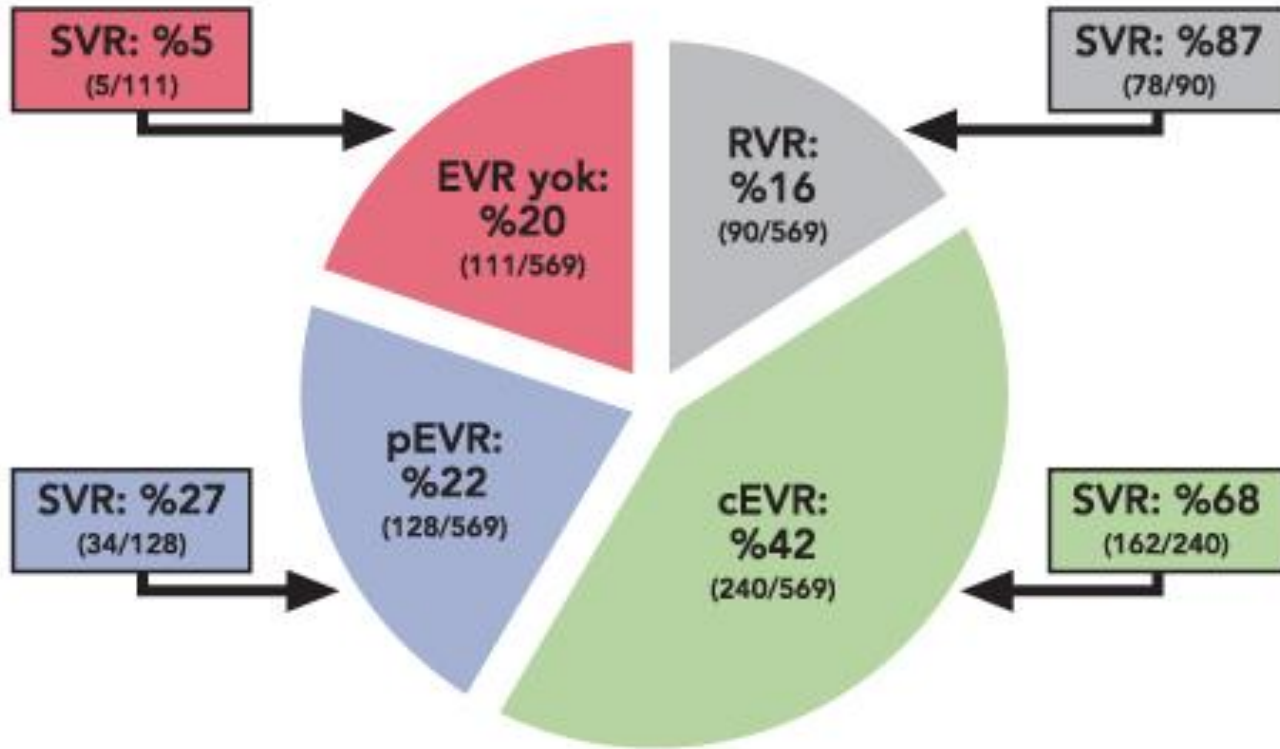


Tedaviye Yanıtın Göstergeleri

Parametre	4. hafta	12. hafta
RVR	HCV RNA <50 IU/ml	HCV RNA <50 IU/ml
EVR	RVR yok	HCV RNA <50 IU/ml ya da ≥ 2 log düşüş, ancak halen saptanabiliyor
cEVR	RVR yok	RVR yok, HCV RNA <50 IU/ml
pEVR	RVR yok	RVR yok, HCV RNA ≥ 2 log düşüş, ancak halen saptanabiliyor

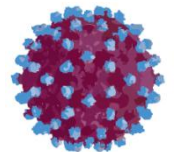


Kalıcı viral yanıt olasılıkları



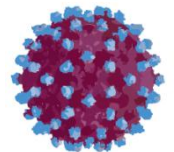
HCV RNA yanıtı:

- 4. haftada <50 IU/ml
- 4. haftada >50 IU/ml, ancak 12. haftada 2 log azalma (pEVR)
- 4. haftada >50 IU/ml, 12. haftada <50 IU/ml (cEVR)
- 12. haftada >50 IU/ml, < 2 log azalma (EVR yok)



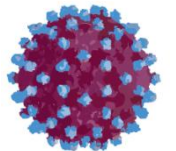
Kalıcı viral yanıt olasılıkları - *IL28b*

- *IL-28b* genotipi;
 - ◆ C/C: %69
 - ◆ C/T: %33
 - ◆ T/T: %27



Tedavi

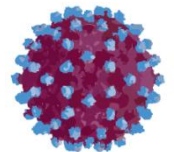
- Tedavi sorunsuz olarak devam ediyor
- 24. haftada hasta 68 kg; PEG-IF dozu 100 μ gr/hf
- 43. haftada hasta 63 kg ve Hb 8,9 gr/dl; RBV 800 mg/gün
- 48. haftada kesiliyor



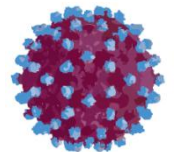
izlem

- 24. haftada HCV RNA: 193,000 IU/ml

“NÜKS”

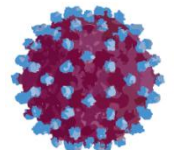


Ne yapalım?



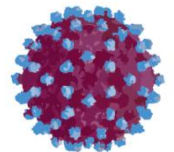
Seenekler

- 1. Tedavisiz izlerim
- 2. Yeniden PEG-IF/RBV
- 3. PEG-IF/RBV/TVR
- 4. Yeni tedavi seenekleri iin beklerim



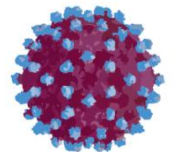
Seçim

- “Yeniden PEG-IF/RBV”
- PEG-IF alfa 2a 180 µgr/hf + RBV 1000 mg/gün (75 kg) başlanıyor



izlem

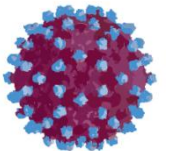
- Birinci ay;
- HCV RNA: (-)
- AST 33 U/L, ALT 29 U/L
- Hemogram: N
- Sistem muayeneleri olađan



Tedavi

- Tedavi sorunsuz olarak devam ediliyor ve 48. haftada kesiliyor
- Tedavi sonrası 24. hafta HCV RNA: (-)

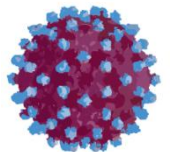
“KVY”



Olgu - 2

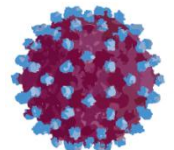
- İK, 1974, erkek, şöför
- Kan bağıışı öncesi yapılan tetkikler sırasında anti-HCV pozitif bulunuyor (2008)
- İzlem ve tedavi amacıyla başvuru (2008)
- Herhangi bir yakınması yok

- Özgeçmiş; Özellik yok
- Soygeçmiş; Özellik yok
- Fizik muayenesi; Normal, 92.5 kg



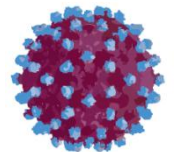
Laboratuvar

- Hemogram normal
- AST: 44 U/L
- ALT: 80 U/L
- Anti-HCV (+)
- Ko-enfeksiyonu yok
- HCV RNA 454,810 IU/ml
- Genotip 1



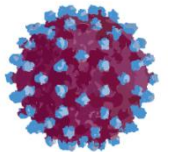
Karaciğer Biyopsisi

- Karaciğer biyopsisi;
 - ◆ Piece-meal nekroz: 2
 - ◆ Konfluen nekroz: 0
 - ◆ Spotty nekroz: 2
 - ◆ Portal enflamasyon: 2
 - ◆ HAI: 6/18,
 - ◆ Fibrozis: 3



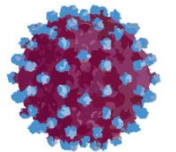
Tedavi

- PEG-IF-alfa 2b 150 μ gr/hf + RBV 1000 mg/gün (92,5 kg) başlanıyor (18.02.2009)



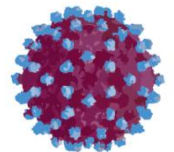
izlem

- Birinci ay;
- HCV RNA: 155,250 IU/ml
- AST 35 U/L, ALT 53 U/L
- Hemogram: N
- Sistem muayeneleri olađan

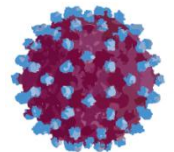


izlem

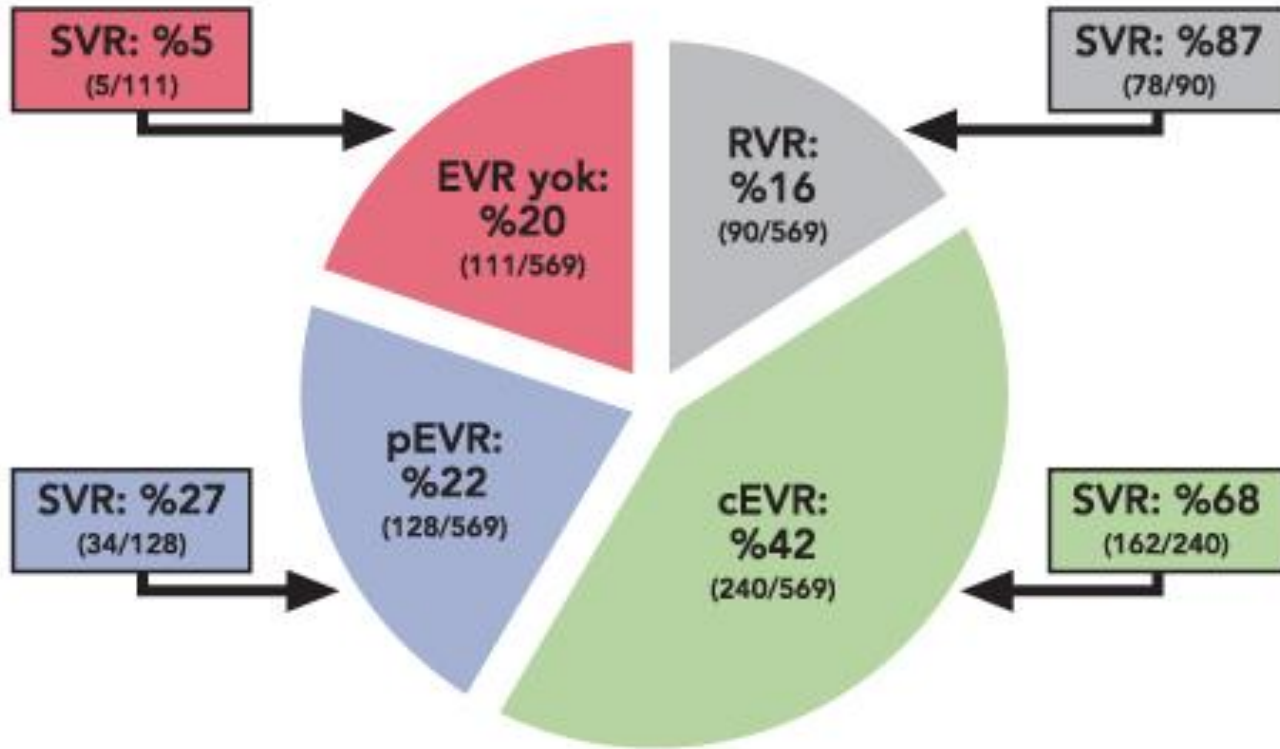
- Üçüncü ay;
- HCV RNA: 27,730 IU/ml
- AST 26 U/L, ALT 30 U/L
- Hemogram: Hb 14.4 gr/dl, Htc %43.2
- Sistem muayeneleri olađan



Ne yapalım?

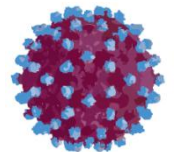


Kalıcı viral yanıt olasılıkları



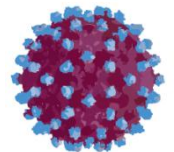
HCV RNA yanıtı:

- 4. haftada <50 IU/ml
- 4. haftada >50 IU/ml, ancak 12. haftada 2 log azalma (pEVR)
- 4. haftada >50 IU/ml, 12. haftada <50 IU/ml (cEVR)
- 12. haftada >50 IU/ml, < 2 log azalma (EVR yok)



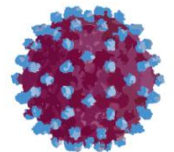
Tedavi

- Tedaviye devam ediliyor
- 24. haftada HCV RNA 21,825 IU/ml
- Tedavi kesiliyor



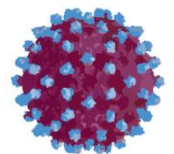
izlem

- Hasta kontrollere geliyor
- Yeniden tedavi ?
- Ribavirin dozu ?



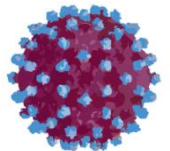
Laboratuvar

- Hemogram normal
- AST: 45 U/L
- ALT: 70 U/L
- Anti-HCV (+)
- HCV RNA 1,088,580 IU/ml
- Genotip 1



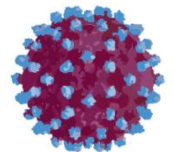
Tedavi

- PEG-IF-alfa 2a 180 μ gr/hf + RBV 1400 mg/gün (99 kg) başlanıyor (05.05.2010)



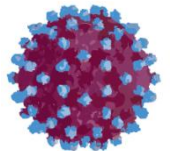
izlem

- Birinci ay;
- HCV RNA: 173,013 IU/ml
- AST 33 U/L, ALT 39 U/L
- Hemogram: N
- Sistem muayeneleri olađan

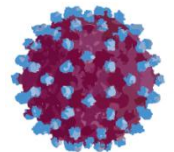


izlem

- Üçüncü ay;
- HCV RNA: (-)
- AST 24 U/L, ALT 26 U/L
- Hemogram: Hb 14.4 gr/dl, Htc %41.2
- Sistem muayeneleri olađan

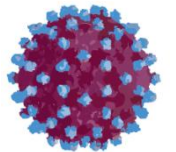


Ne yapalım?



Tedavi

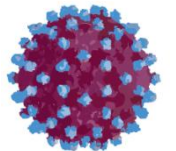
- Tedavi sorunsuz olarak devam ediyor
- 48. haftada kesiliyor



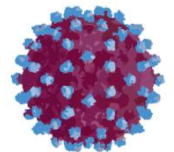
izlem

- 24. haftada HCV RNA: 1,986,387 IU/ml

“NÜKS”

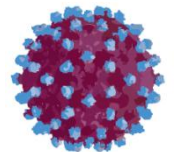


Ne yapalım?

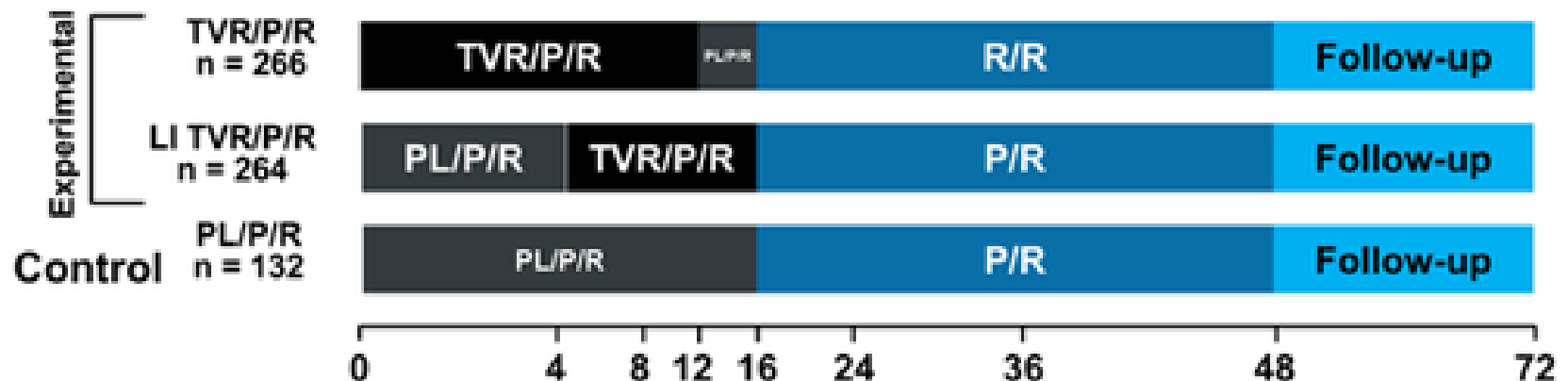


Tedavi Seçenekleri - 2013

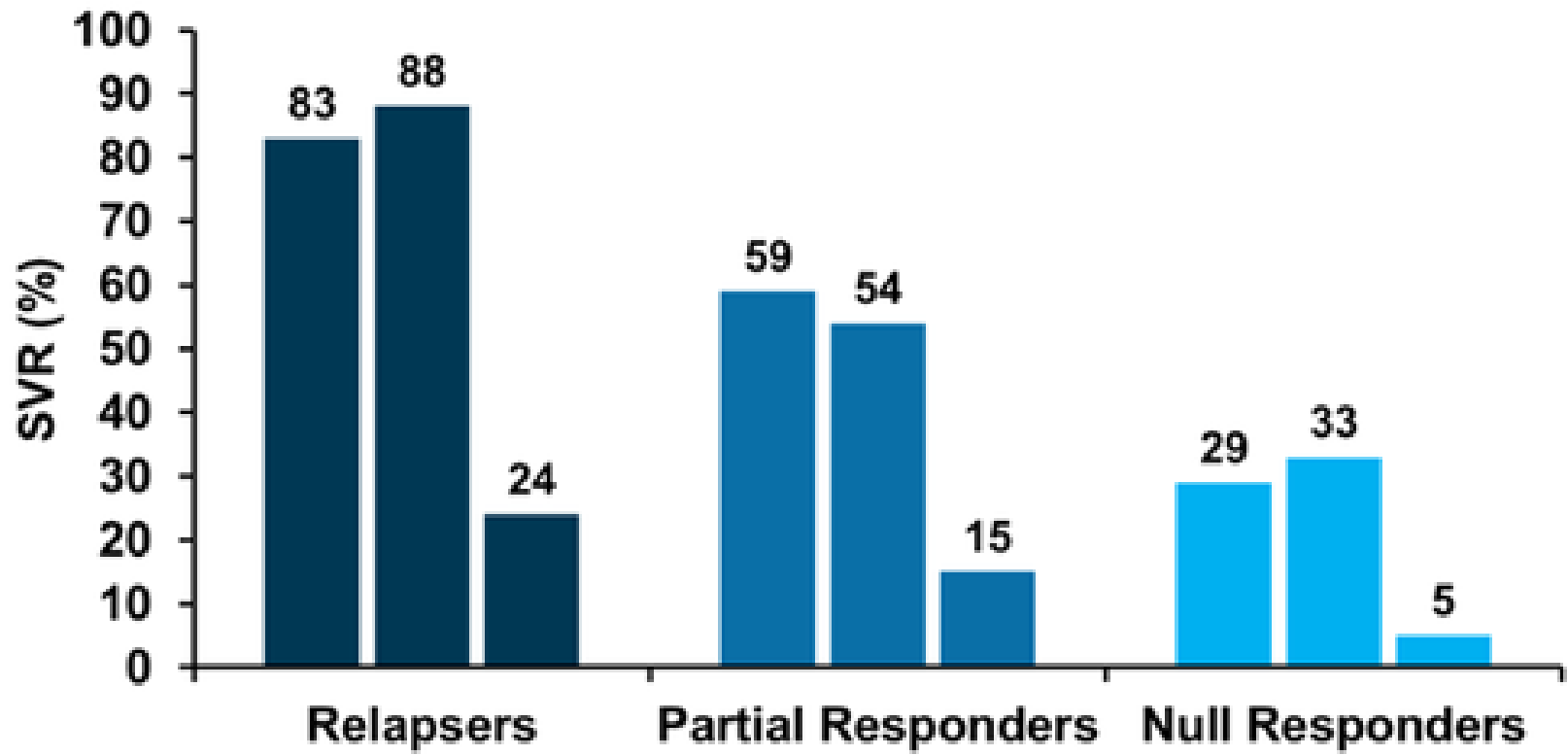
- PEG-IF/RBV
- PEG-IF/RBV/TVR



REALIZE: TVR in IFN-experienced Patients With Genotype 1 Chronic HCV Infection



Results in Previously-treated Patients: TVR



Hofmann WP, et al. *Nat Rev Gastroenterol Hepatol.* 2011;8:257-264.

A serene landscape at sunset or sunrise. The sky is a deep blue, with a bright crescent moon in the upper half. The sun is a glowing orb on the horizon, its light reflecting on the water below. The water is calm, and the reflection of the sun is clear. In the background, there are low, dark mountains or hills. The overall mood is peaceful and contemplative.

Sabrınız için teşekkürler